

**Arterial Lower Limb Duplex**Examined **12/12/2018 15:40**

Page 1 of 2

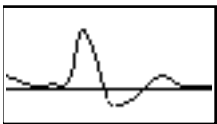
Helen Kerss

Reference

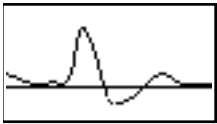
Accession **CR-18-0065065**

Patient **Barbara Sumner**
D.O.B. **10/12/1935**

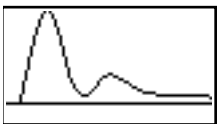
NHS No **438 943 4144**
Patient Ref **3196690**

Reason **Compression Bandaging**Outcome **Widely patent****Right****Left****Brachial**

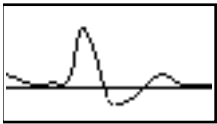
Good

Common Femoral**High Thigh****Low Thigh**

Good

Popliteal**High Calf****Peroneal**

Good

Anterior Tibial

Good

Posterior Tibial**Dorsalis Pedis****Toe Pressure****Post Exercise****Notes**

RIGHT LOWER LIMB ARTERIAL DUPLEX:

*Patient scanned on the ward using the portable CX50 scanner.

CFA, PFA origin, SFA and PopA - widely patent, triphasic waveforms, PSV 58-104cm/s.

TPT is patent. 3 run-off origins noted.

ATA and PTA - patent at the ankle, bouncy monophasic/triphasic waveforms at the ankle, PSV 70cm/s.

Assessed by **Sharifa Kiyegga**

Printed on 25/01/2019 at 3:21 pm

Checked by _____

**Arterial Lower Limb Duplex**Examined **12/12/2018 15:40**

Page 2 of 2

Reference

Helen KerssAccession **CR-18-0065065**Patient **Barbara Sumner**NHS No **438 943 4144**D.O.B. **10/12/1935**Patient Ref **3196690**

Right resting ABPI not performed as patient scanned in a chair.