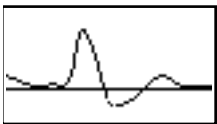
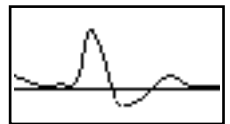
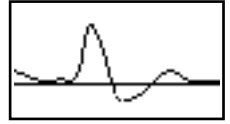
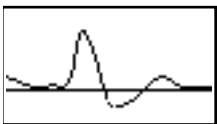
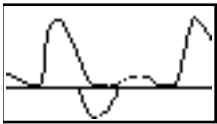
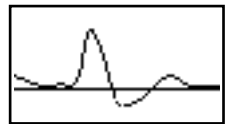
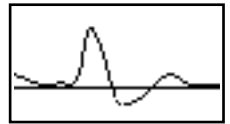


**Arterial Lower Limb Duplex**Examined **14/12/2018 10:16**

Page 1 of 2

Upendram Srinivas-Shankar

Reference

Accession **CR-18-0065443**Patient **Margaret Maney**
D.O.B. **28/01/1967**NHS No **610 710 2191**
Patient Ref **5050942**Reason **Ulceration**Outcome **Calcified****Right** **Brachial****Common Femoral****Left****High Thigh****Low Thigh****Popliteal****High Calf****Peroneal** **Anterior Tibial** **Posterior Tibial****Dorsalis Pedis****Toe Pressure****Post Exercise****Notes****BILATERAL LOWER LIMB ARTERIAL DUPLEX**

*Vessel calcification noted throughout.

RIGHT:

CFA, PFA origin, SFA and PopA - patent, good triphasic waveforms, PSV 124-256cm/s.

TPT is patent.

ATA and PTA - patent at the ankle, good triphasic waveforms, PSV 123-129cm/s.

Assessed by **Sharifa Kiyegga**

Printed on 25/01/2019 at 3:33 pm

Checked by _____

**Arterial Lower Limb Duplex**Examined **14/12/2018 10:16**

Page 2 of 2

Reference

Upendram Srinivas-ShankarAccession **CR-18-0065443**Patient **Margaret Maney**NHS No **610 710 2191**D.O.B. **28/01/1967**Patient Ref **5050942****LEFT:**

CFA, PFA origin, SFA and PopA - widely patent, good triphasic waveforms, PSV 121-178cm/s.

TPT is patent.

ATA, PTA and pero A - patent at the ankle, good triphasic waveforms, PSV 60-97cm/s.

Bilateral resting ABPI's are good (Right - 1.03, Left - 1.03).

Additional comment: Enlarged lymph nodes noted in the right groin.

High patient brachial systolic pressure noted (204mmHg).