

**Arterial Lower Limb Duplex**Examined **14/01/2019 09:55**

Page 1 of 2

**Gareth Harrison**

Reference

Accession **CR-19-0002360**

Patient **Richard Lloyd**  
D.O.B. **28/04/1965**

NHS No **612 893 9171**  
Patient Ref **5515315**

Reason **Ulceration**Outcome **Calcified****Right**

108

1.00

**Brachial****Common Femoral**

Good

**High Thigh****Low Thigh****Popliteal**

Good

**High Calf****Peroneal****Anterior Tibial**

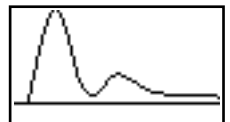
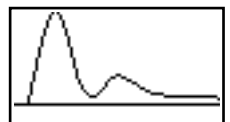
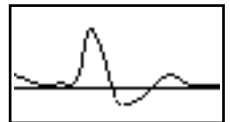
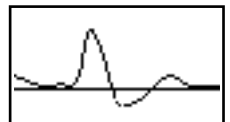
Good

**Posterior Tibial**

Good

120

1.11

**Dorsalis Pedis****Toe Pressure****Post Exercise****Left****Notes****LEFT LOWER LIMB ARTERIAL DUPLEX**

CFA, PFA origin - patent with calcified disease, triphasic waveforms, PSV 94-63cm/s.

SFA - patent with calcified disease. obscured region noted in the distal thigh vessel, good triphasic waveforms throughout, PSV 76-77cm/s.

Pop A- patent with calcified vessel walls, good triphasic waveforms, PSV 74-107cm/s.

TPT is patent with calcified disease. 3 run-off origins noted.

ATA, PTA - calcified but patent along length, bouncy monophasic waveforms at the ankle, PSV

Assessed by **Sharifa Kiyegga**

Printed on 25/01/2019 at 4:15 pm

Checked by \_\_\_\_\_

**Arterial Lower Limb Duplex**Examined **14/01/2019 09:55**

Page 2 of 2

Reference

**Gareth Harrison**Accession **CR-19-0002360**

---

Patient **Richard Lloyd**  
D.O.B. **28/04/1965**

NHS No **612 893 9171**  
Patient Ref **5515315**

---

102-101cm/s

Left resting ABPI's good (1.11).