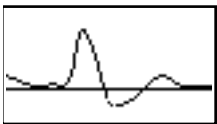


**Arterial Lower Limb Duplex**Examined **10/01/2019 09:10**


Page 1 of 2

Gareth Harrison

Reference

Accession **CR-19-0001691**Patient **George Dodd**
D.O.B. **28/10/1940**NHS No **440 644 8268**
Patient Ref **3030809**Reason Routine
Outcome Occlusion**Right****Left****Brachial**

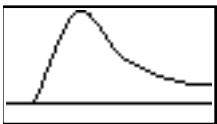
Good

Common Femoral**High Thigh****Low Thigh**

Weak/Absent

Popliteal**High Calf****Peroneal**

Weak

Anterior Tibial

Slightly Reduced

Posterior Tibial**Dorsalis Pedis****Toe Pressure****Post Exercise****Notes****RIGHT LOWER LIMB ARTERIAL DUPLEX:**

CFA, PFA origin & SFA - widely patent, mild disease, bi/triphasic waveforms, PSV 74 - 177cm/s.

PopA - the proximal to mid vessel appears occluded with mixed echogenic material ?thrombus (total occlusion length 6cm). The distal vessel is widely patent, weak monophasic waveforms, PSV 17cm/s.

TPT is patent. 3 run-off origins noted.

ATA - patent proximally. Mid to distal vessel appears occluded with mixed echogenic material ?thrombus. Vessel appears patent at the ankle with weak monophasic waveforms, PSV 7cm/s, before it occludes again

Assessed by **Sharifa Kiyegga**

Printed on 25/01/2019 at 3:50 pm

Checked by _____



Arterial Lower Limb Duplex

Gareth Harrison

Examined 10/01/2019 09:10

Page 2 of 2

Reference

Accession CR-19-0001691

Patient George Dodd

NHS No 440 644 8268

D.O.B. 28/10/1940

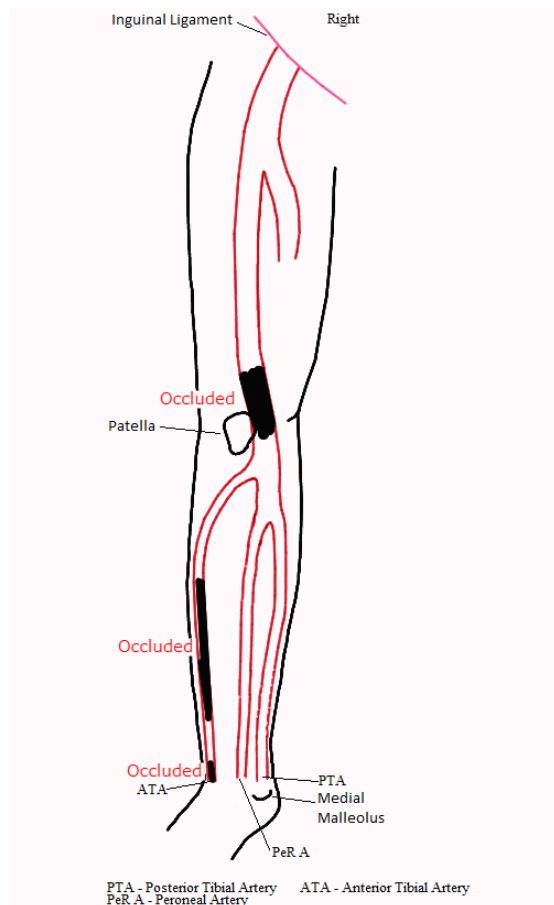
Patient Ref 3030809

with mixed echogenic material.

PTA - patent along length, slightly reduced monophasic waveforms, PSV 64cm/s.

Pero A - patent along length.

ABPI not performed due to the ?acute nature of disease.



Assessed by Sharifa Kiyegga

Printed on 25/01/2019 at 3:50 pm

Checked by