

Reason Varicose vein  
Outcome DVT negative, Competent

	Right		Left	
Deep Veins	Patency	Competency	Patency	Competency
Common Iliac Vein				
External Iliac Vein				
Internal Iliac Vein				
Common Femoral Vein			Patent	Competent
Profunda Vein			Patent	Competent
Superficial Femoral Vein			Patent	Competent
Popliteal Vein			Patent	Competent
Posterior Tibial Vein			Patent	Competent
Anterior Tibial Vein			Patent	Competent
Peroneal Vein			Patent	Competent
Soleal Vein			Patent	
Gastrocnemius			Patent	
Superficial Veins				
Saphenofemoral Junction			Patent	Competent
L Saphenous Vein Above			Patent	Competent
L Saphenous Vein Below			Patent	Competent
Vein of Giacomini			Patent	Competent
Saphenopopiteal Junction			Not Identified	
S Saphenous Vein			Patent	Competent
Evidence of D.V.T.				
Above the knee			No	
Popliteal			No	
Below the knee			No	

## Notes

### LEFT LOWER LIMB VENOUS DUPLEX ASSESSMENT

Iliac veins not viewed. Flow in the common femoral vein is phasic with respiration and a normal response on Valsalva manoeuvre, suggesting proximal vein patency. All visualised deep veins appear patent and competent with no evidence of previous DVT.

All measurements are proximal to the medial malleolus unless otherwise stated.

SFJ is patent and competent. LSV is patent and competent along its length.

SPJ not identified. SSV is patent and competent and is continuous with a competent vein of Giacomini.

Assessed by Jimmy Chen

Printed on 07/12/2018 at 10:52 am

Checked by



**Reason** Varicose vein  
**Outcome** DVT positive - chronic, Incompetence

<b>Right</b>		<b>Left</b>	
<b>Deep Veins</b>	<b>Patency</b>	<b>Competency</b>	<b>Competency</b>
Common Iliac Vein			
External Iliac Vein			
Internal Iliac Vein			
Common Femoral Vein		Widely Patent	Competent
Profunda Vein		Widely Patent	Competent
Superficial Femoral Vein		Widely Patent	Incompetent
Popliteal Vein		Recanalised	Old Thrombus
Posterior Tibial Vein		Patent	Incompetent
Anterior Tibial Vein		Patent	Competent
Peroneal Vein		Patent	Incompetent
Soleal Vein		Patent	
Gastrocnemius		Recanalised	Old Thrombus
<b>Superficial Veins</b>			
Saphenofemoral Junction		Patent	Competent
L Saphenous Vein Above		Patent	Competent
L Saphenous Vein Below		Patent	Competent
Vein of Giacomini		Not Identified	
Saphenopopiteal Junction		Recanalised	Old Thrombus
S Saphenous Vein		Patent	Incompetent
<b>Evidence of D.V.T.</b>			
Above the knee		No	
Popliteal		Yes	Old
Below the knee		Yes	Old

## Notes

### LEFT LOWER LIMB VENOUS DUPLEX ASSESSMENT

Iliac veins not viewed. Flow in the common femoral vein is phasic with respiration and a normal response on Valsalva manoeuvre, suggesting proximal vein patency. Common femoral and profunda femoral veins appear widely patent and competent with no evidence of previous DVT. Incompetent flow noted along the length of the superficial femoral vein and evidence of recanalised, old thrombus in the popliteal, posterior tibial, peroneal, and gastrocnemius veins, however no evidence of acute DVT detected. All other deep calf veins appear patent and competent with no evidence of acute or chronic DVT.

All measurements are proximal to the medial malleolus unless otherwise stated.

Assessed by Jimmy Chen

Printed on 07/12/2018 at 10:52 am

Checked by



SFJ is patent and competent. LSV is patent and competent along its length with an incompetent perforator in the distal calf at 12cm.

Neo-vascularised tissue noted in the groin with an incompetent ATV arising at the level of the SFJ trunk and appears small calibre proximally becoming larger in the prox-mid thigh. ATV leaves the fascia at 71cm (~17cm from the SFJ) and forms anterior thigh varicosities.

SSV forms a common trunk with a gastrocnemius vein to form an SPJ. SPJ appears slightly incompetent with evidence of recanalised old thrombus. SSV is patent and incompetent along its length, and tracks in a relatively linear fashion within a fascia in the calf. Incompetent branches in the prox and mid calf at 34cm and 24cm respectively. Incompetent perforator noted in the distal calf at 20cm.

Transverse (AP) dimensions of ATV:

Proximal thigh- 0.21cm,

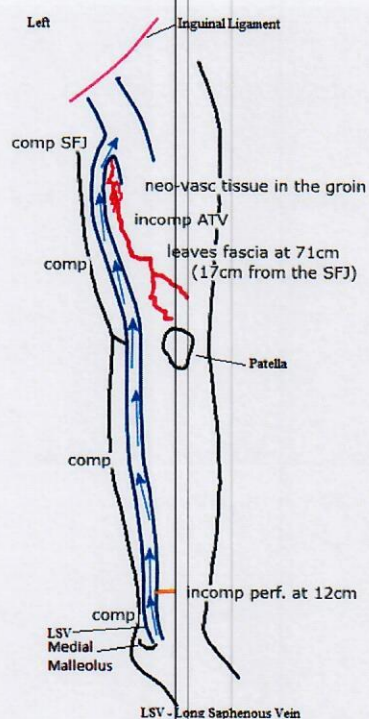
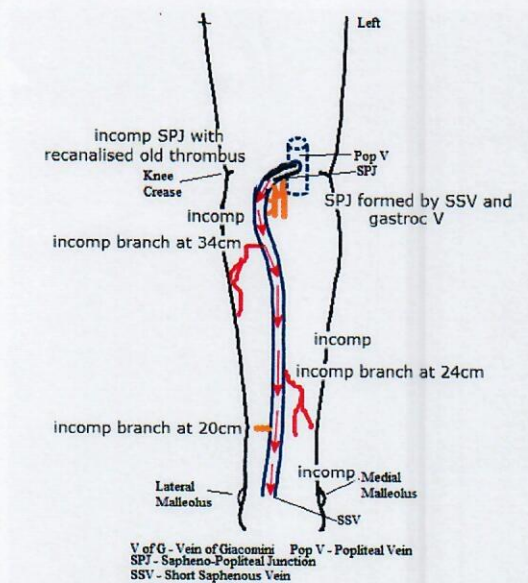
Mid thigh - 0.4cm,

Transverse (AP) dimensions of SSV:

Proximal calf- 0.48cm,

Mid calf - 0.51cm,

Distal calf - 0.26cm.



Assessed by Jimmy Chen

Printed on 07/12/2018 at 10:52 am

Checked by



**Reason** Varicose vein  
**Outcome** DVT negative, Incompetence

	<b>Right</b>		<b>Left</b>	
<b>Deep Veins</b>	<b>Patency</b>	<b>Competency</b>	<b>Patency</b>	<b>Competency</b>
Common Iliac Vein				
External Iliac Vein				
Internal Iliac Vein				
Common Femoral Vein	Widely Patent	Competent	Widely Patent	Competent
Profunda Vein	Widely Patent	Competent	Widely Patent	Competent
Superficial Femoral Vein	Widely Patent	Competent	Widely Patent	Competent
Popliteal Vein	Widely Patent	Competent	Widely Patent	Competent
Posterior Tibial Vein	Patent	Competent	Patent	Competent
Anterior Tibial Vein	Patent	Competent	Patent	Competent
Peroneal Vein	Patent	Competent	Patent	Competent
Soleal Vein	Patent		Patent	
Gastrocnemius	Patent		Patent	
<b>Superficial Veins</b>				
Saphenofemoral Junction	Patent	Incompetent	Patent	Incompetent
L Saphenous Vein Above	Patent	Incompetent	Patent	Isolated Incompetence
L Saphenous Vein Below	Patent	Incompetent	Patent	Isolated Incompetence
Vein of Giacomini	Patent	Competent	Patent	Competent
Saphenopopliteal Junction	Not Identified		Not Identified	
S Saphenous Vein	Patent	Competent	Patent	Competent
<b>Evidence of D.V.T.</b>				
Above the knee	No		No	
Popliteal	No		No	
Below the knee	No		No	

## Notes

### BILATERAL LOWER LIMB VENOUS DUPLEX ASSESSMENT

\*challenging scan due to poor mobility.

Iliac veins not viewed bilaterally. Flow in the common femoral veins are phasic with respiration and a normal response on Valsalva manoeuvre, suggesting proximal vein patency. All visualised deep veins appear widely patent and competent with no evidence of previous DVT.

All measurements are proximal to the medial malleolus unless otherwise stated.

#### RIGHT

SFJ is patent and incompetent. LSV is patent and incompetent proximally before leaving the fascia in the prox thigh at 57cm (~11cm from groin). LSV remains incompetent and tracks in a relatively linear fashion in

Assessed by Jimmy Chen

Printed on 07/12/2018 at 10:53 am

Checked by



the medial thigh. LSV is slightly tortuous in the mid-distal thigh at 47cm.  
Calf LSV is patent and incompetent. Incompetent branch leaves the mid calf at 19cm and continues to communicate with an incompetent perforator in the distal calf at 10cm.  
Competent perforators noted in the mid and distal calf at 24cm and 16cm.

SPJ not identified. SSV is patent and competent and is continuous with a competent vein of Giacomini.

Transverse (AP) dimensions of LSV:

Proximal thigh- 0.6cm,  
Mid thigh - 0.54cm,  
Distal thigh - 0.4cm.  
Proximal calf- 0.38cm,  
Mid calf - 0.4cm,  
Distal calf - 0.43cm.

#### LEFT

SFJ is patent and incompetent. LSV is patent and incompetent proximally. Incompetent branch leaves in the prox thigh at 62cm (~11cm from groin). Distal to this, LSV becomes competent and remains so to the knee. Calf LSV is patent and competent. Competent perforator noted at 19cm. Incompetent branch communicates with the mid LSV at 18cm. Distal to this, LSV becomes incompetent. Competent perforator noted in the distal calf at 13cm and gives rise to a competent branch which communicates with the distal LSV at 11cm. LSV remains incompetent at the ankle.

SPJ not identified. SSV is patent and competent and is continuous with a competent vein of Giacomini.

Transverse (AP) dimensions of LSV:

Proximal thigh- 0.63cm,  
Mid thigh - 0.28cm,  
Distal thigh - 0.36cm.  
Proximal calf- 0.17cm,  
Mid calf - 0.41cm,  
Distal calf - 0.44cm.

---

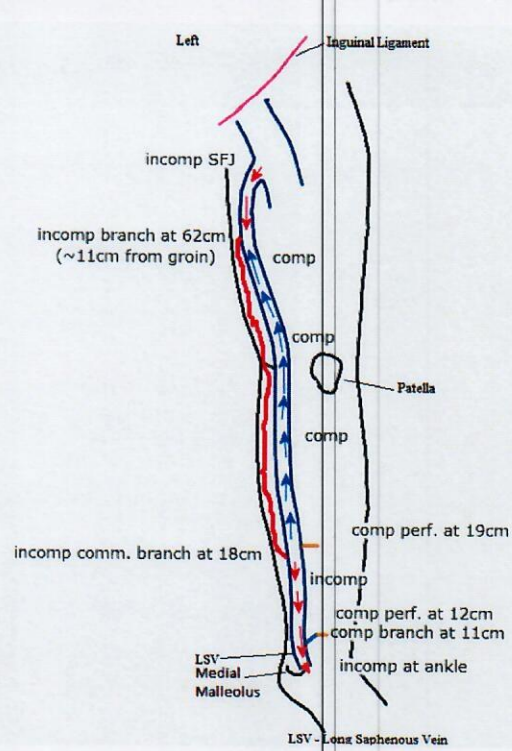
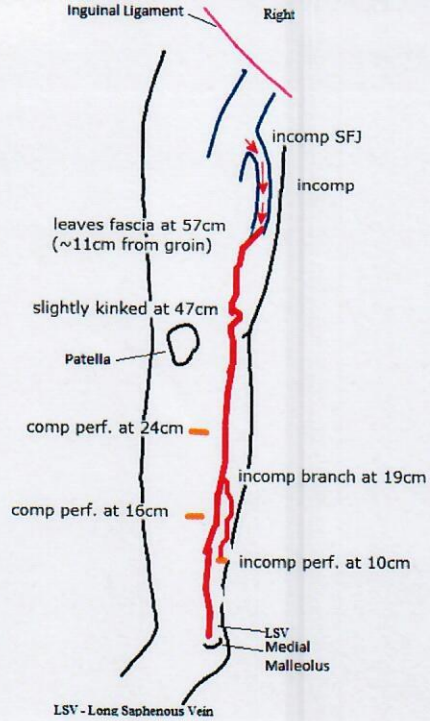
Assessed by Jimmy Chen

Printed on 07/12/2018 at 10:53 am

Checked by

---





Assessed by Jimmy Chen  
Printed on 07/12/2018 at 10:53 am

Checked by



**Reason** Varicose vein  
**Outcome** DVT negative, Incompetence

	<b>Right</b>		<b>Left</b>	
<b>Deep Veins</b>	<b>Patency</b>	<b>Competency</b>	<b>Patency</b>	<b>Competency</b>
Common Iliac Vein				
External Iliac Vein				
Internal Iliac Vein				
Common Femoral Vein	Widely Patent	Competent		
Profunda Vein	Widely Patent	Competent		
Superficial Femoral Vein	Widely Patent	Competent		
Popliteal Vein	Widely Patent	Competent		
Posterior Tibial Vein	Widely Patent	Competent		
Anterior Tibial Vein	Widely Patent	Competent		
Peroneal Vein	Widely Patent	Competent		
Soleal Vein	Patent			
Gastrocnemius	Patent			
<b>Superficial Veins</b>				
Saphenofemoral Junction	Patent	Competent		
L Saphenous Vein Above	Patent	Competent		
L Saphenous Vein Below	Patent	Competent		
Vein of Giacomini	Patent	Competent		
Saphenopopiteal Junction	Patent	Competent		
S Saphenous Vein	Patent	Isolated Incompetence		
<b>Evidence of D.V.T.</b>				
Above the knee	No			
Popliteal	No			
Below the knee	No			

### Notes

RIGHT LOWER LIMB VENOUS DUPLEX ASSESSMENT - scanned in clinic

Iliac veins not viewed. Flow in the common femoral vein is phasic with respiration and a normal response on Valsalva manoeuvre, suggesting proximal vein patency. All visualised deep veins appear widely patent and competent with no evidence of previous DVT.

All measurements are proximal to the medial malleolus unless otherwise stated.

SFJ is patent and competent. LSV is patent and competent along its length.

SPJ is patent and competent. Vein of Giacomini is patent and competent with an incompetent branch noted above the level of the knee at 51cm (~10cm above the level of the SPJ), and form visible posterior calf

Assessed by Jimmy Chen

Printed on 07/12/2018 at 10:50 am

Checked by



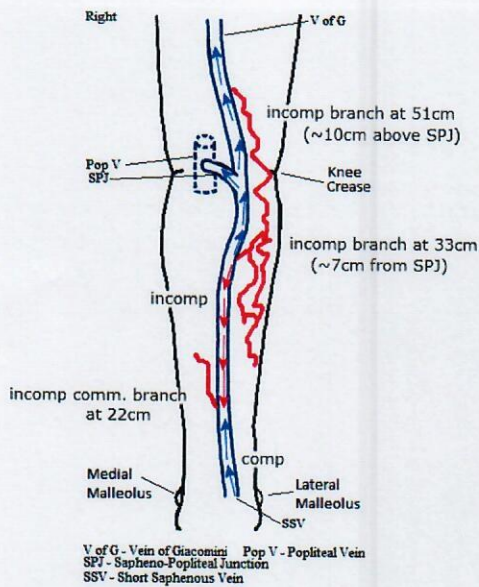
varicosities. LSV is patent and competent in the prox calf before an incompetent branch communicates in the prox calf at 33cm (~7cm from the level of the SPJ). LSV becomes incompetent distal to this. A further incompetent branch communicates with the LSV in the mid calf at 22cm. LSV is competent distal to this and remains so to the ankle.

Transverse (AP) dimensions of SSV:

Proximal calf- 0.5cm,

Mid calf - 0.47cm,

Distal calf - 0.26cm.



Assessed by Jimmy Chen

Printed on 07/12/2018 at 10:50 am

Checked by



**Reason** Varicose vein  
**Outcome** DVT negative, Incompetence

	<b>Right</b>		<b>Left</b>	
<b>Deep Veins</b>	<b>Patency</b>	<b>Competency</b>	<b>Patency</b>	<b>Competency</b>
Common Iliac Vein				
External Iliac Vein				
Internal Iliac Vein				
Common Femoral Vein	Patent	Competent	Patent	Competent
Profunda Vein	Patent	Competent	Patent	Competent
Superficial Femoral Vein	Patent	Competent	Patent	Competent
Popliteal Vein	Patent	Competent	Patent	Competent
Posterior Tibial Vein	Patent	Competent	Patent	Competent
Anterior Tibial Vein	Patent	Competent	Patent	Competent
Peroneal Vein	Patent	Competent	Patent	Competent
Soleal Vein	Patent		Patent	
Gastrocnemius	Patent		Patent	
<b>Superficial Veins</b>				
Saphenofemoral Junction	Patent	Competent	Patent	Incompetent
L Saphenous Vein Above	Patent	Competent	Patent	Isolated Incompetence
L Saphenous Vein Below	Patent	Competent	Patent	Competent
Vein of Giacomini	Patent	Competent	Patent	Competent
Saphenopopliteal Junction	Not Identified		Not Identified	
S Saphenous Vein	Patent	Competent	Patent	Competent
<b>Evidence of D.V.T.</b>				
Above the knee	No		No	
Popliteal	No		No	
Below the knee	No		No	

### Notes

#### BILATERAL LOWER LIMB VENOUS DUPLEX ASSESSMENT

\*sub-optimal images obtained due to superficial oedema and patient habitus.

Iliac veins not viewed bilaterally. Flow in the common femoral veins are phasic with respiration and a normal response on Valsalva manoeuvre, suggesting proximal vein patency bilaterally. All visualised deep veins appear patent and competent with no evidence of previous DVT, bilaterally.

All measurements are proximal to the medial malleolus unless otherwise stated.

#### RIGHT

SFJ is patent and competent. LSV is patent and competent along its length.

Assessed by Jimmy Chen

Printed on 07/12/2018 at 10:51 am

Checked by



SPJ not identified. SSV is patent and competent and is continuous with a competent vein of Giacomini.

LEFT

SFJ is patent and incompetent. LSV is patent and incompetent before vessel becomes slightly tortuous in the prox thigh at 53cm (~12cm from SFJ), distal to this, LSV becomes competent and remains so to the ankle.

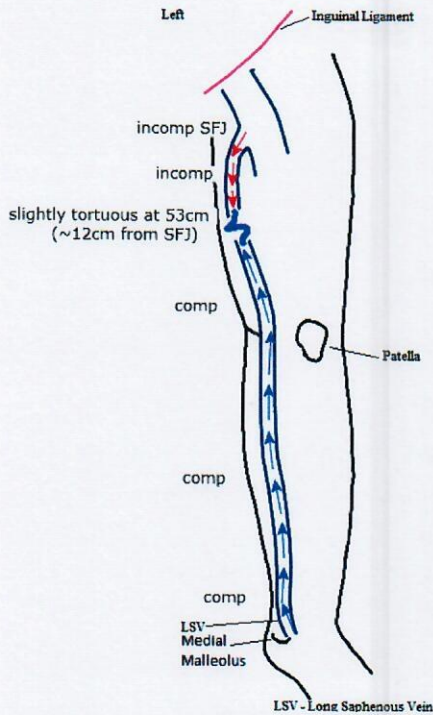
SPJ not identified. SSV is patent and competent and is continuous with a competent vein of Giacomini.

Transverse (AP) dimensions of LSV:

Proximal thigh- 0.7cm,

Mid thigh - 0.63cm,

Distal thigh - 0.57cm.



Assessed by Jimmy Chen

Printed on 07/12/2018 at 10:51 am

Checked by



**Reason** Varicose vein  
**Outcome** DVT negative, Incompetence

	<b>Right</b>		<b>Left</b>	
<b>Deep Veins</b>	<b>Patency</b>	<b>Competency</b>	<b>Patency</b>	<b>Competency</b>
Common Iliac Vein				
External Iliac Vein				
Internal Iliac Vein				
Common Femoral Vein	Widely Patent	Competent		
Profunda Vein	Widely Patent	Competent		
Superficial Femoral Vein	Widely Patent	Competent		
Popliteal Vein	Widely Patent	Competent		
Posterior Tibial Vein	Widely Patent	Competent		
Anterior Tibial Vein	Widely Patent	Competent		
Peroneal Vein	Widely Patent	Competent		
Soleal Vein	Patent			
Gastrocnemius	Patent			
<b>Superficial Veins</b>				
Saphenofemoral Junction	Patent	Competent		
L Saphenous Vein Above	Patent	Isolated Incompetence		
L Saphenous Vein Below	Patent	Isolated Incompetence		
Vein of Giacomini	Not Identified			
Saphenopopliteal Junction	Patent	Competent		
S Saphenous Vein	Patent	Competent		
<b>Evidence of D.V.T.</b>				
Above the knee	No			
Popliteal	No			
Below the knee	No			

### Notes

#### RIGHT LOWER LIMB VENOUS DUPLEX ASSESSMENT

Iliac veins not viewed. Flow in the common femoral vein is phasic with respiration and a normal response on Valsalva manoeuvre, suggesting proximal vein patency. All visualised deep veins appear widely patent and competent with no evidence of previous DVT.

All measurements are proximal to the medial malleolus unless otherwise stated.

SFJ is patent and competent.

ATV is patent and competent proximally with an incompetent branch at 73cm (~5cm from SFJ), and forms anterior thigh varicosities. Distal to this, ATV remains competent in the thigh.

LSV is patent and competent proximally. LSV leaves the fascia at 68cm (~10cm from SFJ), and becomes

Assessed by Jimmy Chen

Printed on 07/12/2018 at 10:47 am

Checked by



incompetent in the thigh. LSV reforms in the prox calf at 36cm and becomes competent for a short section before an incompetent branch communicates in the prox calf at 30cm. LSV becomes incompetent distal to this. Incompetent branches communicate in the distal calf at 9cm, distal to this, LSV becomes competent and remains so to the ankle.

SPJ is patent and competent. SSV is patent and competent along its length.

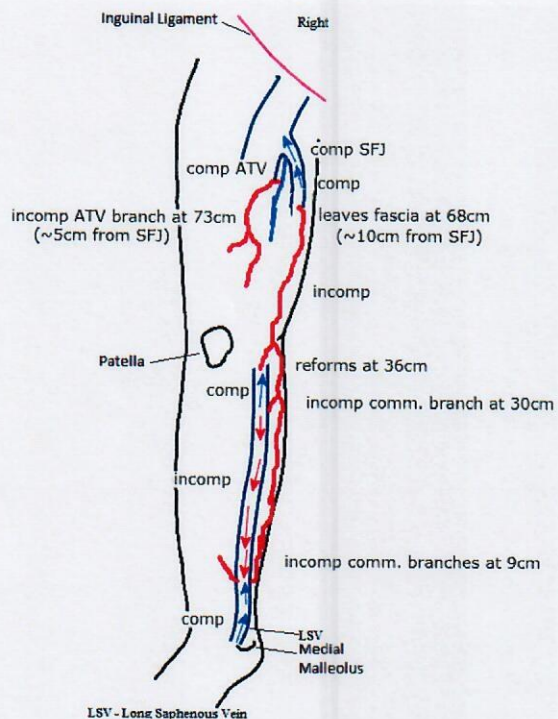
Transverse (AP) dimensions of LSV:

Proximal thigh- 0.34cm,

Proximal calf- 0.35cm,

Mid calf - 0.45cm,

Distal calf - 0.4cm.



Assessed by Jimmy Chen

Printed on 07/12/2018 at 10:47 am

Checked by

**Reason** Varicose vein  
**Outcome** DVT negative, Incompetence

	<b>Right</b>		<b>Left</b>	
<b>Deep Veins</b>	<b>Patency</b>	<b>Competency</b>	<b>Patency</b>	<b>Competency</b>
Common Iliac Vein				
External Iliac Vein				
Internal Iliac Vein				
Common Femoral Vein	Patent	Competent	Patent	Competent
Profunda Vein	Patent	Competent	Patent	Competent
Superficial Femoral Vein	Patent	Competent	Patent	Competent
Popliteal Vein	Patent	Competent	Patent	Competent
Posterior Tibial Vein	Patent	Competent	Patent	Isolated Incompetence
Anterior Tibial Vein	Patent	Competent	Patent	Competent
Peroneal Vein	Patent	Competent	Patent	Competent
Soleal Vein	Patent		Patent	
Gastrocnemius	Patent		Patent	
<b>Superficial Veins</b>				
Saphenofemoral Junction	Not Identified		Not Identified	
L Saphenous Vein Above	Not Identified		Occlusive and non-occlusive	Mixed Thrombus
L Saphenous Vein Below	Patent	Incompetent	Patent	Incompetent
Vein of Giacomini	Patent	Competent	Not Identified	
Saphenopopliteal Junction	Patent	Competent	Patent	Competent
S Saphenous Vein	Patent	Incompetent	Patent	Competent
<b>Evidence of D.V.T.</b>				
Above the knee	No		No	
Popliteal	No		No	
Below the knee	No		No	

### Notes

BILATERAL LOWER LIMB VENOUS DUPLEX ASSESSMENT - scanned in clinic.

Iliac veins not viewed bilaterally. Flow in the common femoral veins are phasic with respiration and a normal response on Valsalva manoeuvre, suggesting proximal vein patency bilaterally.

All measurements are proximal to the medial malleolus unless otherwise stated.

### RIGHT

All visualised deep veins appear patent and competent with no evidence of previous DVT.

SFJ not identified. LSV not identified in the thigh. LSV reforms at the level of the knee at 46cm.

LSV is patent and incompetent. Incompetent branches noted in the prox calf at 37cm and 32cm, which form

Assessed by Jimmy Chen

Printed on 07/12/2018 at 10:48 am

Checked by



calf varicosities. Incompetent perforator noted in the mid calf at 24cm. Distal to this, LSV becomes competent and remains so to the ankle.

SPJ is patent and competent. Vein of Giacomini is patent and competent. Prox-mid SSV is patent and incompetent. Incompetent branch communicates in the mid calf at 31cm, distal to this, SSV becomes competent and remains so to the ankle.

Transverse (AP) dimensions of LSV:

Proximal calf- 0.6cm,

Mid calf - 0.3cm,

Distal calf - 0.3cm.

Transverse (AP) dimensions of SSV:

Proximal calf- 0.43cm,

Mid calf - 0.28cm,

Distal calf - 0.16cm.

#### LEFT

All visualised deep veins, proximal to and including the popliteal vein, appear patent and competent with no evidence of previous DVT.

Isolated incompetence noted in 1x posterior tibial vein. All other deep calf veins appear patent and competent with no evidence of previous DVT.

?incompetent vein arises above the level of the SFJ ?pelvic vein.

SFJ not identified. Neo-vascularised tissue noted in the groin. LSV not identified in the prox thigh. LSV reforms in the mid thigh at 63cm which is incompetent with evidence of non-occlusive thrombophlebitis. Incompetent branch leaves the mid thigh at ~58cm and forms visible thigh and knee varicosities. Distal to this, LSV is occluded for a short section before becoming patent and incompetent in the distal thigh at 53cm.

Difficulty assessing calf due to patient discomfort. However, where seen, LSV is patent and incompetent in the calf. Incompetent branches noted in the prox and mid calf at 37cm and 31cm which form calf varicosities. Distal to this, LSV remains incompetent to the ankle.

SPJ is patent and competent. SSV is patent and competent along its length.

Transverse (AP) dimensions of LSV:

Mid thigh - 0.55cm

Distal thigh - 0.89

Proximal calf- 0.62cm,

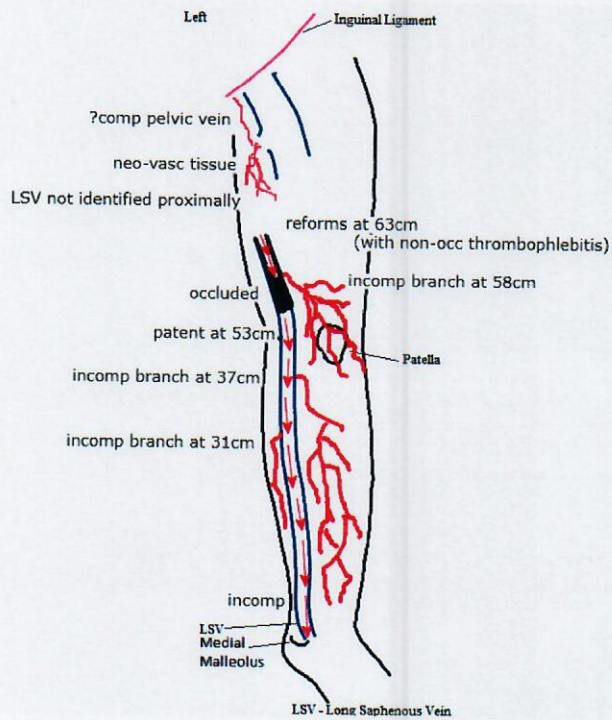
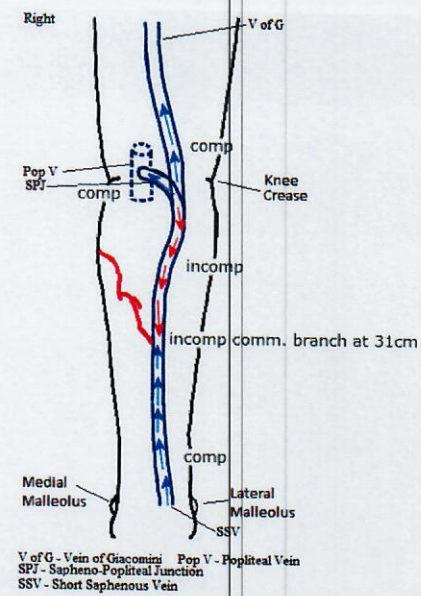
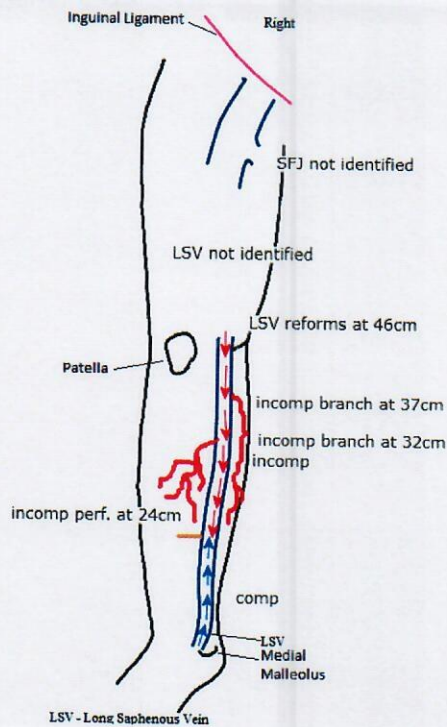
Mid calf - 0.3cm,

Distal calf - 0.39cm.

Assessed by Jimmy Chen

Printed on 07/12/2018 at 10:48 am

Checked by



Assessed by Jimmy Chen  
Printed on 07/12/2018 at 10:48 am

Checked by



**Reason** Varicose vein  
**Outcome** DVT negative, Incompetence

	<b>Right</b>		<b>Left</b>	
<b>Deep Veins</b>	<b>Patency</b>	<b>Competency</b>	<b>Patency</b>	<b>Competency</b>
Common Iliac Vein				
External Iliac Vein				
Internal Iliac Vein				
Common Femoral Vein	Patent	Competent		
Profunda Vein	Patent	Competent		
Superficial Femoral Vein	Patent	Competent		
Popliteal Vein	Patent	Competent		
Posterior Tibial Vein	Patent	Competent		
Anterior Tibial Vein	Patent	Competent		
Peroneal Vein	Patent	Competent		
Soleal Vein	Patent			
Gastrocnemius	Patent			
<b>Superficial Veins</b>				
Saphenofemoral Junction	Patent	Incompetent		
L Saphenous Vein Above	Patent	Isolated Incompetence		
L Saphenous Vein Below	Patent	Isolated Incompetence		
Vein of Giacomini	Not Identified			
Saphenopopiteal Junction	Patent	Competent		
S Saphenous Vein	Patent	Competent		
<b>Evidence of D.V.T.</b>				
Above the knee	No			
Popliteal	No			
Below the knee	No			

## Notes

### RIGHT LOWER LIMB VENOUS DUPLEX ASSESSMENT

Iliac veins not viewed. Proximal common femoral vein not clearly visualised ?due to depth. However, flow in the distal common femoral vein is phasic with respiration and a normal response on Valsalva manoeuvre , suggesting proximal vein patency.

All visualised deep veins appear patent and competent with no evidence of previous DVT.

All measurements are proximal to the medial malleolus unless otherwise stated.

SFJ is patent and incompetent. LSV is patent, incompetent proximally. Incompetent branch leaves the prox thigh at 72cm (~13cm from the SFJ), and forms visible medial thigh varicosities. Distal to the branch, LSV becomes competent with a competent branch in the prox thigh at 69cm. Incompetent branch in the

Assessed by Jimmy Chen

Printed on 07/12/2018 at 10:45 am

Checked by

prox-mid thigh at 58cm and communicates with thigh varicosities. LSV becomes incompetent distal to this, and remains so to the distal thigh where the LSV becomes varicosed at 49cm. Incompetent branch in the prox calf at 32cm forming calf varicosities. Distal to this, LSV becomes small calibre and competent before leaving the fascia and communicating with varicosities at 24cm. LSV not identified distal to this, however reforms in the mid calf at 20cm and is competent to the ankle.

SPJ is patent and competent. SSV is patent and competent and is continuous with a competent vein of Giacomini.

Transverse (AP) dimensions of LSV:

Proximal thigh - 0.8cm,

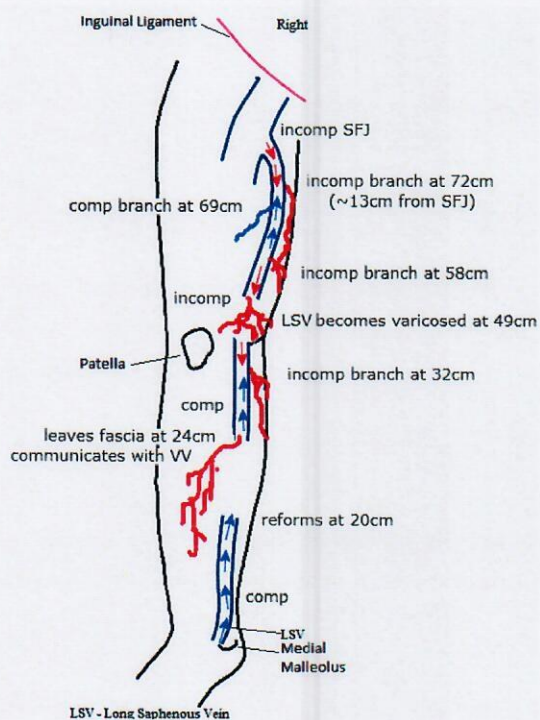
Mid thigh - 0.35cm,

Distal thigh - 0.45cm.

Proximal calf - 0.41cm,

Mid calf - 0.29cm,

Distal calf - 0.25cm.



Assessed by Jimmy Chen

Printed on 07/12/2018 at 10:45 am

Checked by



**Reason** Varicose vein  
**Outcome** DVT negative, Superficial oedema, Incompetence

	<b>Right</b>		<b>Left</b>	
<b>Deep Veins</b>	<b>Patency</b>	<b>Competency</b>	<b>Patency</b>	<b>Competency</b>
Common Iliac Vein				
External Iliac Vein				
Internal Iliac Vein				
Common Femoral Vein	Patent	Competent	Patent	Competent
Profunda Vein	Patent	Competent	Patent	Competent
Superficial Femoral Vein	Patent	Incompetent	Patent	Competent
Popliteal Vein	Patent	Incompetent	Patent	Competent
Posterior Tibial Vein	Patent	Competent	Patent	Competent
Anterior Tibial Vein	Patent	Competent	Patent	Competent
Peroneal Vein	Patent	Competent	Patent	Competent
Soleal Vein	Patent		Patent	
Gastrocnemius	Patent		Patent	
<b>Superficial Veins</b>				
Saphenofemoral Junction	Patent	Competent	Patent	Competent
L Saphenous Vein Above	Patent	Competent	Patent	Isolated Incompetence
L Saphenous Vein Below	Patent	Competent	Patent	Isolated Incompetence
Vein of Giacomini	Not Identified		Patent	Competent
Saphenopopliteal Junction	Not Identified		Not Identified	
S Saphenous Vein	Patent	Competent	Patent	Competent
<b>Evidence of D.V.T.</b>				
Above the knee	No		No	
Popliteal	No		No	
Below the knee	No		No	

## Notes

### BILATERAL LOWER LIMB VENOUS DUPLEX ASSESSMENT

#### RIGHT

Iliac veins not viewed. Flow in the common femoral vein is phasic with respiration and a normal response on Valsalva manoeuvre, suggesting proximal vein patency.

Common femoral and profunda femoris veins appear patent and competent with no evidence of previous DVT. The superficial femoral and popliteal vein appears incompetent, with no evidence of previous DVT. All visualised deep calf veins appear patent and competent with no evidence of previous DVT.

All measurements are proximal to the medial malleolus unless otherwise stated.

SFJ is patent and competent. LSV is patent and competent along its length. Competent branch noted in the

Assessed by Jimmy Chen

Printed on 07/12/2018 at 10:45 am

Checked by



mid thigh at 56cm. Further competent branches noted in the prox-mid calf at 31cm and 14cm, respectively. Competent perforator in the mid calf at 13cm.

SPJ not identified. SSV reforms in the prox calf at 30cm and appears competent along its length.

#### LEFT

Iliac veins not viewed. Flow in the common femoral vein is phasic with respiration and a normal response on Valsalva manoeuvre, suggesting proximal vein patency. All visualised deep veins appear patent and competent with no evidence of previous DVT.

SFJ is patent and competent. LSV is patent and competent in the prox-mid thigh. Competent branch noted in the mid thigh at 56cm, distal to this, LSV remains competent for a short section before leaving the fascia in the distal thigh at 50cm, and becoming incompetent to the knee. LSV reforms in the prox calf at 38cm and is competent. Incompetent branches in the prox calf at 37cm and 36cm, respectively. LSV leaves the fascia in the prox-mid calf at 35cm and remains competent, and reforms in the mid calf at 29cm. Competent branches leaves at the mid calf at 25cm and communicate with a competent perforator at 24cm, distal to the branches, LSV remains competent to the ankle.

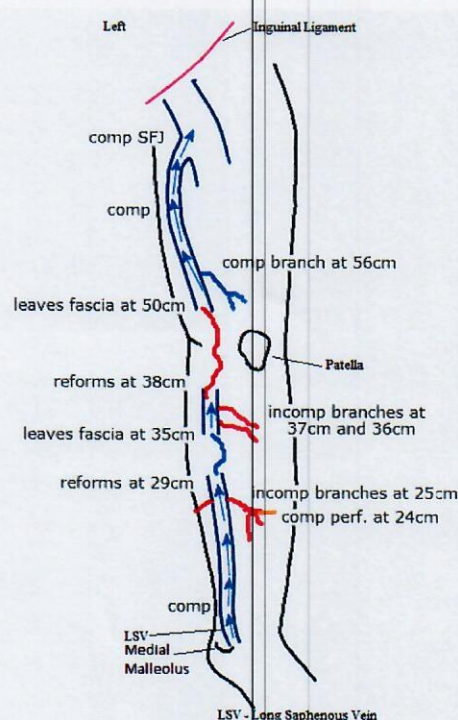
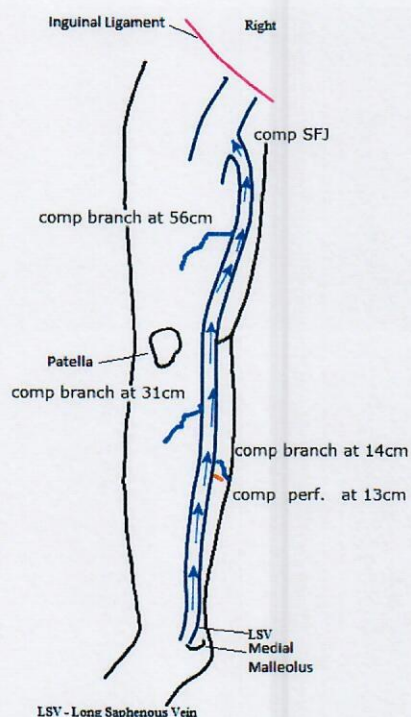
SPJ not identified. SSV is patent and competent and is continuous with a competent vein of Giacomini.

Transverse (AP) dimensions of LSV:

Proximal calf- 0.3cm,

Mid calf - 0.29cm,

Distal calf - 0.38cm.



Assessed by Jimmy Chen

Printed on 07/12/2018 at 10:45 am

Checked by



**Reason** Varicose vein  
**Outcome** DVT negative, Incompetence

	<b>Right</b>		<b>Left</b>	
<b>Deep Veins</b>	<b>Patency</b>	<b>Competency</b>	<b>Patency</b>	<b>Competency</b>
Common Iliac Vein				
External Iliac Vein				
Internal Iliac Vein				
Common Femoral Vein	Widely Patent	Competent		
Profunda Vein	Widely Patent	Competent		
Superficial Femoral Vein	Widely Patent	Incompetent		
Popliteal Vein	Widely Patent	Incompetent		
Posterior Tibial Vein	Widely Patent	Competent		
Anterior Tibial Vein	Widely Patent	Competent		
Peroneal Vein	Widely Patent	Incompetent		
Soleal Vein	Patent			
Gastrocnemius	Patent			
<b>Superficial Veins</b>				
Saphenofemoral Junction	Patent	Competent		
L Saphenous Vein Above	Patent	Isolated Incompetence		
L Saphenous Vein Below	Patent	Isolated Incompetence		
Vein of Giacomini	Patent	Competent		
Saphenopopliteal Junction	Not Identified			
S Saphenous Vein	Patent	Competent		
<b>Evidence of D.V.T.</b>				
Above the knee	No			
Popliteal	No			
Below the knee	No			

## Notes

### RIGHT LOWER LIMB VENOUS DUPLEX ASSESSMENT

Iliac veins not viewed. Flow in the common femoral vein is phasic with respiration and a normal response on Valsalva manoeuvre, suggesting proximal vein patency. Common femoral and profunda femoris veins appear widely patent and competent with no evidence of previous DVT. Incompetent flow noted in the superficial femoral, popliteal and 2x peroneal veins. All other deep calf veins appear widely patent and competent with no evidence of previous DVT

All measurements are proximal to the medial malleolus unless otherwise stated.

SFJ is patent and competent. ATV is patent, competent and tracks relatively linear within a fascia in the prox thigh. ATV leaves the fascia in the mid thigh at 53cm. and becomes incompetent, and forms thigh

Assessed by Jimmy Chen

Printed on 07/12/2018 at 10:46 am

Checked by



varicosities.

LSV is patent, competent and tracks relatively linear within a fascia in the prox-mid thigh. Incompetent perforator noted in the prox-mid thigh at 60cm. Incompetent branch leaves the mid thigh at 57cm, and communicates with thigh varicosities. Distal to this, LSV leaves the fascia at 56cm and becomes incompetent in the distal thigh. LSV reforms in the prox calf.

Incompetent branch leaves the prox calf at 37cm, distal to this, LSV remains incompetent before an further incompetent branch in the mid calf at 30cm. LSV becomes competent and remains so to the ankle. Competent perforator noted in the mid calf at 24cm.

Incompetent perforator noted in the distal calf and forms postero-lateral varicosities.

SPJ not identified. SSV is patent and competent along its length and is continuous with a competent vein of Giacomini. Competent branch noted in the mid calf at 23cm and communicates with distal calf varicosities.

Transverse (AP) dimensions of LSV:

Proximal thigh- 0.54cm,

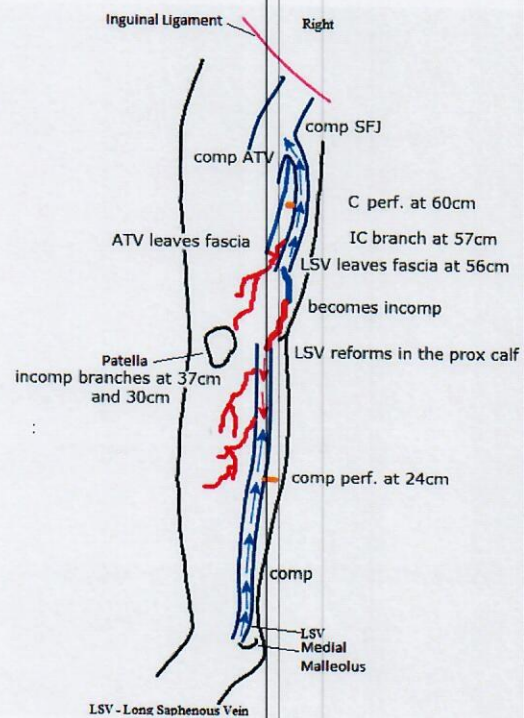
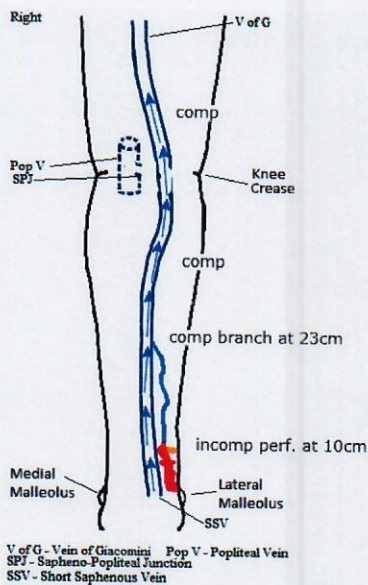
Mid thigh - 0.6cm,

Distal thigh - 0.72cm.

Proximal calf- 0.47cm,

Mid calf - 0.44cm,

Distal calf - 0.32cm.



Assessed by Jimmy Chen

Printed on 07/12/2018 at 10:46 am

Checked by



**Reason** Varicose vein  
**Outcome** Incompetence

<b>Right</b>		<b>Left</b>	
<b>Deep Veins</b>	<b>Patency</b>	<b>Patency</b>	<b>Competency</b>
Common Iliac Vein			
External Iliac Vein			
Internal Iliac Vein			
Common Femoral Vein		Patent	Competent
Profunda Vein		Patent	Competent
Superficial Femoral Vein		Patent	Competent
Popliteal Vein		Patent	Competent
Posterior Tibial Vein		Patent	Competent
Anterior Tibial Vein		Patent	Competent
Peroneal Vein		Patent	Competent
Soleal Vein		Patent	
Gastrocnemius		Patent	
<b>Superficial Veins</b>			
Saphenofemoral Junction		Patent	Competent
L Saphenous Vein Above		Not Identified	
L Saphenous Vein Below		Patent	Incompetent
Vein of Giacomini		Patent	Competent
Saphenopopliteal Junction		Not Identified	
S Saphenous Vein		Patent	Competent
<b>Evidence of D.V.T.</b>			
Above the knee		No	
Popliteal		No	
Below the knee		No	

## Notes

LEFT LOWER LIMB VENOUS DUPLEX ASSESSMENT - PREVIOUS EVLA.

Iliac veins not viewed. Flow in the common femoral vein is phasic with respiration and a normal response on Valsalva manoeuvre, suggesting proximal vein patency. All visualised deep veins appear patent and competent with no evidence of previous DVT.

All measurements are proximal to the medial malleolus unless otherwise stated.

SFJ is patent and competent. LSV not identified in the thigh.

LSV is patent and incompetent in the calf. Incompetent branch noted in the prox calf at 28cm. Competent branch in the mid calf at 19cm and incompetent perforator at 18cm.

Assessed by Jimmy Chen

Printed on 07/12/2018 at 10:42 am

Checked by

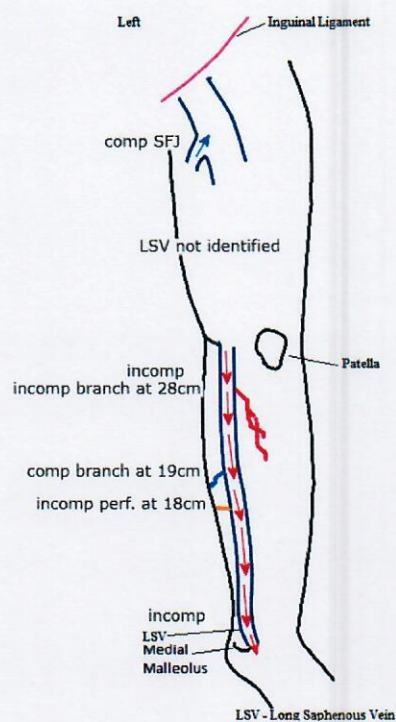
SPJ not identified. SSV is patent and competent and is continuous with a competent vein of Giacomini.

Transverse (AP) dimensions of LSV:

Proximal calf - 0.42cm,

Mid calf - 0.5cm,

Distal calf - 0.4cm.



Assessed by Jimmy Chen

Printed on 07/12/2018 at 10:42 am

Checked by



**Reason** Varicose vein

**Outcome** DVT negative, Superficial thrombophlebitis, Incompetence

	Right		Left	
Deep Veins	Patency	Competency	Patency	Competency
Common Iliac Vein				
External Iliac Vein				
Internal Iliac Vein				
Common Femoral Vein	Patent	Competent	Patent	Competent
Profunda Vein	Patent	Competent	Patent	Competent
Superficial Femoral Vein	Patent	Competent	Patent	Competent
Popliteal Vein	Patent	Competent	Patent	Competent
Posterior Tibial Vein	Patent	Competent	Patent	Competent
Anterior Tibial Vein	Patent	Competent	Patent	Competent
Peroneal Vein	Patent	Competent	Patent	Competent
Soleal Vein	Patent		Patent	
Gastrocnemius	Patent		Patent	
Superficial Veins				
Saphenofemoral Junction	Patent	Competent	Patent	Incompetent
L Saphenous Vein Above	Patent	Competent	Patent	Isolated Incompetence
L Saphenous Vein Below	Patent	Competent	Patent	Competent
Vein of Giacomini	Patent	Competent	Patent	Competent
Saphenopopliteal Junction	Patent	Competent	Not Identified	
S Saphenous Vein	Areas of Thrombus	Old Thrombus	Patent	Competent
Evidence of D.V.T.				
Above the knee	No		No	
Popliteal	No		No	
Below the knee	No		No	

## Notes

### BILATERAL LOWER LIMB VENOUS DUPLEX ASSESSMENT

Iliac veins not viewed bilaterally. Flow in the common femoral veins are phasic with respiration and a normal response on Valsalva manoeuvre, suggesting proximal vein patency bilaterally. All visualised deep veins appear patent and competent with no evidence of previous DVT bilaterally.

All measurements are proximal to the medial malleolus unless otherwise stated.

#### RIGHT

SFJ is patent and competent. LSV is patent and competent along its length.

SPJ is patent and competent. Vein of Giacomini is patent and competent. Old, non-occlusive superficial thrombophlebitis noted in the prox-mid SSV. Distal SSV appears patent and is competent to the ankle.

Assessed by Jimmy Chen

Printed on 07/12/2018 at 10:43 am

Checked by

LEFT

SFJ is patent and incompetent. LSV is patent and incompetent in the proximally with an incompetent branch in the prox thigh at 60 (~12cm from the SFJ), and tracks distally to form thigh and knee varicosities. Distal to the branch, LSV becomes competent and remains so to the ankle.

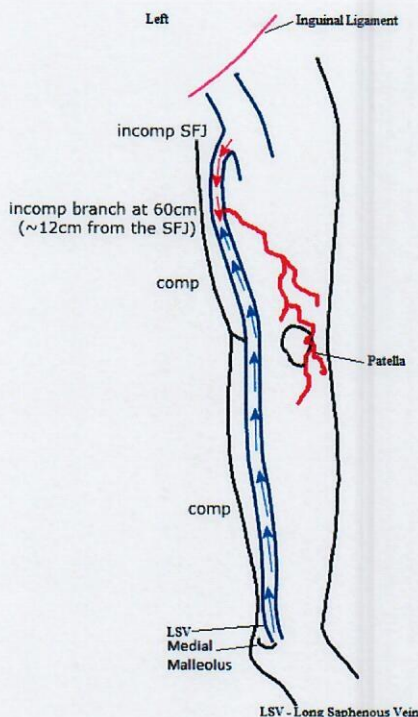
SPJ not identified. SSV is patent and competent and is continuous with a competent vein of Giacomini.

Transverse (AP) dimensions of LSV:

Proximal thigh- 0.53cm,

Mid thigh - 0.41cm,

Distal thigh - 0.31cm.



Assessed by Jimmy Chen

Printed on 07/12/2018 at 10:43 am

Checked by



Reason	Varicose vein			
Outcome	Incompetence, Superficial thrombophlebitis			
	<b>Right</b>		<b>Left</b>	
<b>Deep Veins</b>	<b>Patency</b>	<b>Competency</b>	<b>Patency</b>	<b>Competency</b>
Common Iliac Vein				
External Iliac Vein				
Internal Iliac Vein				
Common Femoral Vein			Widely Patent	Competent
Profunda Vein			Widely Patent	Competent
Superficial Femoral Vein			Widely Patent	Competent
Popliteal Vein			Widely Patent	Competent
Posterior Tibial Vein			Widely Patent	Competent
Anterior Tibial Vein			Widely Patent	Competent
Peroneal Vein			Widely Patent	Competent
Soleal Vein			Widely Patent	
Gastrocnemius			Widely Patent	
<b>Superficial Veins</b>				
Saphenofemoral Junction			Patent	Incompetent
L Saphenous Vein Above			Patent	Incompetent
L Saphenous Vein Below			Patent	Incompetent
Vein of Giacomini			Widely Patent	Competent
Saphenopopiteal Junction			Not Identified	
S Saphenous Vein			Patent	Isolated Incompetence
<b>Evidence of D.V.T.</b>				
Above the knee				
Popliteal				
Below the knee				
<b>Notes</b>				
<b>LEFT LOWER LIMB VENOUS DUPLEX ASSESSMENT</b>				
<p>Iliac veins not viewed. Flow in the common femoral vein is phasic with respiration and a normal response on Valsalva manoeuvre, suggesting proximal vein patency. All visualised deep veins appear widely patent and competent with no evidence of previous DVT.</p> <p>All measurements are proximal to the medial malleolus unless otherwise stated.</p> <p>SFJ is patent and incompetent. LSV is patent and incompetent in the prox-mid thigh. Competent perforator in the prox thigh at 61cm (~10cm from SFJ). LSV becomes slightly tortuous in the mid thigh at 50cm. Non-occlusive old superficial thrombophlebitis identified in the mid-distal thigh at 47cm and extends for a length of ~6cm. LSV remains incompetent and leaves the fascia in the distal thigh at 40cm.</p>				
Assessed by	Jimmy Chen			
Printed on 07/12/2018 at 10:40 am			Checked by	



Incompetent branch leaves at the level of the knee at 32cm and tracks medially to communicate with the SSV. Distal to this, LSV remains incompetent and rejoins the fascia in the prox-mid calf at 25cm and is incompetent to the ankle.

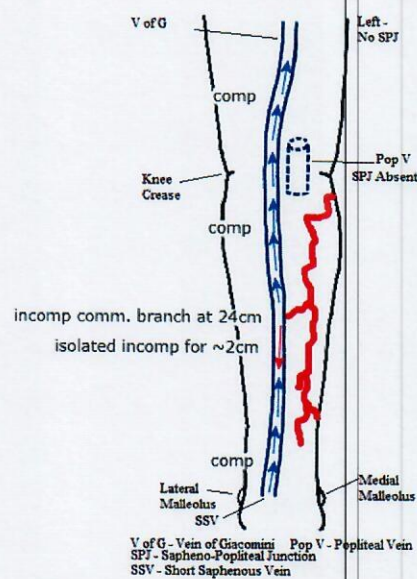
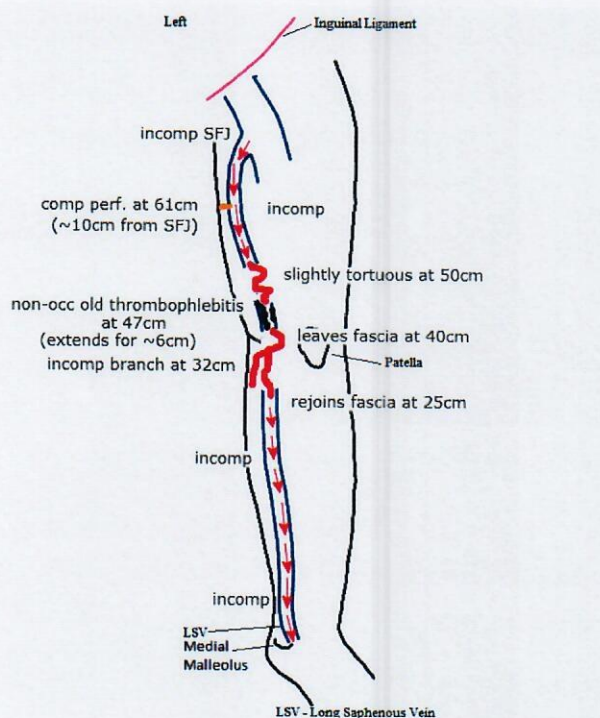
SPJ not identified. The prox SSV is patent and competent and is continuous with a competent vein of Giacomini. Incompetent branch communicates in the mid SSV at 24cm, distal to this, SSV becomes incompetent for a short section (~2cm) before becoming competent to the ankle.

Transverse (AP) dimensions of LSV:

Proximal thigh- 1.1cm,  
Mid thigh - 0.8cm,  
Distal thigh - 0.72cm.  
Proximal calf- 0.64cm,  
Mid calf - 0.56cm,  
Distal calf - 0.39cm.

Transverse (AP) dimensions of SSV:

Proximal calf- 0.27cm,  
Mid calf - 0.53cm,  
Distal calf - 0.22cm.



Assessed by Jimmy Chen

Printed on 07/12/2018 at 10:40 am

Checked by



Reason V - Foam sclerotherapy, Varicose vein

Outcome Incompetence

	Right		Left	
Deep Veins	Patency	Competency	Patency	Competency
Common Iliac Vein				
External Iliac Vein				
Internal Iliac Vein				
Common Femoral Vein	Widely Patent	Competent		
Profunda Vein	Widely Patent	Competent		
Superficial Femoral Vein	Widely Patent	Competent		
Popliteal Vein	Widely Patent	Incompetent		
Posterior Tibial Vein	Widely Patent	Competent		
Anterior Tibial Vein	Widely Patent	Competent		
Peroneal Vein	Widely Patent	Competent		
Soleal Vein	Patent			
Gastrocnemius	Patent			
<b>Superficial Veins</b>				
Saphenofemoral Junction	Not Identified			
L Saphenous Vein Above	Patent	Isolated Incompetence		
L Saphenous Vein Below	Patent	Incompetent		
Vein of Giacomini	Patent	Competent		
Saphenopopliteal Junction	Patent	Competent		
S Saphenous Vein	Patent	Competent		
<b>Evidence of D.V.T.</b>				
Above the knee	No			
Popliteal	No			
Below the knee	No			

**Notes****RIGHT LOWER LIMB VENOUS DUPLEX ASSESSMENT - PREVIOUS FOAM SCLEROTHERAPY**

Iliac veins not viewed. Flow in the common femoral vein is phasic with respiration and a normal response on Valsalva manoeuvre, suggesting proximal vein patency. All visualised deep veins, proximal to the popliteal vein, appear widely patent and competent with no evidence of previous DVT. The popliteal vein is incompetent, however no evidence of previous DVT detected. All deep calf veins appear widely patent and competent with no evidence of previous DVT.

All measurements are proximal to the medial malleolus unless otherwise stated.

SFJ not identified. Neo-vascularised tissue noted in the groin which appears to reform the LSV in the prox thigh at 66cm (~3cm from groin), and appears patent and incompetent tracking in a relatively linear fashion

Assessed by Jimmy Chen

Printed on 07/12/2018 at 10:41 am

Checked by

within the fascia in the prox-mid thigh. Incompetent branch in the prox thigh at 58cm, which tracks distally in the thigh. Distal to the branch, LSV remains incompetent. Incompetent branch noted in the distal thigh at 44cm, distal to this, LSV becomes competent and small calibre to the knee. LSV not identified at the level of the knee. Incompetent perforator reforms the LSV in the mid calf at 25cm and is incompetent with evidence of old superficial thrombophlebitis. Incompetent branch communicates at the distal calf at 10cm, LSV remains incompetent to the ankle.

Transverse (AP) dimensions of LSV:

Proximal thigh- 0.27cm,

Mid thigh - 0.27cm,

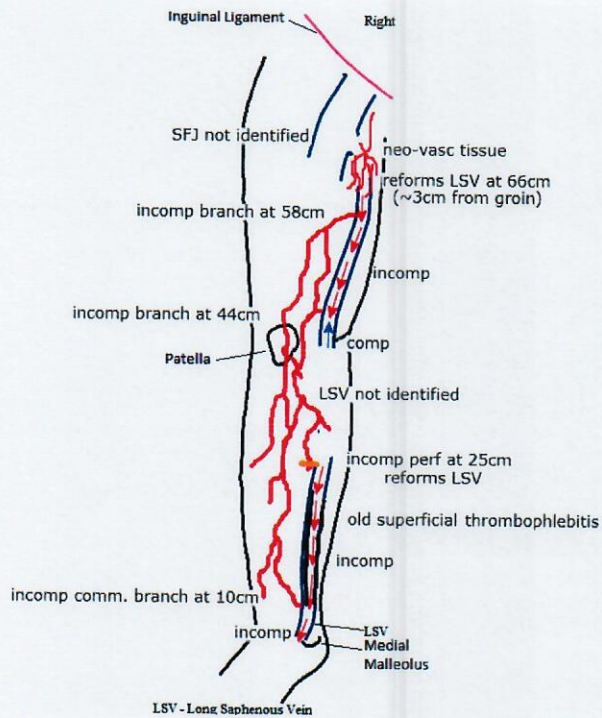
Distal thigh - 0.18cm.

Proximal calf- NI

Mid calf - 0.34cm,

Distal calf - 0.33cm.

SPJ is patent and competent. SSV is patent and competent and is continuous with a competent vein of Giacomini.



Assessed by Jimmy Chen

Printed on 07/12/2018 at 10:41 am

Checked by



**Reason** Varicose vein  
**Outcome** DVT negative, Incompetence

	<b>Right</b>		<b>Left</b>	
<b>Deep Veins</b>	<b>Patency</b>	<b>Competency</b>	<b>Patency</b>	<b>Competency</b>
Common Iliac Vein				
External Iliac Vein				
Internal Iliac Vein				
Common Femoral Vein	Widely Patent	Competent	Widely Patent	Competent
Profunda Vein	Widely Patent	Competent	Widely Patent	Competent
Superficial Femoral Vein	Widely Patent	Competent	Widely Patent	Competent
Popliteal Vein	Widely Patent	Slight Incompetence	Widely Patent	Competent
Posterior Tibial Vein	Widely Patent	Competent	Widely Patent	Competent
Anterior Tibial Vein	Widely Patent	Competent	Widely Patent	Competent
Peroneal Vein	Widely Patent	Competent	Widely Patent	Competent
Soleal Vein	Patent		Patent	
Gastrocnemius	Patent		Patent	
<b>Superficial Veins</b>				
Saphenofemoral Junction	Patent	Incompetent	Patent	Incompetent
L Saphenous Vein Above	Patent	Isolated Incompetence	Patent	Incompetent
L Saphenous Vein Below	Patent	Incompetent	Patent	Isolated Incompetence
Vein of Giacomini	Patent	Competent	Patent	Competent
Saphenopopliteal Junction	Not Identified		Not Identified	
S Saphenous Vein	Patent	Competent	Patent	Competent
<b>Evidence of D.V.T.</b>				
Above the knee	No		No	
Popliteal	No		No	
Below the knee	No		No	

## Notes

### BILATERAL LOWER LIMB VENOUS DUPLEX ASSESSMENT

Iliac veins not viewed bilaterally. Flow in the common femoral veins are phasic with respiration and a normal response on Valsalva manoeuvre, suggesting proximal vein patency.

All measurements are proximal to the medial malleolus unless otherwise stated.

#### RIGHT

All visualised deep veins, proximal to the popliteal vein appear widely patent and competent with no evidence of previous DVT.

Slight incompetence noted in the popliteal vein.

All other deep veins appear widely patent and competent with no evidence of previous DVT.

Assessed by Jimmy Chen

Printed on 07/12/2018 at 10:39 am

Checked by



SFJ is patent and incompetent. LSV is patent and incompetent proximally. Incompetent branch noted in the prox thigh at 67cm (~6cm from groin) and becomes tortuous and form large thigh and knee varicosities. Distal to this, LSV is competent and becomes incompetent in the mid-distal thigh at 45cm. Incompetent branch noted in the distal thigh at 44cm and communicate with thigh varicosities. Distal to the branch LSV remains incompetent to the knee. Incompetent branch leaves at the level of the knee and in the prox calf at 35cm and 28cm, respectively. Distal to thigh, LSV is incompetent to the ankle. Competent perforators noted in the mid calf at 23cm and 18cm. Incompetent perforator noted in the distal calf at 10cm giving rise to an incompetent branch that communicates with the LSV at the ankle.

SPJ not identified. SSV is patent and competent and is continuous with a competent vein of Giacomini.

Transverse (AP) dimensions of LSV:

Proximal thigh- 1.38cm,

Mid thigh - 0.5cm,

Distal thigh - 0.78cm.

Proximal calf- 0.7cm,

Mid calf - 0.72cm,

Distal calf - 0.94cm.

#### LEFT

All visualised deep veins appear widely patent and competent with no evidence of previous DVT.

?competent branch arises above the level of the SFJ ?pelvic origin.

SFJ is patent and incompetent. Anterior thigh vein (ATV) is patent, incompetent and becomes tortuous at 73cm (~2cm from groin). ATV leaves the fascia at 70cm and forms large anterior thigh varicosities.

LSV is patent and competent in the thigh. Small competent branch leaves at the level of the knee and becomes incompetent and varicosed in the mid calf.

Distal to this, LSV remains competent before becoming incompetent at the mid calf at 28cm, with an incompetent branch at 26cm. LSV remains incompetent to the ankle.

SPJ not identified. SSV is patent and competent and is continuous with a competent vein of Giacomini.

Transverse (AP) dimensions of LSV:

Proximal thigh- 0.47cm,

Mid thigh - 0.37cm,

Distal thigh - 0.38cm.

Proximal calf- 0.313cm,

Mid calf - 0.43cm,

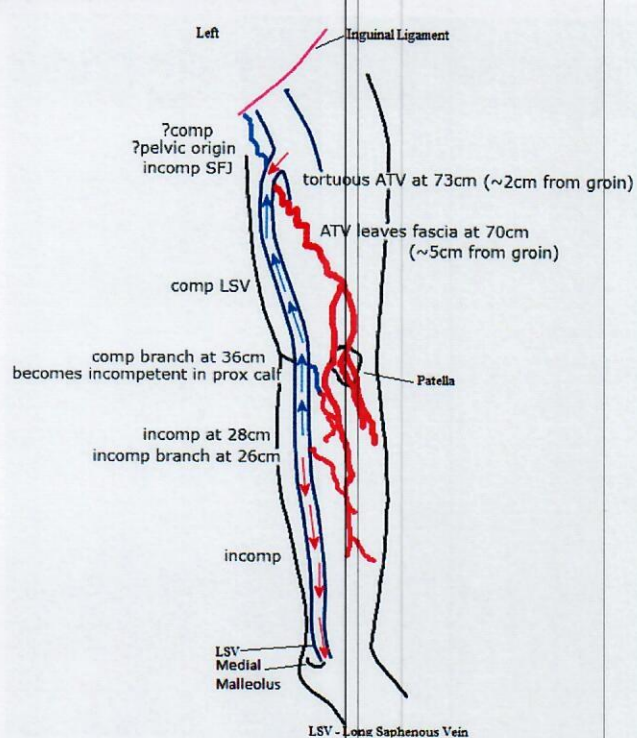
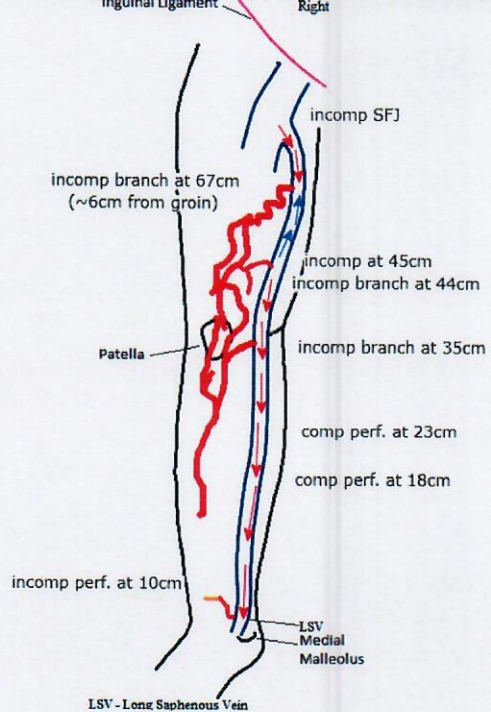
Distal calf - 0.37cm.

Assessed by Jimmy Chen

Printed on 07/12/2018 at 10:39 am

Checked by





Assessed by Jimmy Chen

Printed on 07/12/2018 at 10:39 am

Checked by

Reason

Varicose vein

Outcome

DVT negative, Incompetence

	Right		Left	
Deep Veins	Patency	Competency	Patency	Competency
Common Iliac Vein				
External Iliac Vein				
Internal Iliac Vein				
Common Femoral Vein	Widely Patent	Competent	Widely Patent	Competent
Profunda Vein	Widely Patent	Competent	Widely Patent	Competent
Superficial Femoral Vein	Widely Patent	Competent	Widely Patent	Competent
Popliteal Vein	Widely Patent	Competent	Widely Patent	Competent
Posterior Tibial Vein	Widely Patent	Competent	Widely Patent	Competent
Anterior Tibial Vein	Widely Patent	Competent	Widely Patent	Competent
Peroneal Vein	Widely Patent	Competent	Widely Patent	Competent
Soleal Vein	Patent		Patent	
Gastrocnemius	Patent		Patent	
<b>Superficial Veins</b>				
Saphenofemoral Junction	Patent	Competent	Patent	Competent
L Saphenous Vein Above	Patent	Competent	Patent	Competent
L Saphenous Vein Below	Patent	Competent	Patent	Isolated Incompetence
Vein of Giacomini	Patent	Competent	Not Identified	
Saphenopopliteal Junction	Patent	Competent	Patent	Competent
S Saphenous Vein	Patent	Competent	Patent	Competent
<b>Evidence of D.V.T.</b>				
Above the knee	No		No	
Popliteal	No		No	
Below the knee	No		No	

### Notes

#### BILATERAL LOWER LIMB VENOUS DUPLEX ASSESSMENT

Iliac veins not viewed bilaterally. Flow in the common femoral veins are phasic with respiration and a normal response on Valsalva manoeuvre, suggesting proximal vein patency bilaterally. All visualised deep veins appear widely patent and competent with no evidence of previous DVT bilaterally.

All measurements are proximal to the medial malleolus unless otherwise stated.

#### RIGHT

SFJ is patent and competent. LSV is patent and competent along its length.

SPJ is patent and competent. SSV is patent and competent and is continuous with a competent vein of Giacomini.

Assessed by Jimmy Chen

Printed on 07/12/2018 at 10:39 am

Checked by



LEFT

SFJ is patent and competent. LSV is patent and competent in the thigh. Incompetent medial branch leaves at the level of the knee at 40cm. Distal to this, calf LSV becomes incompetent. Incompetent branches leave in the prox-mid calf at 29cm. Incompetent branch communicates in the distal calf with an competent perforator at 14cm. Distal to this, LSV becomes competent and remains so to the ankle. Competent perforator noted in the mid calf at 26cm.

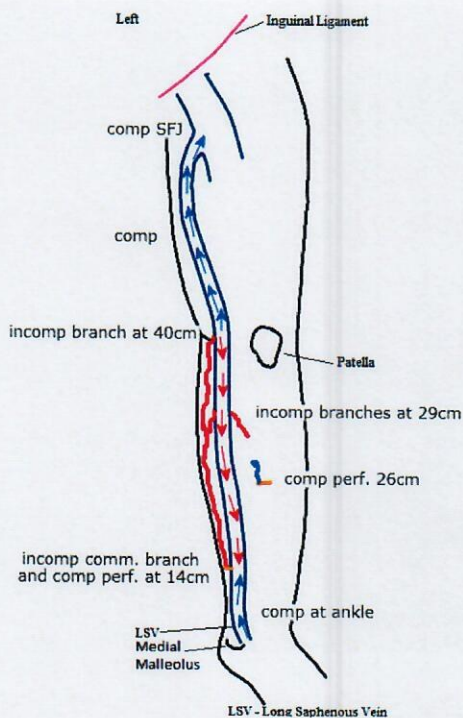
SPJ is patent and competent. SSV is patent and competent along its length.

Transverse (AP) dimensions of LSV:

Proximal calf- 0.33cm,

Mid calf - 0.2cm,

Distal calf - 0.32cm.



Assessed by Jimmy Chen

Printed on 07/12/2018 at 10:39 am

Checked by

Reason Varicose vein  
Outcome DVT negative, Incompetence

	Right		Left	
Deep Veins	Patency	Competency	Patency	Competency
Common Iliac Vein				
External Iliac Vein				
Internal Iliac Vein				
Common Femoral Vein	Widely Patent	Competent		
Profunda Vein	Widely Patent	Competent		
Superficial Femoral Vein	Widely Patent	Competent		
Popliteal Vein	Widely Patent	Competent		
Posterior Tibial Vein	Widely Patent	Competent		
Anterior Tibial Vein	Widely Patent	Competent		
Peroneal Vein	Widely Patent	Isolated Incompetence		
Soleal Vein	Widely Patent			
Gastrocnemius	Widely Patent			
Superficial Veins				
Saphenofemoral Junction	Widely Patent	Incompetent		
L Saphenous Vein Above	Widely Patent	Incompetent		
L Saphenous Vein Below	Widely Patent	Competent		
Vein of Giacomini	Widely Patent	Competent		
Saphenopopiteal Junction	Not Identified			
S Saphenous Vein	Widely Patent	Competent		
Evidence of D.V.T.				
Above the knee	No			
Popliteal	No			
Below the knee	No			

## Notes

RIGHT LOWER LIMB VENOUS DUPLEX ASSESSMENT - scanned in clinic

Iliac veins not viewed. Flow in the common femoral vein is phasic with respiration and a normal response on Valsalva manoeuvre, suggesting proximal vein patency. All visualised deep veins, proximal to and including the popliteal vein, appear widely patent and competent with no evidence of previous DVT. Isolated incompetent noted in 1x peroneal vein. All other deep calf veins appear widely patent and competent with no evidence of previous DVT.

All measurements are proximal to the medial malleolus unless otherwise stated.

?incompetent veins arise above the level of the SFJ ?pelvic source.

SFJ is patent and incompetent. LSV is patent, incompetent and tracks in a relatively linear fashion with a

Assessed by Jimmy Chen

Printed on 07/12/2018 at 10:36 am

Checked by



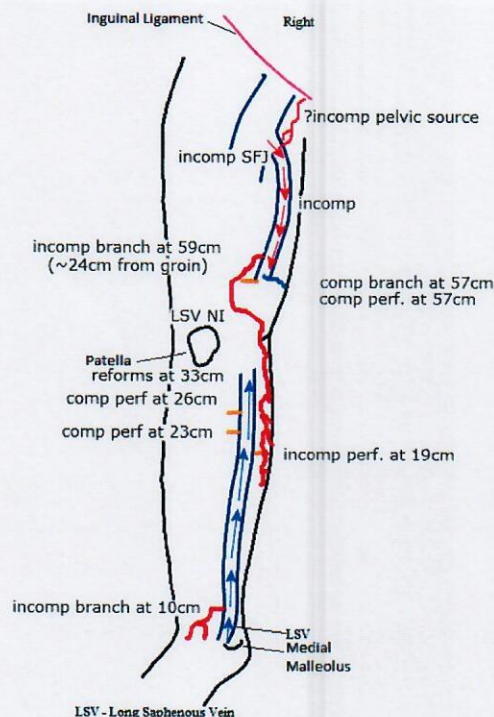
fascia in the prox-mid thigh. Incompetent branch leaves the mid thigh at 59cm (~24cm from the groin), and forms distal thigh and calf varicosities. Distal to this branch, LSV becomes competent before a competent branch leaves the mid thigh at 57cm, LSV immediately communicates with a competent perforator at this level and is not identified distal to this.

LSV reforms in the prox calf at 33cm and is competent. Competent perforators noted in the prox-mid calf at 26cm and 23cm. Further medial calf varicosities arise from an incompetent perforator in the mid calf at 19cm. LSV remains competent to the ankle with an incompetent branch at the distal calf at 10cm.

SPJ not identified. SSV is patent and competent and is continuous with a competent vein of Giacomini.

Transverse (AP) dimensions of LSV: Proximal thigh - 0.86cm, Mid-thigh - 0.26cm, Distal thigh NI

Transverse (AP) dimensions of LSV: Proximal calf - 0.15cm, Mid - calf - 0.28cm, Distal calf - 0.28 cm.



Assessed by Jimmy Chen

Printed on 07/12/2018 at 10:36 am

Checked by



Reason

varicose vein

Outcome

DVT negative, Incompetence

	Right		Left	
Deep Veins	Patency	Competency	Patency	Competency
Common Iliac Vein				
External Iliac Vein				
Internal Iliac Vein				
Common Femoral Vein	Widely Patent	Competent	Widely Patent	Competent
Profunda Vein	Widely Patent	Competent	Widely Patent	Competent
Superficial Femoral Vein	Widely Patent	Competent	Widely Patent	Incompetent
Popliteal Vein	Widely Patent	Competent	Widely Patent	Incompetent
Posterior Tibial Vein	Widely Patent	Competent	Widely Patent	Competent
Anterior Tibial Vein	Widely Patent	Competent	Widely Patent	Competent
Peroneal Vein	Widely Patent	Competent	Widely Patent	Competent
Soleal Vein	Widely Patent		Widely Patent	
Gastrocnemius	Widely Patent		Widely Patent	Competent
<b>Superficial Veins</b>				
Saphenofemoral Junction	Patent	Competent	Patent	
L Saphenous Vein Above	Not Identified		See notes	
L Saphenous Vein Below	Patent	Competent	Patent	Isolated Incompetence
Vein of Giacomini	Patent	Competent	Patent	Competent
Saphenopopliteal Junction				
S Saphenous Vein	Patent	Competent	Patent	Competent
<b>Evidence of D.V.T.</b>				
Above the knee	No		No	
Popliteal	No		No	
Below the knee	No		No	

## Notes

BILATERAL LOWER LIMB VENOUS DUPLEX ASSESSMENT - Scanned in clinic

All measurements are proximal to the medial malleolus unless otherwise stated.

## RIGHT

Iliac veins not viewed. Flow in the common femoral veins is phasic with respiration and a normal response on Valsalva manoeuvre, suggesting proximal vein patency bilaterally. All visualised deep veins appear widely patent and competent with no evidence of previous DVT.

SFJ is patent and competent. LSV not identified in the thigh. ATV is patent and incompetent in the prox-mid thigh and tracks in a relatively linear fashion before leaving the fascia in the mid thigh and becoming small calibre and competent. ATV becomes incompetent below the knee and forms anterior calf varicosities. LSV

Assessed by Jimmy Chen

Printed on 07/12/2018 at 10:38 am

Checked by



reforms at the level of the knee at 36cm and is incompetent. Incompetent branches in the prox calf at 33cm and 30cm respectively. Distal to this, LSV becomes competent and of small calibre to the ankle.

SPJ not identified. SSV is competent and is continuous with a competent vein of Giacomini.

Transverse (AP) dimensions of ATV:

Proximal thigh- 0.3cm,

Mid thigh - 0.29cm.

Transverse (AP) dimensions of LSV:

Proximal calf- 0.59cm,

Mid calf - 0.21cm,

Distal calf - 0.12cm.

#### LEFT

Iliac veins not viewed. Flow in the common femoral veins is phasic with respiration and a normal response on Valsalva manoeuvre, suggesting proximal vein patency bilaterally. The common femoral and profunda femoris veins appear widely patent and competent with no evidence of previous DVT. The Superficial femoral and popliteal veins appear patent and incompetent with no evidence of previous DVT identified. All deep calf veins appear widely patent and competent with no evidence of previous DVT.

SFJ is patent and competent. LSV is patent and competent in the prox thigh. LSV not identified from 66cm and reforms in the mid thigh at 57cm, and appear incompetent to the knee. LSV is incompetent in the prox calf with incompetent branches at 31cm and 27cm, respectively. Distal to this, LSV becomes competent and of small calibre to the ankle.

SPJ not identified. SSV is competent and is continuous with a competent vein of Giacomini.

Transverse (AP) dimensions of LSV:

Proximal thigh- 0.28cm,

Mid thigh - NI

Distal thigh - 0.48-0.58cm.

Proximal calf- 0.52cm,

Mid calf - 0.11cm,

Distal calf - 0.12cm.

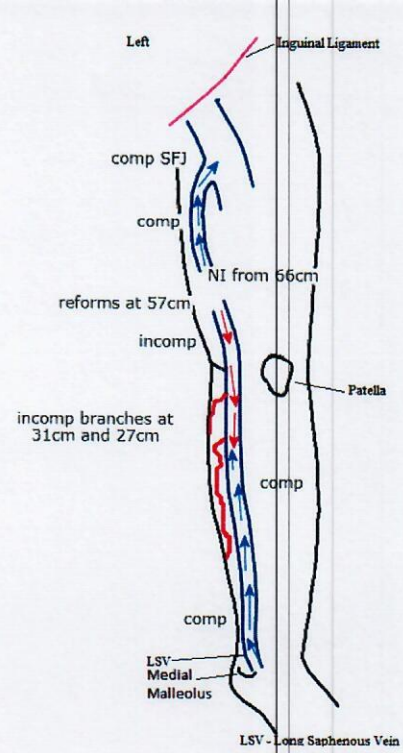
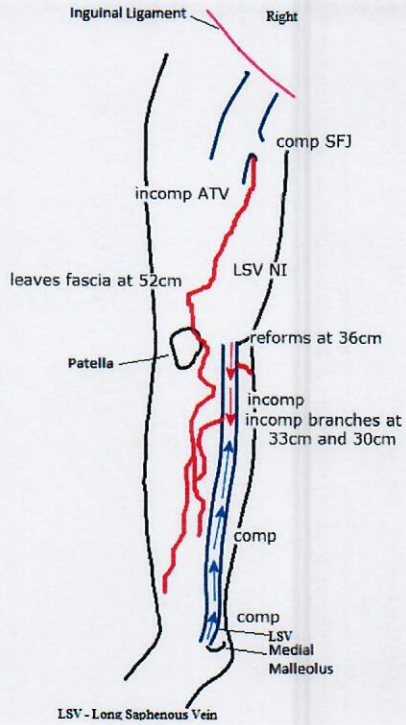
---

Assessed by Jimmy Chen

Printed on 07/12/2018 at 10:38 am

Checked by

---



Assessed by Jimmy Chen  
 Printed on 07/12/2018 at 10:38 am

Checked by



Reason Varicose vein  
Outcome DVT negative, Incompetence

	Right		Left	
Deep Veins	Patency	Competency	Patency	Competency
Common Iliac Vein				
External Iliac Vein				
Internal Iliac Vein				
Common Femoral Vein			Widely Patent	Competent
Profunda Vein			Widely Patent	Competent
Superficial Femoral Vein			Widely Patent	Competent
Popliteal Vein			Widely Patent	Competent
Posterior Tibial Vein			Widely Patent	Competent
Anterior Tibial Vein			Widely Patent	Competent
Peroneal Vein			Widely Patent	Competent
Soleal Vein			Patent	
Gastrocnemius			Patent	
Superficial Veins				
Saphenofemoral Junction			Patent	
L Saphenous Vein Above			Not Identified	
L Saphenous Vein Below			See notes	
Vein of Giacomini			Patent	Competent
Saphenopopiteal Junction			Not Identified	
S Saphenous Vein			Patent	Competent
Evidence of D.V.T.				
Above the knee			No	
Popliteal			No	
Below the knee			No	

## Notes

LEFT LOWER LIMB VENOUS DUPLEX ASSESSMENT - Scanned in clinic.

Iliac veins not viewed. Flow in the common femoral vein is phasic with respiration and a normal response on Valsalva manoeuvre, suggesting proximal vein patency. All visualised deep veins appear widely patent and competent with no evidence of previous DVT.

All measurements are proximal to the medial malleolus unless otherwise stated.

SFJ is patent and competent. Incompetent ATV arises at the level of the SFJ and leaves the fascia at ~5cm from the SFJ and is tortuous. ATV continues to form varicosities in the thigh and at the knee.

LSV reforms in the distal thigh at 49cm and appears competent for a short section before becoming incompetent below the level of the knee with evidence of old, recanalised superficial thrombophlebitis. LSV

Assessed by Jimmy Chen

Printed on 07/12/2018 at 10:34 am

Checked by

becomes slightly tortuous in the prox-mid calf at 30cm, with an incompetent branch in the mid calf at 25cm. Distal to this, LSV remains incompetent to the ankle.

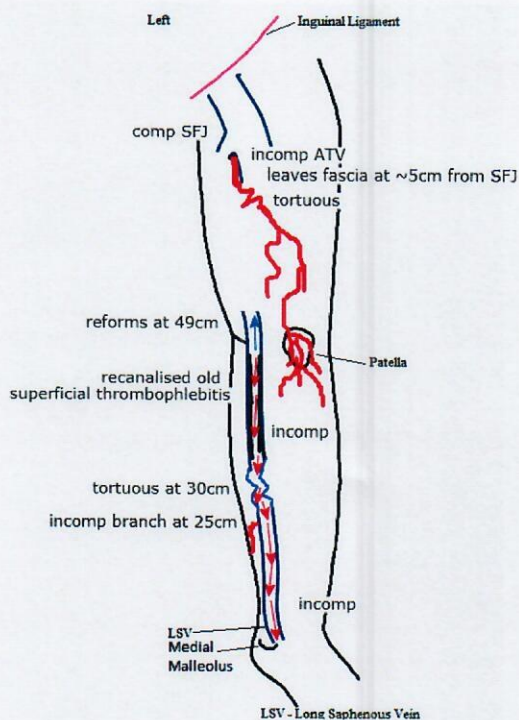
SPJ not identified. SSV is patent and competent and is continuous with a competent vein of Giacomini.

Transverse (AP) dimensions of LSV:

Proximal calf- 0.58cm,

Mid calf - 0.49cm,

Distal calf - 0.36cm.



Assessed by Jimmy Chen

Printed on 07/12/2018 at 10:34 am

Checked by



**Reason**

Varicose vein

**Outcome**

DVT positive - chronic, Occlusion, Superficial thrombophlebitis

	<b>Right</b>		<b>Left</b>	
<b>Deep Veins</b>	<b>Patency</b>	<b>Competency</b>	<b>Patency</b>	<b>Competency</b>
Common Iliac Vein				
External Iliac Vein				
Internal Iliac Vein				
Common Femoral Vein			Patent	Competent
Profunda Vein			Patent	Competent
Superficial Femoral Vein			Patent	Competent
Popliteal Vein			Recanalised	Old Thrombus
Posterior Tibial Vein			Areas of Thrombus	Old Thrombus
Anterior Tibial Vein			Patent	Competent
Peroneal Vein			Patent	Isolated Incompetence
Soleal Vein				
Gastrocnemius				
<b>Superficial Veins</b>				
Saphenofemoral Junction			Patent	Competent
L Saphenous Vein Above			See notes	
L Saphenous Vein Below			See notes	
Vein of Giacomini			Patent	Competent
Saphenopopliteal Junction			Not Identified	
S Saphenous Vein			Patent	Competent
<b>Evidence of D.V.T.</b>				
Above the knee			No	
Popliteal			Yes	Old
Below the knee			Yes	Old

**Notes****LEFT LOWER LIMB VENOUS DUPLEX ASSESSMENT**

Iliac veins not viewed. Flow in the common femoral vein is phasic with respiration and a normal response on Valsalva manoeuvre, suggesting proximal vein patency. All visualised deep veins, proximal to the popliteal vein, appear patent and competent with no evidence of previous DVT. Old, recanalised thrombus identified in the proximal popliteal vein and is incompetent. Mid-distal popliteal vein was not identified ?chronically occluded. Isolated, irregular and incompetent flow noted in the posterior tibial veins suggestive of old non-occlusive thrombus. Isolated incompetence noted in the mid peroneal veins. All other deep calf veins appear patent and competent with no evidence of previous DVT.

All measurements are proximal to the medial malleolus unless otherwise stated.

Assessed by Jimmy Chen

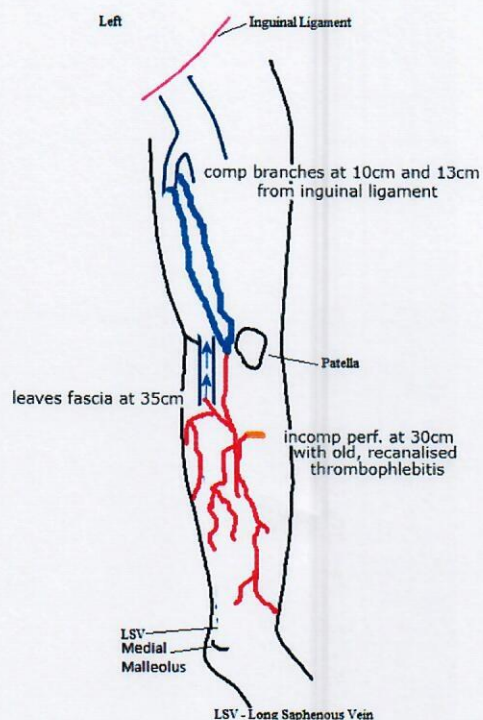
Printed on 07/12/2018 at 10:34 am

Checked by

SFJ is patent and competent. LSV is patent proximally with a competent branch leaving at ~10cm from the inguinal ligament. A further competent branch leaves at ~13cm from the inguinal ligament, distal to this, LSV was not identified in the thigh.

Calf LSV is competent proximally and leaves the fascia in the prox calf at 35cm and communicates with calf varicosities. Incompetent perforator identified in the prox calf at 30cm with evidence of recanalised old thrombophlebitis, and gives rise to anterior calf varicosities.

SPJ not identified. SSV is patent and competent and is continuous with a competent vein of Giacomini.



Assessed by Jimmy Chen

Printed on 07/12/2018 at 10:34 am

Checked by



**Reason** Ulceration, Varicose vein post-op  
**Outcome** DVT negative, Partial recanalised EVLT

Right		Left	
Deep Veins	Patency	Competency	Patency
Common Iliac Vein			
External Iliac Vein			
Internal Iliac Vein			
Common Femoral Vein			Patent
Profunda Vein			Patent
Superficial Femoral Vein			Patent
Popliteal Vein			Patent
Posterior Tibial Vein			Patent
Anterior Tibial Vein			Patent
Peroneal Vein			Patent
Soleal Vein			Patent
Gastrocnemius			Patent
Superficial Veins			
Saphenofemoral Junction			Patent
L Saphenous Vein Above			Occluded
L Saphenous Vein Below			Partially occluded
Vein of Giacomini			Not Identified
Saphenopopiteal Junction			Occluded
S Saphenous Vein			Occluded
Evidence of D.V.T.			
Above the knee			No
Popliteal			No
Below the knee			No

## Notes

### LEFT LOWER LIMB VENOUS DUPLEX ASSESSMENT - POST LSV AND SSV EVLA

Iliac veins not viewed. Flow in the common femoral vein is phasic with respiration and a normal response on Valsalva manoeuvre, suggesting proximal vein patency. All visualised deep veins appear patent and competent with no evidence of previous DVT.

All measurements are proximal to the medial malleolus unless otherwise stated.

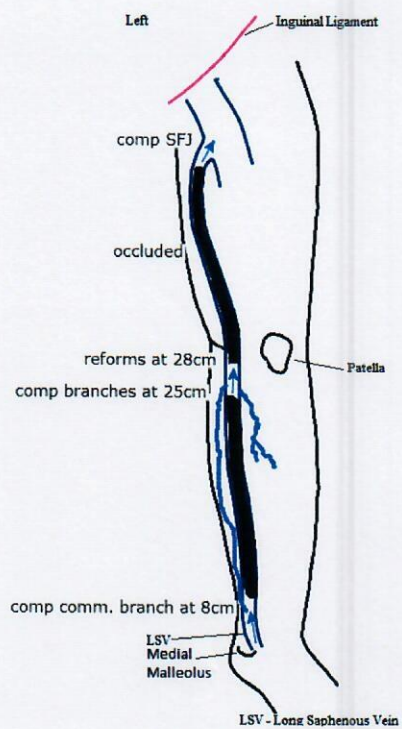
SFJ is patent and competent. LSV is occluded in the thigh. LSV reforms in prox calf at 28cm. Competent branches identified in the prox calf at 25cm. Distal to this, LSV is occluded before a competent branch communicates in the distal calf at 8cm. LSV is competent at the ankle.

Assessed by Jimmy Chen

Printed on 07/12/2018 at 10:35 am

Checked by

SPJ and SSV are occluded.



Assessed by Jimmy Chen  
Printed on 07/12/2018 at 10:35 am

Checked by



Reason Varicose vein  
Outcome DVT negative, Incompetence

	Right		Left	
Deep Veins	Patency	Competency	Patency	Competency
Common Iliac Vein				
External Iliac Vein				
Internal Iliac Vein				
Common Femoral Vein	Patent	Competent		
Profunda Vein	Patent	Competent		
Superficial Femoral Vein	Patent	Competent		
Popliteal Vein	Patent	Competent		
Posterior Tibial Vein	Patent	Competent		
Anterior Tibial Vein	Patent	Competent		
Peroneal Vein	Patent	Competent		
Soleal Vein				
Gastrocnemius				
Superficial Veins				
Saphenofemoral Junction	Patent	Competent		
L Saphenous Vein Above	Patent	Competent		
L Saphenous Vein Below	Patent	Isolated Incompetence		
Vein of Giacomini	Patent	Competent		
Saphenopopiteal Junction	Not Identified			
S Saphenous Vein	Patent	Competent		
Evidence of D.V.T.				
Above the knee	No			
Popliteal	No			
Below the knee	No			

### Notes

RIGHT LOWER LIMB VENOUS DUPLEX ASSESSMENT - Scanned in clinic.

Iliac veins not viewed. Flow in the common femoral vein is phasic with respiration and a normal response on Valsalva manoeuvre, suggesting proximal vein patency. All visualised deep veins appear patent and competent with no evidence of previous DVT.

All measurements are proximal to the medial malleolus unless otherwise stated.

SFJ is patent and competent. LSV is patent and competent in the thigh. Difficulty visualising LSV in the calf due to superficial oedema. LSV is patent and competent in the prox calf. LSV becomes incompetent in the mid calf at 27cm. Incompetent branch leaves the mid calf at 26cm, distal to this, LSV remains incompetent to the ankle.

Assessed by Jimmy Chen

Printed on 07/12/2018 at 10:09 am

Checked by

Checked by



**Reason** Ulceration  
**Outcome** DVT negative

	<b>Right</b>		<b>Left</b>	
<b>Deep Veins</b>	<b>Patency</b>	<b>Competency</b>	<b>Patency</b>	<b>Competency</b>
Common Iliac Vein				
External Iliac Vein				
Internal Iliac Vein				
Common Femoral Vein	Patent	Competent	Patent	Competent
Profunda Vein	Patent	Competent	Patent	Competent
Superficial Femoral Vein	Patent	Competent	Patent	Competent
Popliteal Vein	Patent	Competent	Patent	Competent
Posterior Tibial Vein	Patent	Competent	See notes	
Anterior Tibial Vein	Patent	Competent	Patent	Competent
Peroneal Vein	Patent	Competent	See notes	
Soleal Vein	Patent			
Gastrocnemius	Patent			
<b>Superficial Veins</b>				
Saphenofemoral Junction	Patent	Incompetent	Patent	Competent
L Saphenous Vein Above	Patent	Incompetent	Patent	Competent
L Saphenous Vein Below	Patent	Incompetent	Patent	Competent
Vein of Giacomini	Patent	Competent	Patent	Competent
Saphenopopiteal Junction	Patent	Competent	Patent	Competent
S Saphenous Vein	Patent	Competent	Patent	Incompetent
<b>Evidence of D.V.T.</b>				
Above the knee	No		No	
Popliteal	No		No	
Below the knee	No		No	

## Notes

BILATERAL LOWER LIMB VENOUS DUPLEX ASSESSMENT - Scanned in clinic.

\*limited scan due to patient habitus, poor mobility, patient discomfort and overlying calcified arteries.

## RIGHT

Iliac veins not viewed. Flow in the common femoral vein is phasic with respiration and a normal response on Valsalva manoeuvre, suggesting proximal vein patency. All visualised deep veins appear patent and competent with no evidence of previous DVT.

All measurements are proximal to the medial malleolus unless otherwise stated.

SFJ is patent and incompetent. Difficulty assessed LSV in the thigh due to poor access and poor patient mobility and discomfort. Where seen, LSV is patent and incompetent in the thigh. Incompetent branch

Assessed by Jimmy Chen

Printed on 07/12/2018 at 10:10 am

Checked by



leaves the prox calf at 31cm and forms calf varcosities. Distal to this, LSV becomes competent and remains so to the ankle.

SPJ is patent and competent. SSV is patent and competent and is continuous with a competent vein of Giacomini.

Transverse (AP) dimensions of LSV: Proximal thigh - 0.82cm, Mid- thigh - 0.63cm, Distal thigh - 0.73cm.  
Transverse (AP) dimensions of LSV: Proximal calf - 0.61cm, Mid - calf - 0.35cm, Distal calf - 0.27cm.

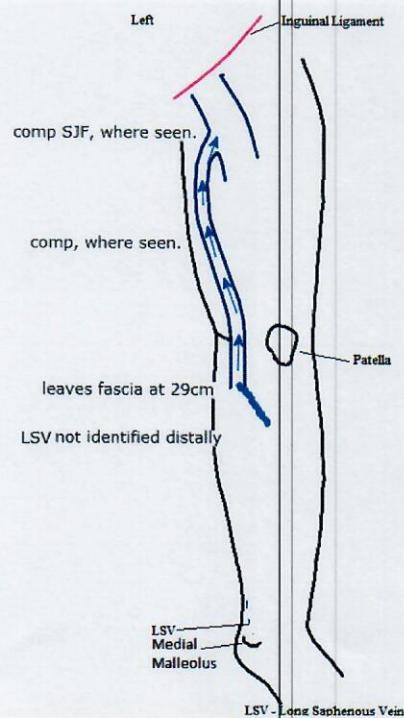
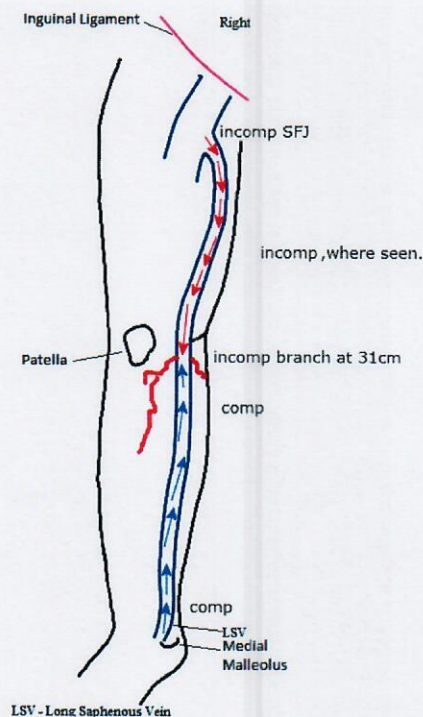
## LEFT

Iliac veins not viewed. Flow in the common femoral vein is phasic with respiration and a normal response on Valsalva manoeuvre, suggesting proximal vein patency. All visualised deep veins, proximal to and including the popliteal vein, appear patent and competent with no evidence of previous DVT. Anterior tibial veins appear patent and competent. Unable to assess the complete length of the posterior tibial and peroneal veins due to superficial oedema and calcified crural vessels - unable to exclude acute or chronic DVT from these images.

Where seen, SFJ is patent and competent. LSV is patent and competent in the thigh. LSV leaves the fascia in the prox calf at 29cm is not identified distal to this due to superficial oedema.

SPJ is patent and competent where seen. SSV is patent and incompetent along its length. Vein of Giacomini is patent and competent.

Transverse (AP) dimensions of SSV: Proximal calf - 0.58cm, Mid - calf - 0.43cm, Distal calf - 0.49cm.

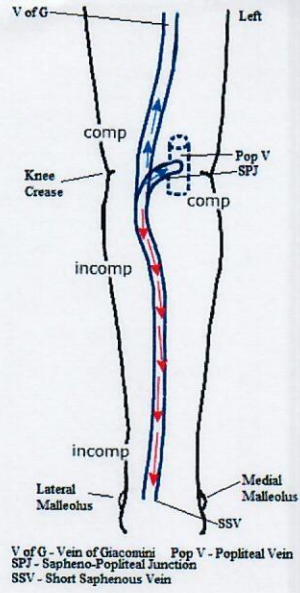


Assessed by Jimmy Chen

Printed on 07/12/2018 at 10:10 am

Checked by





Assessed by Jimmy Chen  
 Printed on 07/12/2018 at 10:10 am

Checked by

Reason Varicose vein  
Outcome Incompetence

	Right		Left	
Deep Veins	Patency	Competency	Patency	Competency
Common Iliac Vein				
External Iliac Vein				
Internal Iliac Vein				
Common Femoral Vein			Recanalised	Old Thrombus
Profunda Vein			Patent	Competent
Superficial Femoral Vein			Patent	Competent
Popliteal Vein			Patent	Competent
Posterior Tibial Vein			Patent	Competent
Anterior Tibial Vein			Patent	Competent
Peroneal Vein			Patent	Competent
Soleal Vein			Patent	
Gastrocnemius			Patent	
Superficial Veins				
Saphenofemoral Junction			Patent	
L Saphenous Vein Above			Not Identified	
L Saphenous Vein Below			Patent	Incompetent
Vein of Giacomini			Patent	Competent
Saphenopopliteal Junction			Patent	Competent
S Saphenous Vein			Patent	Competent
Evidence of D.V.T.				
Above the knee			Yes	Old
Popliteal			No	
Below the knee			No	

## Notes

### LEFT LOWER LIMB VENOUS DUPLEX ASSESSMENT

Iliac veins not viewed. Flow in the common femoral vein is phasic with respiration and a normal response on Valsalva manoeuvre, suggesting proximal vein patency. Old, recanalised thrombus identified in the common femoral vein, however no evidence of acute DVT detected. All other visualised deep veins appear patent and competent with no evidence of previous DVT.

SFJ is patent. LSV not identified in the thigh ?due to previous vv surgery.

LSV reforms in the prox calf distal to the knee crease ?via small tortuous branches that track proximally to the groin. LSV is incompetent and linear in the calf with a competent branch communicating in the mid calf at ~18cm. Perforators identified in the calf appear competent.

Assessed by Jimmy Chen

Printed on 07/12/2018 at 10:16 am

Checked by



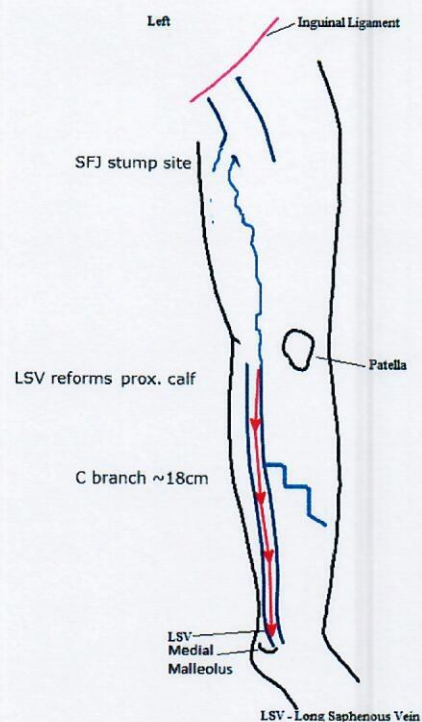
Transverse (AP) dimensions of LSV in the calf:

Proximal calf- 0.33cm,

Mid calf - 0.35cm,

Distal calf - 0.41cm.

SPJ is patent and competent. SSV is competent and is continuous with a competent vein of Giacomini.



Assessed by Jimmy Chen

Printed on 07/12/2018 at 10:16 am

Checked by

Reason Ulceration  
Outcome DVT negative

	Right		Left	
Deep Veins	Patency	Competency	Patency	Competency
Common Iliac Vein				
External Iliac Vein				
Internal Iliac Vein				
Common Femoral Vein	Patent	Competent	Patent	Competent
Profunda Vein	Patent	Competent	Patent	Competent
Superficial Femoral Vein	Patent	Competent	Patent	Competent
Popliteal Vein	Patent	Competent	Patent	Competent
Posterior Tibial Vein	Patent	Competent	See notes	
Anterior Tibial Vein	Patent	Competent	Patent	Competent
Peroneal Vein	Patent	Competent	See notes	
Soleal Vein	Patent			
Gastrocnemius	Patent			
Superficial Veins				
Saphenofemoral Junction	Patent	Incompetent	Patent	Competent
L Saphenous Vein Above	Patent	Incompetent	Patent	Competent
L Saphenous Vein Below	Patent	Incompetent	Patent	Competent
Vein of Giacomini	Patent	Competent	Patent	Competent
Saphenopopliteal Junction	Patent	Competent	Patent	Competent
S Saphenous Vein	Patent	Competent	Patent	Incompetent
Evidence of D.V.T.				
Above the knee	No		No	
Popliteal	No		No	
Below the knee	No		No	

## Notes

BILATERAL LOWER LIMB VENOUS DUPLEX ASSESSMENT - Scanned in clinic.

\*limited scan due to patient habitus, poor mobility, patient discomfort and overlying calcified arteries.

## RIGHT

Iliac veins not viewed. Flow in the common femoral vein is phasic with respiration and a normal response on Valsalva manoeuvre, suggesting proximal vein patency. All visualised deep veins appear patent and competent with no evidence of previous DVT.

All measurements are proximal to the medial malleolus unless otherwise stated.

SFJ is patent and incompetent. Difficulty assessed LSV in the thigh due to poor access and poor patient mobility and discomfort. Where seen, LSV is patent and incompetent in the thigh. Incompetent branch

Assessed by Jimmy Chen

Printed on 07/12/2018 at 10:30 am

Checked by



leaves the prox calf at 31cm and forms calf varicosities. Distal to this, LSV becomes competent and remains so to the ankle.

SPJ is patent and competent. SSV is patent and competent and is continuous with a competent vein of Giacomini.

Transverse (AP) dimensions of LSV: Proximal thigh - 0.82cm, Mid- thigh - 0.63cm, Distal thigh - 0.73cm.  
Transverse (AP) dimensions of LSV: Proximal calf - 0.61cm, Mid - calf - 0.35cm, Distal calf - 0.27cm.

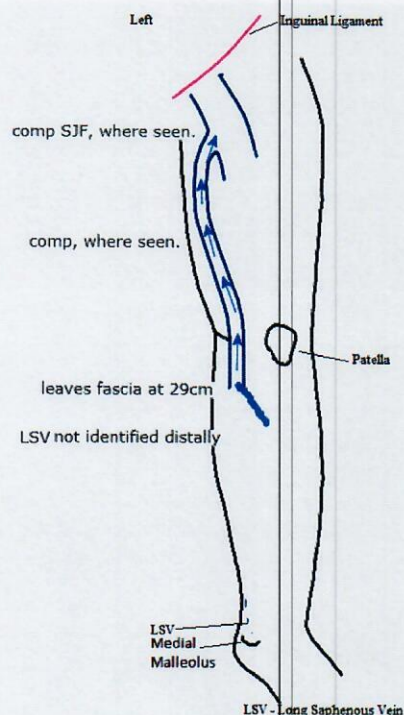
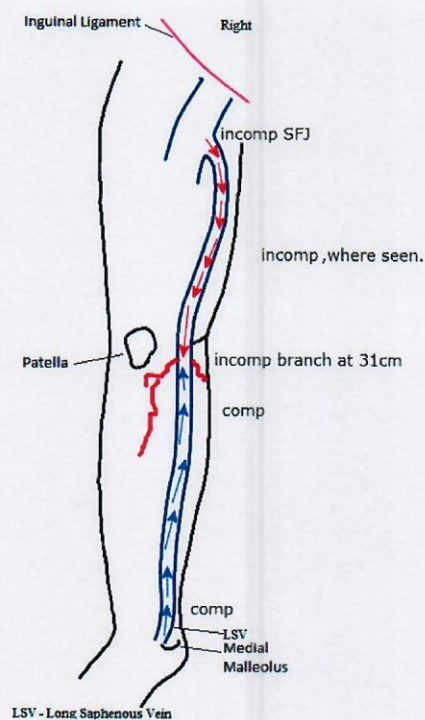
#### LEFT

Iliac veins not viewed. Flow in the common femoral vein is phasic with respiration and a normal response on Valsalva manoeuvre, suggesting proximal vein patency. All visualised deep veins, proximal to and including the popliteal vein, appear patent and competent with no evidence of previous DVT. Anterior tibial veins appear patent and competent. Unable to assess the complete length of the posterior tibial and peroneal veins due to superficial oedema and calcified crural vessels - unable to exclude acute or chronic DVT from these images.

Where seen, SFJ is patent and competent. LSV is patent and competent in the thigh. LSV leaves the fascia in the prox calf at 29cm is not identified distal to this due to superficial oedema.

SPJ is patent and competent where seen. SSV is patent and incompetent along its length. Vein of Giacomini is patent and competent.

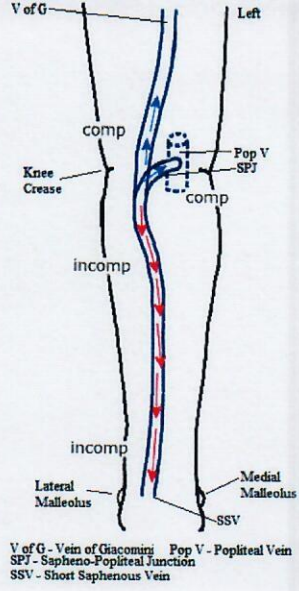
Transverse (AP) dimensions of SSV: Proximal calf - 0.58cm, Mid - calf - 0.43cm, Distal calf - 0.49cm.



Assessed by Jimmy Chen

Printed on 07/12/2018 at 10:30 am

Checked by



Assessed by Jimmy Chen  
 Printed on 07/12/2018 at 10:30 am

Checked by