

Reason	Pseudoaneurysm
Outcome	Pseudoaneurysm negative

Notes

DUPLEX ASSESSMENT OF RIGHT GROIN POSSIBLE PSEUDOANEURYSM

The right distal external iliac (EIA), common femoral (CFA), profunda femoral (PFA), and proximal superficial femoral arteries (SFA) appear patent with monophasic waveforms and PSV 124cm/s, 94cm/s, 65cm/s and 65cm/s, respectively.

No evidence of patent pseudoaneurysm identified in the groin at this time, however monophasic waveforms obtained in the distal EIA, CFA, PFA and SFA - suggestive of significant arterial disease.

SUGGEST VASCULAR SURGICAL OPINION, IF FELT APPROPRIATE.

Assessed by Jimmy Chen


Printed on 07/12/2018 at 9:44 am

Checked by

Reason Routine
Outcome Widely patent

Right

Left




Good

Brachial

130

1.00



Good

Radial

Ulnar

Post Exercise

Notes

RIGHT UPPER LIMB ARTERIAL DUPLEX ASSESSMENT

Common carotid artery - patent, PSV 90cm/s.

Subclavian artery - patent along length with tri/bouncy monophasic waveforms, PSV 101-102-94cm/s.

Axillary artery - patent with good bouncy monophasic waveforms, PSV 69cm/s.

Brachial/radial/ulnar arteries - patent with good bouncy monophasic waveforms, PSV 69cm/s, 64cm/s and 60cm/s, respectively.

The right and left vertebral arteries appear open and orthograde.

CONCLUSION - No evidence of significant disease/Subclavian Steal Syndrome identified from this scan.

Assessed by Jimmy Chen

Printed on 07/12/2018 at 9:46 am


Checked by

Reason Graft vein fem-pop
Outcome Widely patent, Calcified

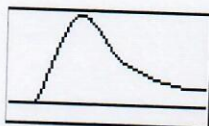
Right

150


1.00



Good




Slightly Reduced



Reduced

130

0.87



Reduced

Brachial

Common Femoral

High Thigh

Low Thigh

Popliteal

High Calf

Peroneal

Anterior Tibial

Posterior Tibial

Dorsalis Pedis

Toe Pressure

Post Exercise

Left

Notes

RIGHT LOWER LIMB ARTERIAL DUPLEX ASSESSMENT - PREVIOUS FEM-POP VEIN GRAFT. Scanned in clinic.

CFA - patent and calcified, biphasic waveforms, PSV 98cm/s.

Proximal anastomosis - patent and slightly obscured. Where seen, elevated velocities obtained, monophasic waveforms, PSV 334cm/s ?increased velocities due to vessel calibre change.
Graft body - patent along length with monophasic waveforms, PSV 160-155-119cm/s.

Assessed by Jimmy Chen

Printed on 07/12/2018 at 9:49 am

Checked by

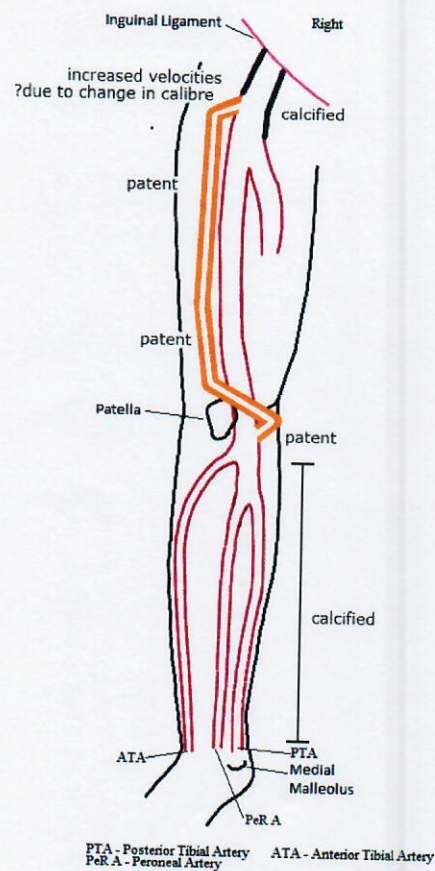
Distal anastomosis - patent with monophasic waveforms, PSV 209cm/s.

PopA - patent with monophasic waveforms, PSV 49cm/s.

ATA and PTA - patent and heavily calcified, monophasic waveforms, PSV 48cm/s and 79cm/s, respectively.

Resting ABPI is within normal limits in the right.

Unable to obtain ABPI in the left due to poor signal strength.



Assessed by Jimmy Chen

Printed on 07/12/2018 at 9:49 am

Checked by

Reason Graft vein fem-pop
Outcome Occlusion, Calcified, Poor images

Right

180

1.00

Brachial

Common Femoral

Good

High Thigh

Low Thigh

Popliteal

Absent

High Calf

Peroneal

Anterior Tibial

Weak

220

1.22

120

0.67

Posterior Tibial




Weak

Dorsalis Pedis

Toe Pressure

Post Exercise

Left



Notes

LEFT LOWER LIMB ARTERIAL DUPLEX ASSESSMENT - PREVIOUS FEM-POP BYPASS
Scanned in clinic.

CFA - patent and calcified, triphasic waveforms, PSV 97cm/s.

Proximal anastomosis - occluded.

Graft body - occluded.

Distal anastomosis - occluded.

Assessed by Jimmy Chen

Printed on 07/12/2018 at 9:51 am

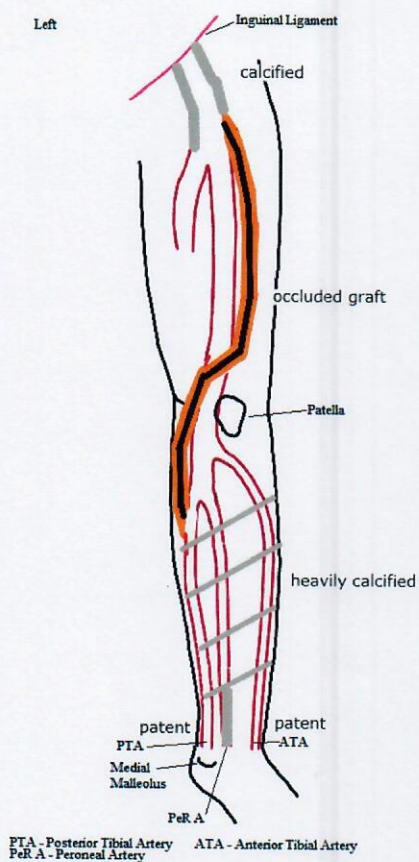
Checked by

PopA - occluded.

ATA and PTA - heavily calcified, however patent at the ankle with weak monophasic waveforms, PSV 27cm/s and 26cm/s respectively.

Resting right ABPI is falsely elevated due to calcification.

Resting left ABPI is reduced.



Assessed by Jimmy Chen

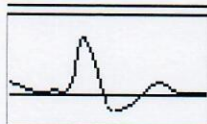
Printed on 07/12/2018 at 9:51 am

Checked by

Reason Graft vein
Outcome Widely patent

Right

Left



Good

Brachial

Common Femoral

High Thigh

Low Thigh

Popliteal

High Calf

Peroneal

Anterior Tibial

Posterior Tibial

Dorsalis Pedis

Toe Pressure

Post Exercise

Notes

RIGHT LOWER LIMB ARTERIAL DUPLEX SCAN (Right Ileo-femoral CIA->CFA vein graft using SFV; and CIA>IIA jump graft)

Aorta – Patent with good triphasic flow, PSV 110cm/s. Vessel appears to be of normal and uniform calibre - maximally measuring 1.43cm (TS plane; outer-to-outer wall)

CIA – proximal vessel is aneurysmal with biphasic waveforms, PSV 183cm/s. Vessel measures 1.71cm (maximum AP TS plane measurements).

Assessed by Jimmy Chen

Printed on 07/12/2018 at 9:53 am

Checked by

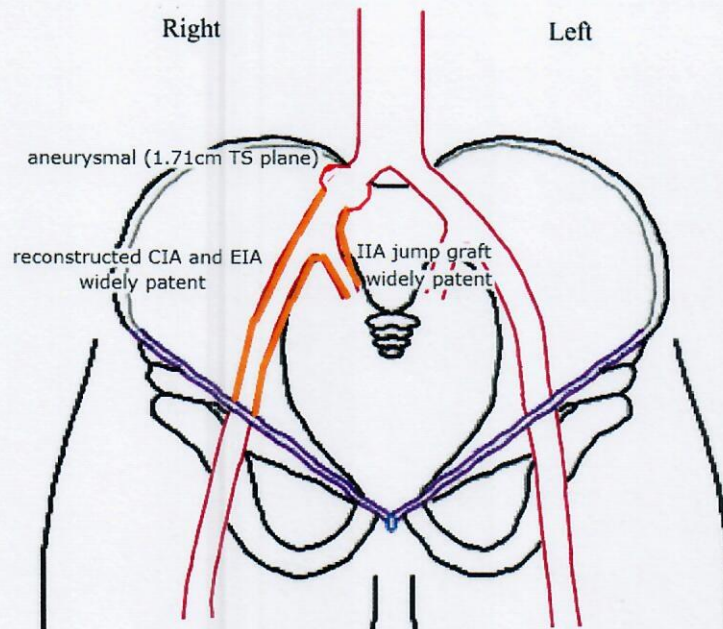
Distal vessel (previous CIA reconstruction) appears widely patent with biphasic waveforms, PSV 60cm/s.

IIA Graft - proximal anastomosis is widely patent with triphasic waveforms, PSV 68cm/s. Prox-distal graft appears patent with triphasic waveforms, PSV 78-67cm/s. Distal anastomosis was not visualised due to vessel depth.

CIA>CFA Graft - widely patent along its length with bi/triphasic waveforms, PSV 60-54-69cm/s.
Distal anastomosis - widely patent with triphasic waveforms, PSV 54cm/s.

CFA – patent with good triphasic flow, PSV 82cm/s.

PLEASE HIGHLIGHT TO MR NICHOLAS TO ARRANGE FOLLOW-UP SURVEILLANCE SCAN.



Assessed by Jimmy Chen

Printed on 07/12/2018 at 9:53 am

Checked by

Reason Ulceration
Outcome Obscured, Stenosis Mild, Calcified

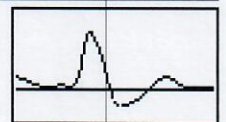
Right

140 1.00

Brachial

Common Femoral

Good

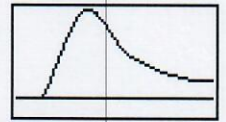


High Thigh

Low Thigh

Popliteal

Slightly Reduced



High Calf

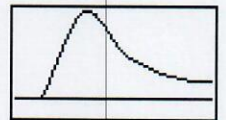
Peroneal

Anterior Tibial

Slightly Reduced

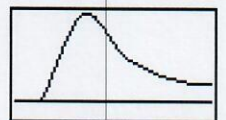
130 0.93

110 0.79



Posterior Tibial

Slightly Reduced



Dorsalis Pedis

Toe Pressure

Post Exercise

Notes

LEFT LOWER LIMB ARTERIAL DUPLEX ASSESSMENT - Scanned in clinic.

Difficulty visualising the abdominal aorta due to overlying bowel gas, where seen, the abdominal aorta is patent and appears of normal calibre (maximum AP TS plane= 1.95cm), with no evidence of focal dilatation or aneurysm identified.

CIA - obscured due to overlying bowel gas.

EIA - prox-mid is obscured due to overlying bowel gas. Distal vessel is patent with triphasic waveforms, PSV 150cm/s.

Assessed by Jimmy Chen

Printed on 07/12/2018 at 9:55 am

Checked by

CFA - patent with triphasic waveforms, PSV 193cm/s.

PFA (origin) - patent with biphasic waveforms, PSV 94cm/s.

SFA - patent in the prox-mid vessel with mild dense disease, triphasic waveforms, PSV 150-152cm/s. Mild stenosis (extending for ~2.58cm) noted in the mid vessel with no elevated velocities noted. Distal vessel is calcified with monophasic waveforms, PSV 127cm/s.

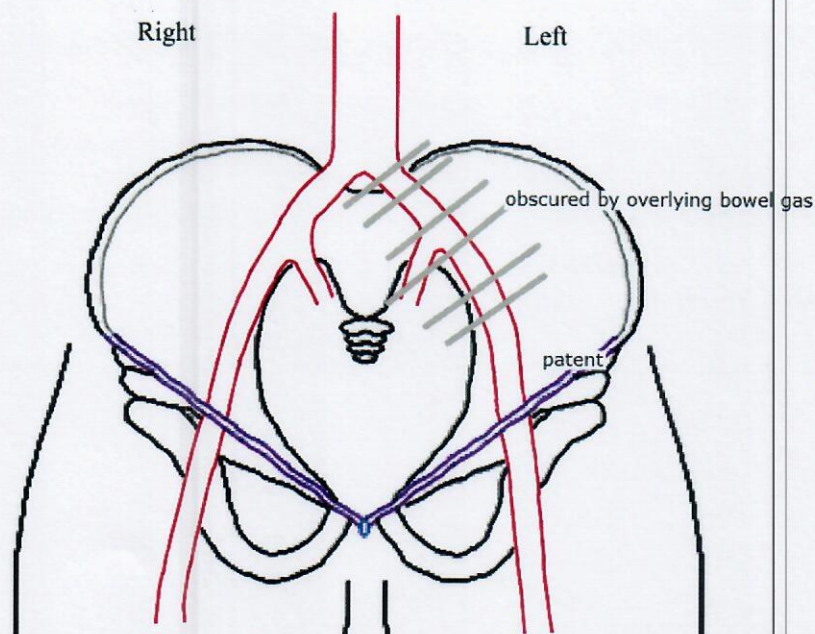
PopA - patent and calcified with monophasic waveforms, PSV 107-73cm/s.

TPT - calcified with evidence of at least 2x vessel run off identified.

ATA and PTA - patent and calcified, monophasic waveforms, PSV 45cm/s and 78cm/s, respectively.

PerA - no flow identified ?calcified.

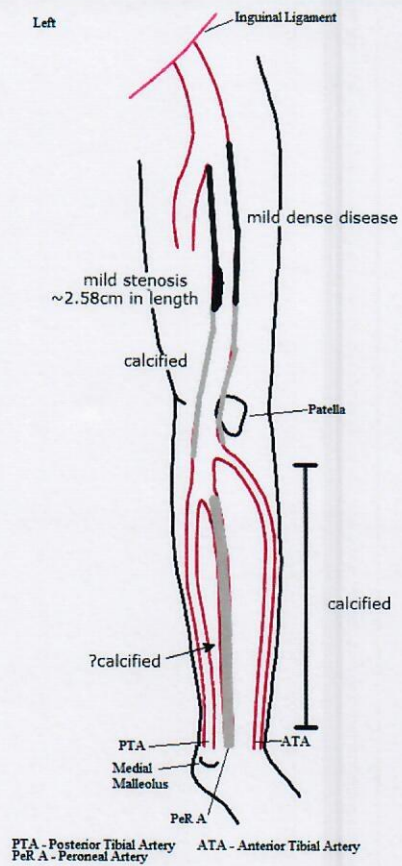
Resting ABPI is within normal limits in the right and reduced in the left.



Assessed by Jimmy Chen

Printed on 07/12/2018 at 9:55 am

Checked by



Assessed by Jimmy Chen
Printed on 07/12/2018 at 9:55 am

Checked by

Reason	Claudication
Outcome	Stenosis Severe, Calcified

Right

115

1.00

Brachial**Common Femoral**

Good

High Thigh**Low Thigh****Popliteal**

Reduced

High Calf**Peroneal****Anterior Tibial**




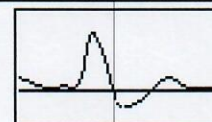
Reduced

Posterior Tibial

Reduced

90

0.78

Dorsalis Pedis**Toe Pressure****Post Exercise****Left****Notes****LEFT LOWER LIMB ARTERIAL DUPLEX ASSESSMENT**

Abdominal aorta is patent with good triphasic waveforms and PSV 65cm/s. The abdominal aorta appears of normal calibre (maximum AP TS plane = 1.94cm), with no evidence of focal dilatation or aneurysm identified.

CIA - patent with mild dense disease, bi/triphasic waveforms, PSV 105cm/s.

EIA - patent with mild dense disease, biphasic waveforms, PSV 77cm/s.

Assessed by Jimmy Chen

Printed on 07/12/2018 at 9:57 am

Checked by

CFA - patent with triphasic waveforms, PSV 122cm/s.

PFA - patent with triphasic waveforms, PSV 94cm/s.

SFA - patent with mild dense disease in the prox-mid vessel with triphasic waveforms, PSV 50-45cm/s.

Severe focal stenosis identified in the mid thigh at 61cm, with velocities increasing from PSV 45cm/s to PSV 484cm/s. Stenosis extends for a length of 4cm. Distal to the stenosis, vessel remains patent with mild calcified disease, monophasic waveforms, PSV 31cm/s.

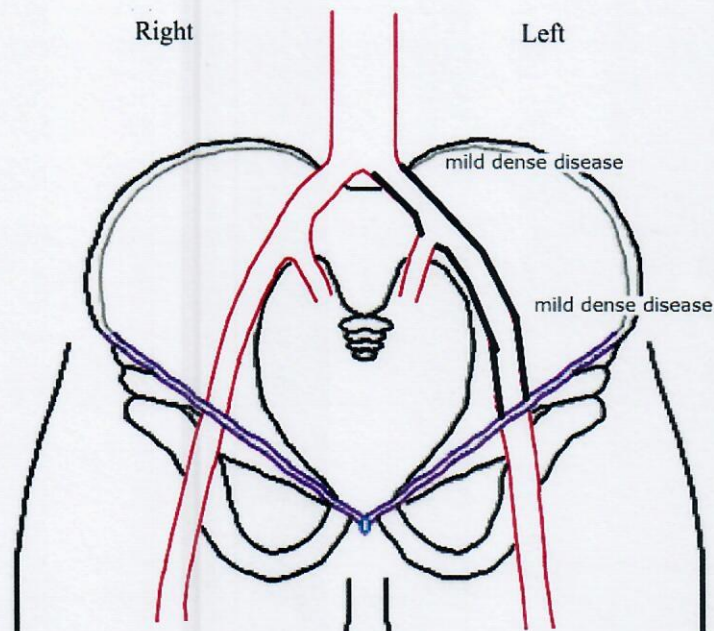
PopA - patent with mild dense and calcified disease, monophasic waveforms, PSV 31-37cm/s.

TPT - patent and calcified with evidence of at least 2x vessel run off identified.

ATA and PTA - calcified, however patent at the ankle with monophasic waveforms, PSV 23cm/s and 36cm/s respectively.

PerA - no flow identified ?calcified ?patency.

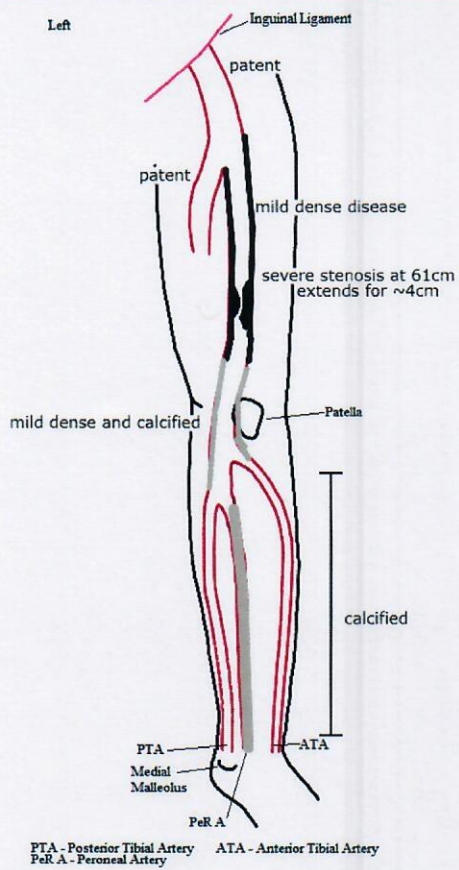
Resting ABPI is within normal limits in the right and reduced in the left lower limb.



Assessed by Jimmy Chen

Printed on 07/12/2018 at 9:57 am

Checked by



Assessed by Jimmy Chen

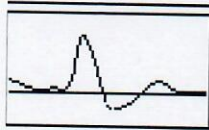
Printed on 07/12/2018 at 9:57 am

Checked by

Reason Angioplasty
Outcome disease mild, Obscured, Poor images, Calcified

Right


Left



Good

Brachial

Common Femoral




Slightly Reduced

High Thigh

Low Thigh

Popliteal

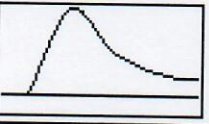


Slightly Reduced

High Calf

Peroneal

Anterior Tibial



Slightly Reduced

Posterior Tibial

Dorsalis Pedis

Toe Pressure

Post Exercise

Notes

RIGHT LOWER LIMB ARTERIAL DUPLEX ASSESSMENT - PREVIOUS SFA AND POPA ANGIOPLASTY
 *patient scanned in chair.

Unable to adequately visualise the abdominal aorta and common iliac artery due to patient positioning and overlying bowel gas.

EIA - patent where seen, with tri/biphasic waveforms, PSV 77-67cm/s.

Assessed by Jimmy Chen

Printed on 07/12/2018 at 9:59 am

Checked by

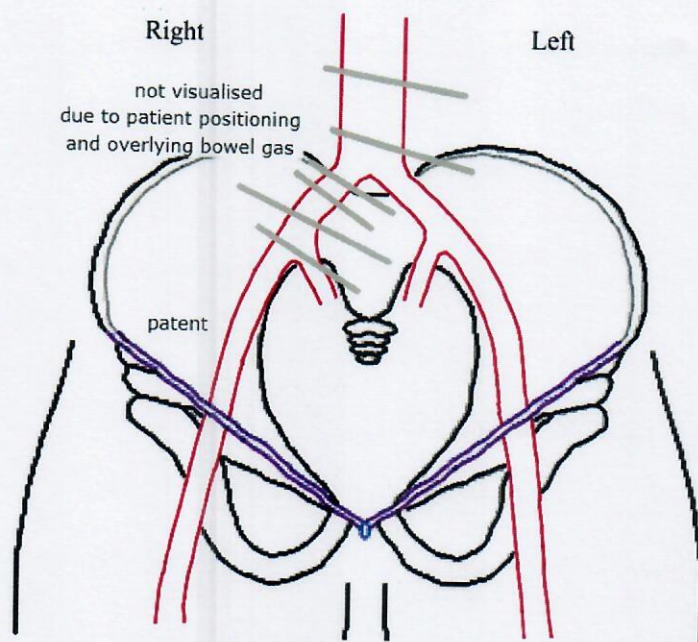
CFA - patent with mild dense and calcified disease, triphasic waveforms, PSV 48cm/s.
PFA (origin) - patent with mild dense and calcified disease, triphasic waveforms, PSV 90cm/s.
SFA - patent with mild diffuse dense and calcified disease along length, triphasic waveforms, PSV 84-45-38cm/s.

PopA - patent and calcified, mono/triphasic waveforms, PSV 64cm/s.

TPT - patent and calcified, evidence of at least 2x vessel run off identified.

ATA and PTA - patent with mild diffuse dense and calcified disease, hyperaemic monophasic waveforms, PSV 58cm/s and 62cm/s, respectively. ?distal infection.

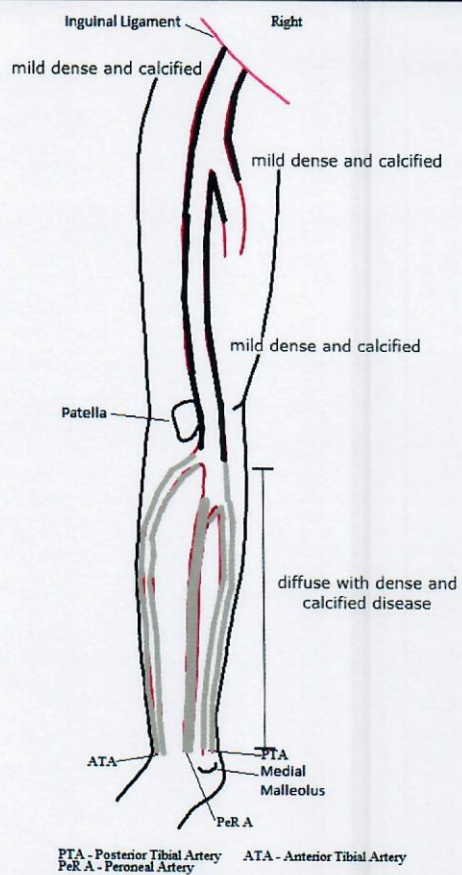
ABPIs not obtained due to patient positioning - ?accuracy of measurements.



Assessed by Jimmy Chen

Printed on 07/12/2018 at 9:59 am

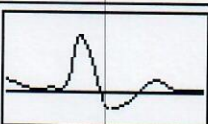




Checked by



Assessed by Jimmy Chen

Printed on 07/12/2018 at 9:59 am

Checked by

Reason	Claudication	
Outcome	Occlusion, Obscured, Calcified, Poor images	
<div style="display: flex; justify-content: space-between;"> <div style="width: 40%;"> <p style="text-align: center;">Right</p> <div style="display: flex; justify-content: space-around; margin-top: 10px;"> <div style="border: 1px solid black; padding: 2px 10px;">120</div> <div style="border: 1px solid black; padding: 2px 10px;">1.00</div> </div> </div> <div style="width: 55%; text-align: center;"> <p>Brachial</p> <hr/> <p>Common Femoral</p> <div style="display: flex; justify-content: space-between; align-items: center;"> <div style="border: 1px solid black; padding: 2px 10px;">Good</div> <div style="width: 100px; height: 50px; position: relative;">  </div> </div> <p>High Thigh</p> <p>Low Thigh</p> <p>Popliteal</p> <div style="display: flex; justify-content: space-between; align-items: center;"> <div style="border: 1px solid black; padding: 2px 10px;">Reduced</div> <div style="width: 100px; height: 50px; position: relative;">  </div> </div> <hr/> <p>High Calf</p> <p>Peroneal</p> <div style="display: flex; justify-content: space-between; align-items: center;"> <div style="border: 1px solid black; padding: 2px 10px;">Reduced</div> <div style="width: 100px; height: 50px; position: relative;">  </div> </div> <hr/> <p>Anterior Tibial</p> <div style="display: flex; justify-content: space-between; align-items: center;"> <div style="border: 1px solid black; padding: 2px 10px;">Reduced</div> <div style="display: flex; justify-content: space-around; width: 100px;"> <div style="border: 1px solid black; padding: 2px 10px;">85</div> <div style="border: 1px solid black; padding: 2px 10px;">0.71</div> </div> <div style="width: 100px; height: 50px; position: relative;">  </div> </div> <hr/> <p>Posterior Tibial</p> <div style="display: flex; justify-content: space-between; align-items: center;"> <div style="border: 1px solid black; padding: 2px 10px;">Reduced</div> <div style="width: 100px; height: 50px; position: relative;">  </div> </div> <hr/> <p>Dorsalis Pedis</p> <p>Toe Pressure</p> <hr/> <p>Post Exercise</p> </div> </div>		
<div style="display: flex; justify-content: space-between;"> <div style="width: 40%;"> <p style="text-align: center;">Left</p> <div style="display: flex; justify-content: space-around; margin-top: 10px;"> <div style="border: 1px solid black; padding: 2px 10px;">90</div> <div style="border: 1px solid black; padding: 2px 10px;">0.75</div> </div> </div> </div>		

Notes

LEFT LOWER LIMB ARTERIAL DUPLEX ASSESSMENT

Abdominal aorta is widely patent with good triphasic waveforms and PSV 96cm/s. The abdominal aorta appears of normal calibre (maximum AP = 1.56cm), with no evidence of focal dilatation or aneurysm identified.

CIA - patent with triphasic waveforms, PSV 126cm/s.

EIA - patent with triphasic waveforms, PSV 154cm/s.

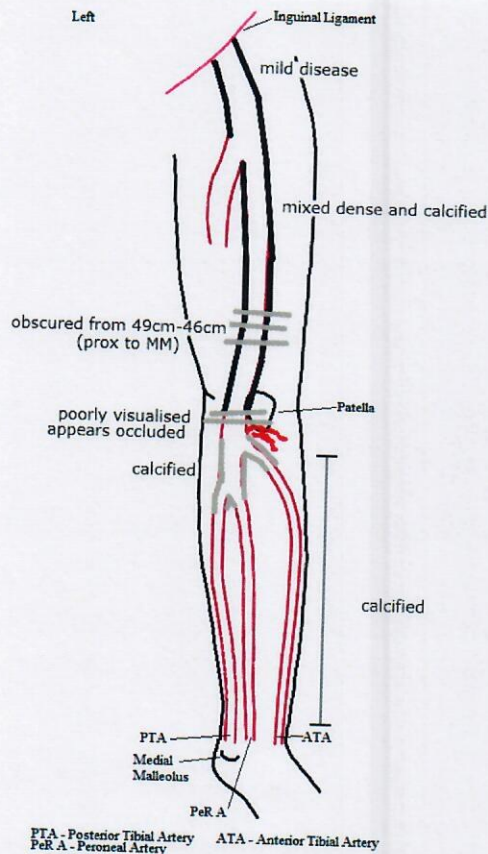
Assessed by Jimmy Chen

Printed on 07/12/2018 at 10:01 am

Checked by

CFA - patent with mild disease, triphasic waveforms, PSV 221cm/s
PFA (origin) - patent with triphasic waveforms, PSV 162cm/s
SFA - patent with mild dense and calcified disease, triphasic waveforms, PSV 150-84cm/s. Vessel is obscured in the mid thigh from 49-46cm (prox to medial malleolus) - triphasic waveforms obtained distal to the obscured area suggests no haemodynamically significant disease within obscured region. Distal vessel is calcified with biphasic waveforms, PSV 51cm/s.
PopA - proximal vessel poorly visualised and heavily calcified, no flow identified with collateral vessels noted. Where seen, proximal vessel appears occluded. Mid vessel is patent and calcified with reduced monophasic waveforms, PSV 20cm/s.
TPT - patent and calcified with evidence of at least 1x vessel run-off identified.
ATA - patent and calcified, monophasic waveforms, PSV 42cm/s.
PTA - patent and calcified, monophasic waveforms, PSV 27cm/s.
PerA - patent and calcified, monophasic waveforms, PSV 17cm/s.

Resting right and left ABPI are reduced.



Assessed by Jimmy Chen

Printed on 07/12/2018 at 10:01 am

Checked by

Reason Claudication
Outcome Occlusion, Obscured, Calcified, Bowel gas, Poor images

Right

160

1.00

Brachial

Common Femoral

Turbulent

High Thigh

Low Thigh

Popliteal

Reduced

High Calf

Peroneal

Anterior Tibial

Reduced

120

0.75

130

0.81

Posterior Tibial

Reduced

Dorsalis Pedis

Toe Pressure

Foot Flex

130

0.81

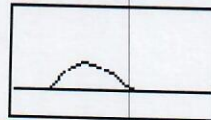
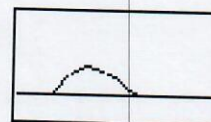

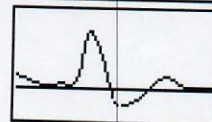
Post Exercise

Foot Flex

90

0.56

Left



Notes

LEFT LOWER LIMB ARTERIAL DUPLEX ASSESSMENT - Scanned in clinic.
Abdominal aorta is patent with bi/triphasic waveforms and PSV 35cm/s. The abdominal aorta appears of normal calibre (maximum AP = 2.1cm), with no evidence of focal dilatation or aneurysm identified.

CIA - difficulty visualising due to overlying bowel gas, however where seen, vessel appears patent with biphasic waveforms, PSV 52cm/s.

EIA - obscured due to overlying bowel gas due to overlying bowel gas, however where seen, vessel is patent with bi/triphasic waveforms, PSV 131-131cm/s.

Assessed by Jimmy Chen

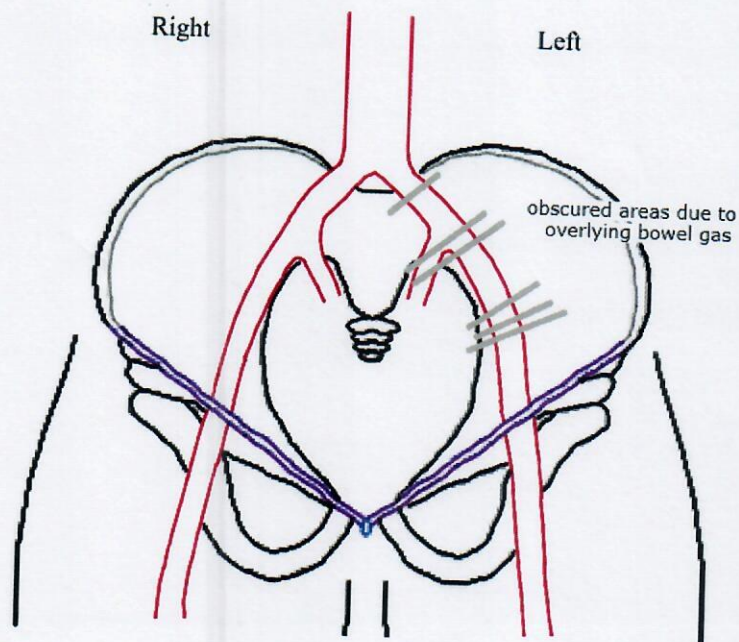
Printed on 07/12/2018 at 10:02 am

Checked by

CFA - patent with mild-moderate dense and calcified disease, turbulent triphasic waveforms, PSV 235cm/s.
 PFA - patent with mild dense and calcified disease, slightly turbulent triphasic waveforms, PSV 246cm/s.
 SFA - patent proximally with moderate dense and calcified disease, biphasic waveforms, PSV 58cm/s.
 Vessel occludes in the proximal thigh at 73cm (~11cm from the groin), and reforms in the distal thigh at 49cm. Distal vessel/adductor canal is patent with dense and calcified disease, reduced monophasic waveforms, PSV 22-34cm/s.
 PopA - patent and calcified with reduced monophasic waveforms, PSV 47-37cm/s.
 TPT - patent and calcified with evidence of at least 2x vessel run off identified.
 ATA and PTA - heavily calcified, however patent at the ankle with reduced monophasic waveforms, PSV 9cm/s and 12cm/s, respectively.
 PerA - no flow identified ?patency ?calcified.

Resting ABPI is reduced in the right lower limb.

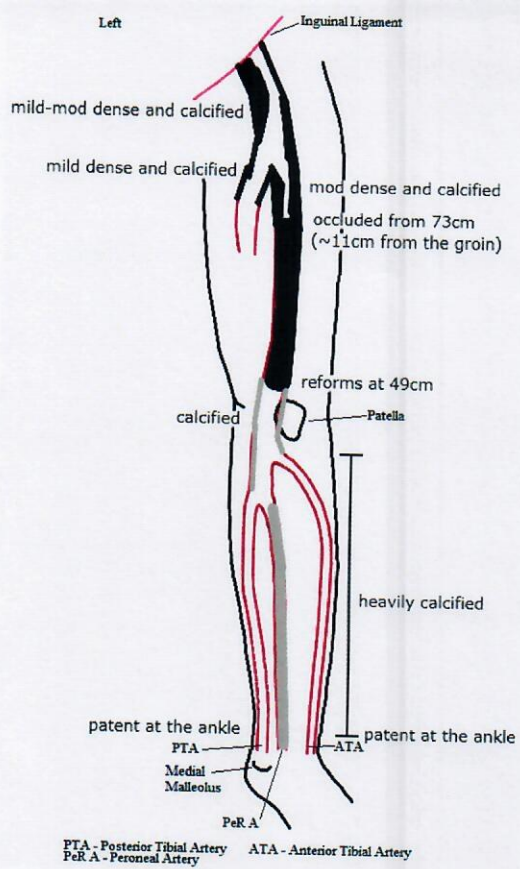
Resting left ABPI is borderline reduced and becomes reduced after a 1 minute foot-flex exercise challenge.



Assessed by Jimmy Chen

Printed on 07/12/2018 at 10:02 am


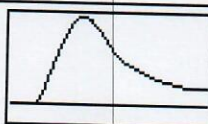






Checked by



Assessed by Jimmy Chen

Printed on 07/12/2018 at 10:02 am

Checked by

Reason	Rest pain	
Outcome	disease moderate, disease severe, Occlusion, Obscured, Bowel gas, Calcified	
Right		Left
<div> <div>140</div> <div>1.00</div> </div> <div>  <div>Good</div> </div>	Brachial	<div>  </div>
<div>  <div>Reduced</div> </div>	Common Femoral	<div> <div>Good</div> </div>
	High Thigh	
	Low Thigh	
	Popliteal	<div> <div>Reduced</div> </div> <div>  </div>
	High Calf	
	Peroneal	
<div>  <div>Reduced</div> <div>100</div> <div>0.71</div> </div>	Anterior Tibial	<div> <div>Reduced</div> <div>60</div> <div>0.43</div> </div> <div>  </div>
<div>  <div>Reduced</div> </div>	Posterior Tibial	<div> <div>Reduced</div> </div> <div>  </div>
	Dorsalis Pedis	
	Toe Pressure	
	Post Exercise	

Notes

BILATERAL LOWER LIMB ARTERIAL DUPLEX ASSESSMENT - Scanned in clinic.
 Abdominal aorta is patent, where seen, with biphasic waveforms and PSV 139cm/s. The abdominal aorta appears of normal calibre (maximum AP TS plane = 0.94cm), with no evidence of focal dilatation or aneurysm identified.

RIGHT

CIA - not visualised due to overlying bowel gas and patient discomfort.

EIA - patent with bi/triphasic waveforms, PSV 170-214cm/s.

Assessed by Jimmy Chen

Printed on 07/12/2018 at 10:03 am

Checked by

CFA - patent with mild dense disease, mono/triphasic waveforms, PSV 261cm/s.
PFA - patent with biphasic waveforms, PSV 162cm/s.
SFA - patent in the prox-mid vessel with mild dense disease, biphasic waveforms, PSV 115cm/s. Disease becomes moderate and calcified in the mid-distal vessel with monophasic waveforms, PSV 175-86cm/s.
PopA - patent and calcified with monophasic waveforms, PSV 55cm/s.
TPT - patent and calcified with evidence of at least 2x vessel run off identified.
ATA and PTA - patent and calcified, monophasic waveforms, PSV 31cm/s and 30cm/s, respectively.
PerA - no flow identified ?calcified.

LEFT

CIA - not visualised due to overlying bowel gas and patient discomfort.
EIA - poorly visualised, however elevated velocities obtained in the proximal vessel with turbulent monophasic waveforms, PSV 548cm/s - suggestive of at least a mod-severe stenosis. Mid-distal vessel remains patent with moderate turbulent monophasic waveforms, PSV 152cm/s.

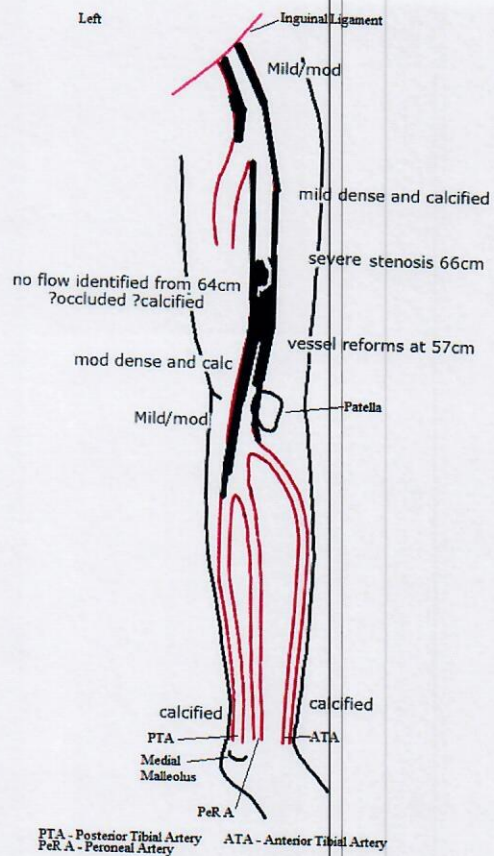
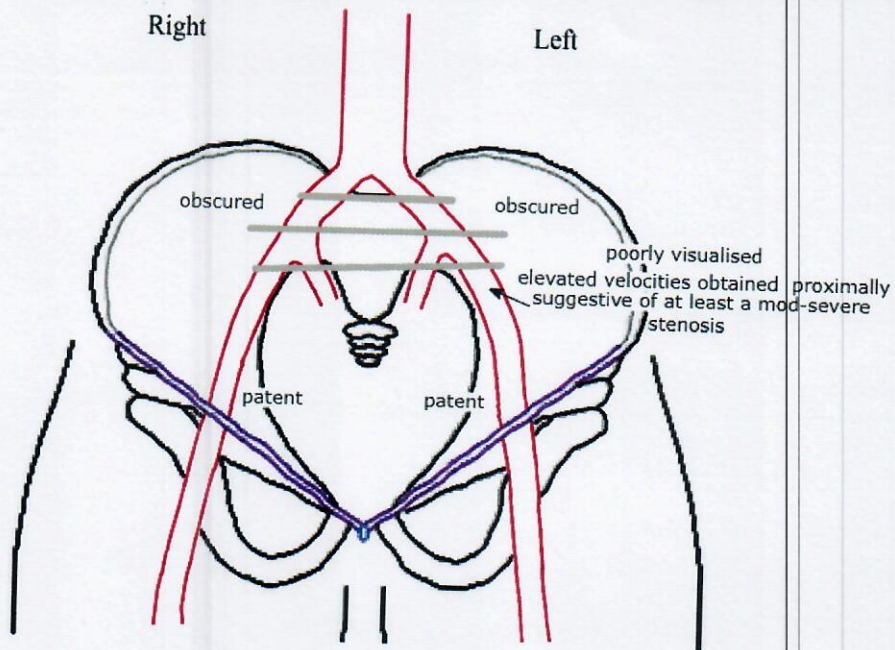
CFA - patent with mild dense disease, monophasic waveforms, PSV 121cm/s.
PFA - patent with monophasic waveforms, PSV 130cm/s.
SFA - patent with mild dense and calcified disease, monophasic waveforms, PSV 82cm/s. Disease becomes mod-severe in the prox-mid thigh at 66cm, monophasic waveforms, PSV 74-157cm/s pre-occlusive trickle flow noted. No flow identified in the prox-mid thigh at 64cm ?calcified ?occluded. Trickle flow noted in the mid thigh at 57cm and reforms the vessel distally with moderate dense and calcified disease, reduced monophasic waveforms, PSV 47cm/s.
PopA - patent and calcified with monophasic waveforms, PSV 52cm/s.
TPT - patent and calcified with evidence of at least 2x vessel run off identified.
ATA and PTA - patent and calcified, monophasic waveforms, PSV 20cm/s and 24cm/s, respectively.
PerA - no flow identified ?calcified.

Resting ABPI is reduced in the right and significantly reduced in the left lower limb .

Assessed by Jimmy Chen

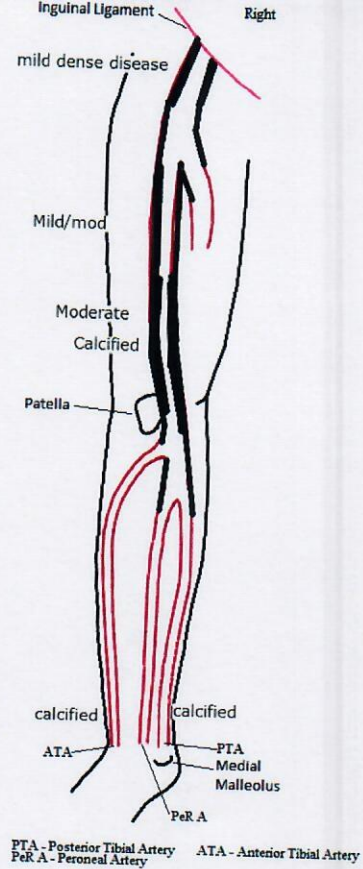
Printed on 07/12/2018 at 10:03 am

Checked by



Assessed by Jimmy Chen
Printed on 07/12/2018 at 10:03 am

Checked by




Assessed by Jimmy Chen
Printed on 07/12/2018 at 10:03 am

Checked by

Reason Claudication
Outcome disease moderate, disease severe, Obscured, Calcified

Right

150 1.00



Good

Brachial

Common Femoral

High Thigh

Low Thigh

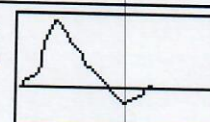
Popliteal

High Calf


Peroneal

Left

Good



Reduced



Reduced

Slightly Reduced

90 0.60

Anterior Tibial

Good

120 0.80

Posterior Tibial

Good

Dorsalis Pedis

Toe Pressure

Post Exercise

Notes

BILATERAL LOWER LIMB ARTERIAL DUPLEX SCAN

Aorta – Patent with good triphasic flow, PSV 78cm/s. Vessel appears to be of normal and uniform calibre - maximally measuring 1.04cm (TS plane; outer-to-outer wall)

RIGHT

CIA – Patent with good triphasic flow, PSV 83cm/s.

EIA – Proximal vessel not adequately visualised due to depth and overlying bowel gas. Mid to distal vessel is

Assessed by Jimmy Chen

Printed on 07/12/2018 at 10:05 am

Checked by

patent with triphasic flow, PSV 129cm/s.

CFA – Patent with mild dense disease, triphasic flow, PSV 154cm/s.

PFA (origin) – Patent with biphasic flow, PSV 121cm/s.

SFA – Patent with moderate-severe diffuse dense and calcified disease in the prox-mid vessel, monophasic flow, PSV 77-140cm/s. Mid-distal vessel remains patent with mild dense and calcified disease, monophasic waveforms, PSV 36-110-66cm/s.

POP – Patent and calcified with monophasic flow, PSV 36cm/s.

TPT – Patent and calcified with origins of 2 VRO identified.

PTA – Patent to the ankle with monophasic flow, PSV 43cm/s.

ATA – Patent to the ankle with monophasic flow, PSV 42cm/s.

PerA – no flow identified ?calcified

LEFT

CIA – Patent with good triphasic flow, PSV 90cm/s.

EIA – Proximal vessel not adequately visualised due to depth and overlying bowel gas. Mid to distal vessel is patent with biphasic flow, PSV 196cm/s.

CFA - Patent with mild dense disease, biphasic flow, PSV 240cm/s.

PFA (origin) – Patent with biphasic flow, PSV 210cm/s.

SFA – Patent proximally with mild dense disease, biphasic flow, PSV 129-159cm/s. Disease becomes mild-moderate and calcified in the mid-distal vessel, biphasic waveforms, PSV 93cm/s.

POP – Patent and calcified with monophasic flow, PSV 79cm/s.

TPT – Patent and calcified, unable to visualise TPT vessel run off.

PTA – Patent to the ankle with triphasic flow, PSV 90cm/s.

ATA – Patent to the ankle with triphasic flow, PSV 81cm/s.

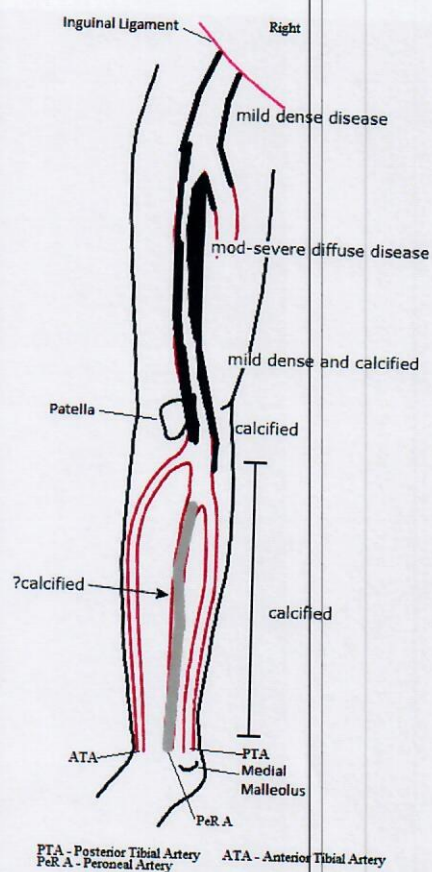
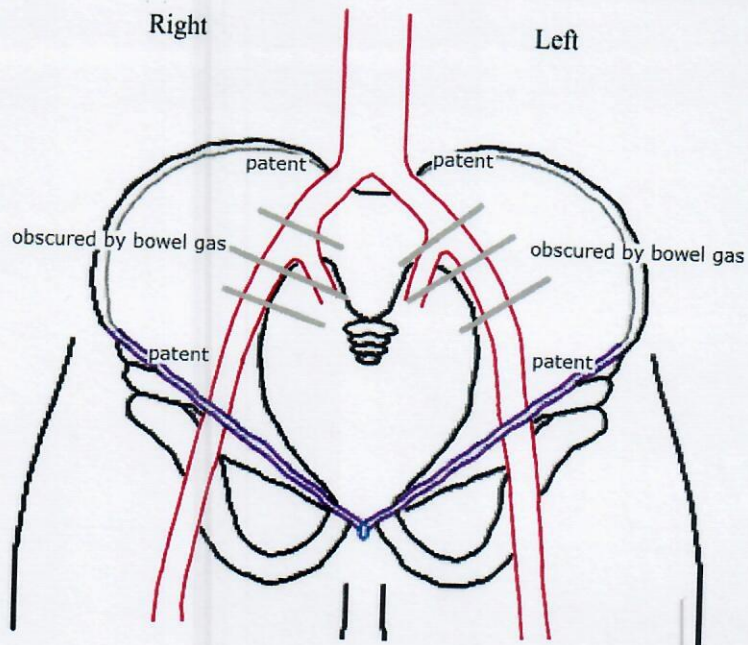
PerA – no flow identified ?calcified

Resting ABPI is reduced in the right and borderline reduced in the left lower limb.

Assessed by Jimmy Chen

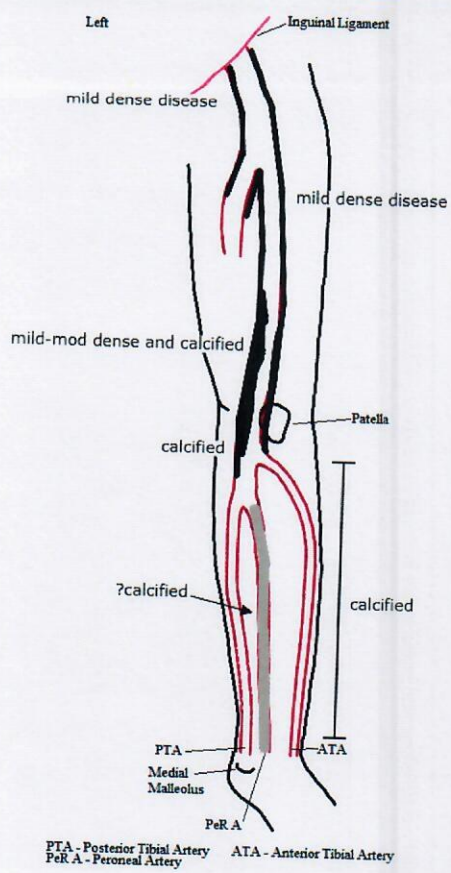
Printed on 07/12/2018 at 10:05 am

Checked by



Assessed by Jimmy Chen
Printed on 07/12/2018 at 10:05 am

Checked by




Assessed by Jimmy Chen
Printed on 07/12/2018 at 10:05 am

Checked by

Reason Claudication
Outcome disease mild, Poor images, Calcified

Right

110 1.00



Good

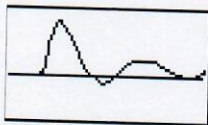
Brachial

Common Femoral

High Thigh

Low Thigh


Popliteal



Slightly Reduced


High Calf

Peroneal



Slightly Reduced

Anterior Tibial



Slightly Reduced

85

0.77

Posterior Tibial

85

0.77

Dorsalis Pedis

Toe Pressure

Post Exercise

Left

Notes

RIGHT LOWER LIMB ARTERIAL DUPLEX ASSESSMENT - Scanned in clinic
Abdominal aorta is patent with good triphasic waveforms and PSV 67cm/s. The abdominal aorta appears of ectatic (maximum AP = TS plane - 2.84cm / LS plane - 2.83cm) - suggest further surveillance scan, if required.

CIA - proximal vessel is patent with triphasic waveforms, PSV 54cm/s. Mid-distal vessel not visualised due to bowel gas and depth.

EIA - patent with triphasic waveforms, PSV 95-77cm/s.

Assessed by Jimmy Chen

Printed on 07/12/2018 at 10:06 am

Checked by

CFA - patent with mild dense disease, triphasic waveforms, PSV 76cm/s.

PFA (origin) - patent with triphasic waveforms, PSV 63cm/s.

SFA - prox-mid vessel is patent with mild dense disease, triphasic waveforms, PSV 70-59cm/s. Mid-distal vessel becomes calcified, however triphasic waveforms obtained, PSV 64cm/s.

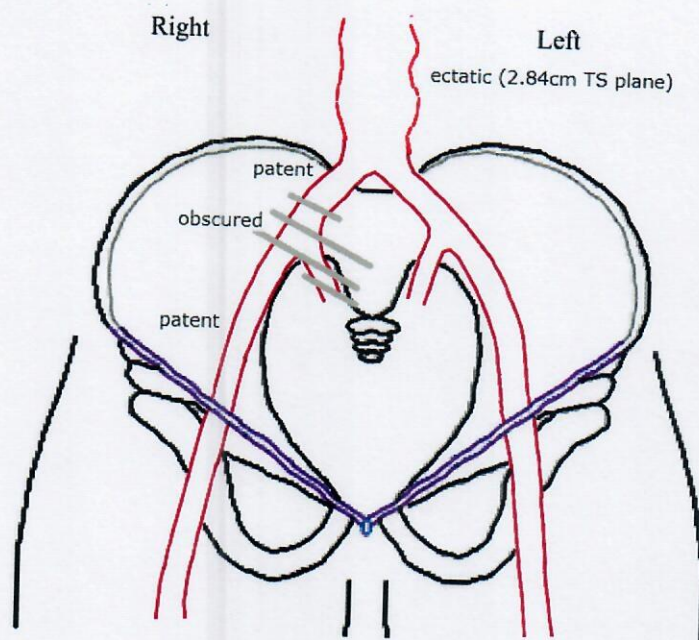
PopA - patent and calcified, triphasic waveforms, PSV 31cm/s.

TPT - patent and calcified, evidence of 3x vessel run off identified.

ATA - patent proximally with biphasic waveforms, PSV 36cm/s. Mid-distal vessel is heavily calcified with no flow obtained at the ankle ?patency.

PTA - heavily calcified, however patent at the ankle with biphasic waveforms, PSV 22cm/s.

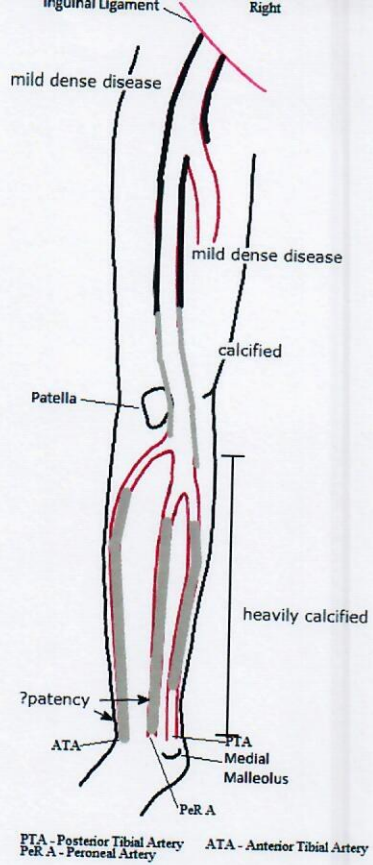
Resting right and left ABPI are borderline reduced.



Assessed by Jimmy Chen

Printed on 07/12/2018 at 10:06 am

Checked by



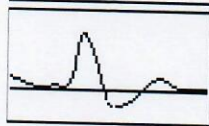
Assessed by Jimmy Chen
Printed on 07/12/2018 at 10:06 am

Checked by


Reason Claudication
Outcome disease severe, Obscured, Calcified, Stenosis Severe

Right


125 1.00



Good




Good



Slightly Reduced

110

0.88



Slightly Reduced

Brachial

Common Femoral

High Thigh

Low Thigh

Popliteal

High Calf

Peroneal

Anterior Tibial

Posterior Tibial

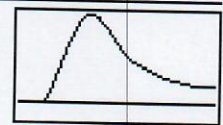
Dorsalis Pedis

Toe Pressure


Post Exercise

Left

Slightly Reduced




Slightly Reduced



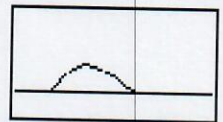
Reduced

75

0.60



Reduced



Notes

BILATERAL LOWER LIMB ARTERIAL DUPLEX ASSESSMENT - Scanned in clinic.
 Abdominal aorta is patent with bi/triphasic waveforms and PSV 67cm/s. The abdominal aorta appears of normal calibre (maximum AP TS plane= 1.18cm), with no evidence of focal dilatation or aneurysm identified.

RIGHT

CIA - obscured by bowel gas, however where seen, no elevated velocities obtained, biphasic waveforms, PSV 196cm/s.

EIA - obscured by bowel gas, where seen, vessel is patent with triphasic waveforms, PSV 140cm/s.

Assessed by Jimmy Chen

Printed on 07/12/2018 at 10:07 am

Checked by

CFA - patent with mild dense disease, triphasic waveforms, PSV 159cm/s.
PFA (origin) - patent with triphasic waveforms, PSV 241cm/s.
SFA - patent in the prox-mid vessel with mild dense and calcified disease, tri/biphasic waveforms, PSV 135-122cm/s. Vessel becomes heavily calcified in the mid-distal vessel, biphasic waveforms, PSV 139cm/s.
PopA - patent and calcified, biphasic waveforms, PSV 78cm/s.
TPT - patent and calcified, with evidence of 3x vessel run off identified.
ATA and PTA - calcified, however patent at the ankle with biphasic waveforms, PSV 58cm/s and 41cm/s, respectively.

LEFT

CIA - obscured by bowel gas, however where seen, elevated velocities obtained, with turbulent monophasic waveforms, PSV 458-404cm/s - suggestive of severe disease/stenosis.
EIA - obscured by bowel gas, where seen, vessel is patent with monophasic waveforms, PSV 119cm/s.

CFA - patent with mild dense disease, monophasic waveforms, PSV 118cm/s.
PFA (origin) - patent with mono/biphasic waveforms, PSV 105cm/s.
SFA - patent in the prox-mid vessel with mild dense and calcified disease, biphasic waveforms, PSV 81-91cm/s. Vessel becomes heavily calcified in the mid-distal vessel, biphasic waveforms, PSV 73cm/s.
PopA - patent and calcified, biphasic waveforms, PSV 43cm/s.
TPT - patent and calcified, with evidence of 2x vessel run off identified.
ATA - calcified, however patent at the ankle with biphasic waveforms, PSV 40cm/s.
and PTA - calcified, however patent in the mid calf with reduced monophasic waveforms, PSV 25cm/s. No flow identified at the ankle ?patency ?calcified.

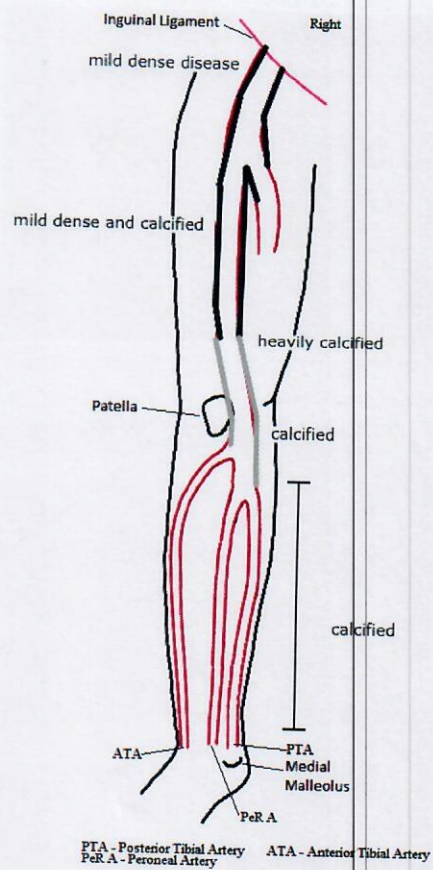
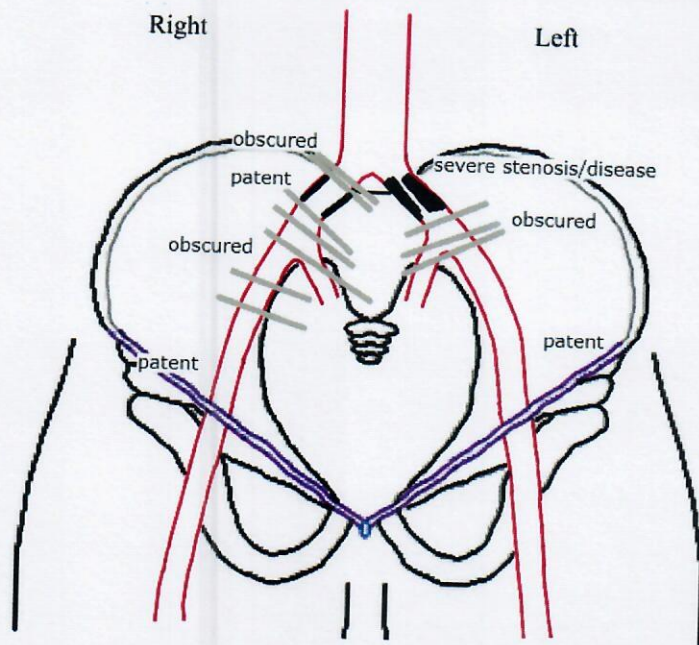
Resting ABPI are within normal limits in the right and reduced in the left lower limb.

CONCLUSION: Evidence of severe disease/stenosis in the left CIA.

Assessed by Jimmy Chen

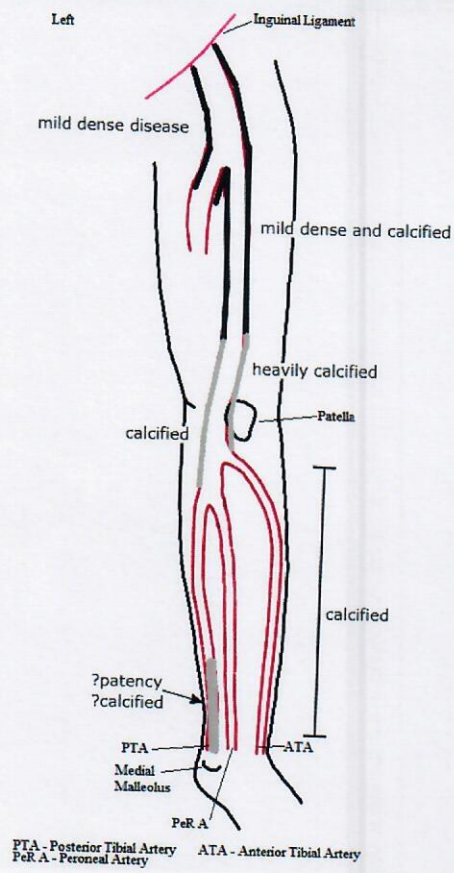
Printed on 07/12/2018 at 10:07 am

Checked by



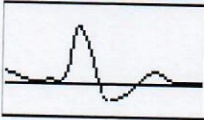


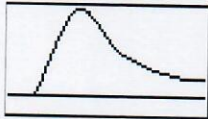
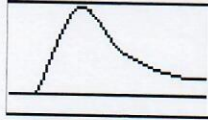
Assessed by Jimmy Chen
 Printed on 07/12/2018 at 10:07 am

Checked by



Assessed by Jimmy Chen
Printed on 07/12/2018 at 10:07 am

Checked by

Reason	Routine			
Outcome	?infection, Patent, Calcified			
Right				Left
	120	1.00	Brachial	
	Good		Common Femoral	
			High Thigh	
			Low Thigh	
	Slightly Reduced		Popliteal	
			High Calf	
	Slightly Reduced		Peroneal	
	Slightly Reduced		Anterior Tibial	
	110	0.92		
	Slightly Reduced		Posterior Tibial	
			Dorsalis Pedis	
			Toe Pressure	
			Post Exercise	
	Foot Flex			
	120	1.00		

Notes

RIGHT LOWER LIMB ARTERIAL DUPLEX ASSESSMENT - scanned in clinic.
 Difficulty visualising the abdominal aorta due to patient habitus and associated vessel depth and overlying bowel gas. Where seen, the abdominal aorta is patent with biphasic waveforms and PSV 83cm/s. The abdominal aorta appears of normal calibre where seen (maximum AP = 2.03cm), with no evidence of focal dilatation or aneurysm identified.

CIA - not visualised due to overlying bowel gas, vessel depth and patient discomfort.

EIA - difficulty visualising vessel due to patient discomfort and overlying bowel gas. Where seen, vessel

Assessed by Jimmy Chen

Printed on 07/12/2018 at 10:08 am

Checked by

appears patent with triphasic waveforms, PSV 175cm/s.

CFA - patent with triphasic waveforms, PSV 123cm/s.

PFA (origin) - patent with biphasic waveforms, PSV 65cm/s.

SFA - patent with mild dense disease proximally, triphasic waveforms, PSV 99cm/s. Disease becomes calcified in the mid-distal vessel with mono/triphasic waveforms, PSV 95-113cm/s.

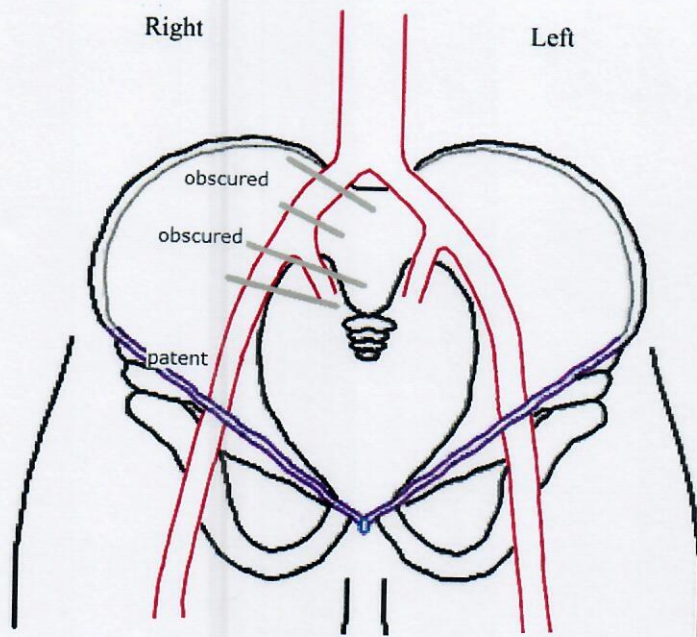
PopA - patent and calcified, monophasic waveforms, PSV 82cm/s.

TPT - patent and calcified, evidence of at least 2x vessel run off identified.

ATA, PTA and PerA - patent and calcified, monophasic waveforms, PSV 71cm/s, 38cm/s and 90cm/s, respectively.

Resting ABPI is within normal limits and remains so following a 1 minute foot-flex exercise challenge.

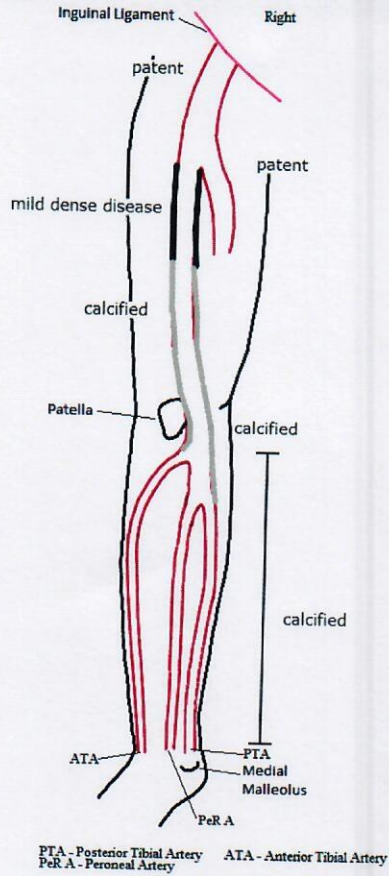
Additional comments: enlarged lymph nodes noted in the groin ?infection.



Assessed by Jimmy Chen

Printed on 07/12/2018 at 10:08 am

Checked by



Assessed by Jimmy Chen
Printed on 07/12/2018 at 10:08 am

Checked by

Ulceration

Outcome

Obscured, Calcified, Poor images, patient habitus

Right

160

1.00

Good

Brachial

Common Femoral

High Thigh

Low Thigh

Popiteal

High Calf

Peroneal

Anterior Tibial

Posterior Tibial

Dorsalis Pedis

Toe Pressure

Post Exercise

Left

Good

Good

Absent

Absent

Reduced

240

1.50

Notes

BILATERAL LOWER LIMB ARTERIAL DUPLEX SCAN – Scanned in clinic

*challenging scan with sub-optimal images obtained due to patient habitus, patient discomfort, poor mobility and heavily calcification.

Aorta – not visualised due to associated vessel depth.

RIGHT

CIA – not visualised due to associated vessel depth.

Assessed by Jimmy Chen

Printed on 07/12/2018 at 10:10 am

Checked by

EIA – prox-mid vessel not visualised due to associated vessel depth and patient discomfort. Patent in the distal vessel with good triphasic flow, PSV 103cm/s.
CFA – Patent with mild dense and calcified disease, triphasic flow, PSV 139cm/s.
PFA (origin) – patent with biphasic flow, PSV 116cm/s.
SFA – patent in the prox-mid vessel with dense and calcified disease, tri-biphasic waveforms, PSV 116-76cm/s. No flow identified in the distal vessel/adductor canal ?due to heavy calcification.
POP – Prox vessel poorly visualised - unable to exclude significant stenosis/disease from these images. Distal vessel is patent and calcified with mono/triphasic waveforms, PSV 57-64cm/s.
TPT – calcified, evidence of at least 1 vessel run off identified.
ATA – no flow identified ?patency ?calcified.
PTA – heavily calcified, however patent in the mid calf with monophasic waveforms, PSV 47cm/s.
PerA – no flow identified ?patency ?calcified.

LEFT

CIA – not visualised due to associated vessel depth.
EIA – prox-mid vessel not visualised due to associated vessel depth and patient discomfort. Patent in the distal vessel with good triphasic flow, PSV 116cm/s.
CFA – Patent with mild dense and calcified disease, triphasic flow, PSV 114cm/s.
PFA (origin) – patent with biphasic flow, PSV 72cm/s.
SFA – patent in the prox vessel with dense and calcified disease, triphasic waveforms, PSV 88cm/s.
Multiple obscured areas in the mid-distal vessel due to extensive calcification, where seen vessel is patent with mono/triphasic waveforms, PSV 112-80cm/s - unable to fully exclude significant stenosis/disease within obscured areas.
POP – patent and calcified with triphasic waveforms, PSV 63cm/s.
TPT – calcified ?patency
ATA – no flow identified ?patency ?calcified.
PTA – no flow identified, however reduced monophasic waveforms obtained using HHD.
PerA – no flow identified ?patency ?calcified.

Resting right and left ABPI are falsely elevated due to calcified crural vessels.

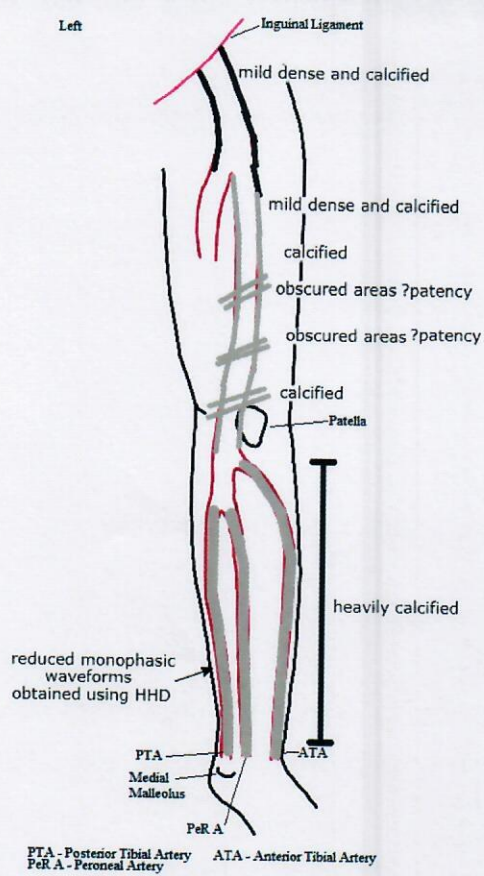
Assessed by Jimmy Chen

Printed on 07/12/2018 at 10:10 am

Checked by



Checked by




Assessed by Jimmy Chen
Printed on 07/12/2018 at 10:10 am

Checked by

Reason Claudication
Outcome disease mild, Obscured, Calcified

Right

110 1.00



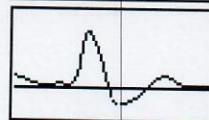
Good

Brachial

Common Femoral

Good

Left

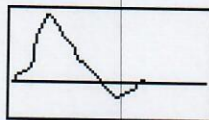


High Thigh

Low Thigh


Popliteal

Good

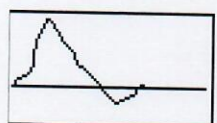


High Calf

Peroneal



Good



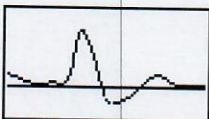
Good

115 1.05

Anterior Tibial

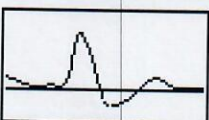
Good

110 1.00



Posterior Tibial

Good



Dorsalis Pedis

Toe Pressure

Foot Flex

95 0.86

Post Exercise

Foot Flex

90 0.82

Notes

BILATERAL LOWER LIMB ARTERIAL DUPLEX ASSESSMENT

Abdominal aorta is patent with good triphasic waveforms and PSV 91cm/s. The abdominal aorta appears of normal calibre (maximum AP = 1.33cm TS plane), with no evidence of focal dilatation or aneurysm identified.

RIGHT

CIA - Not adequately visualised due to vessel movement with respiration and overlying bowel gas.

EIA - patent with bi/triphasic waveforms, PSV 208-161cm/s.

Assessed by Jimmy Chen

Printed on 07/12/2018 at 10:13 am

Checked by

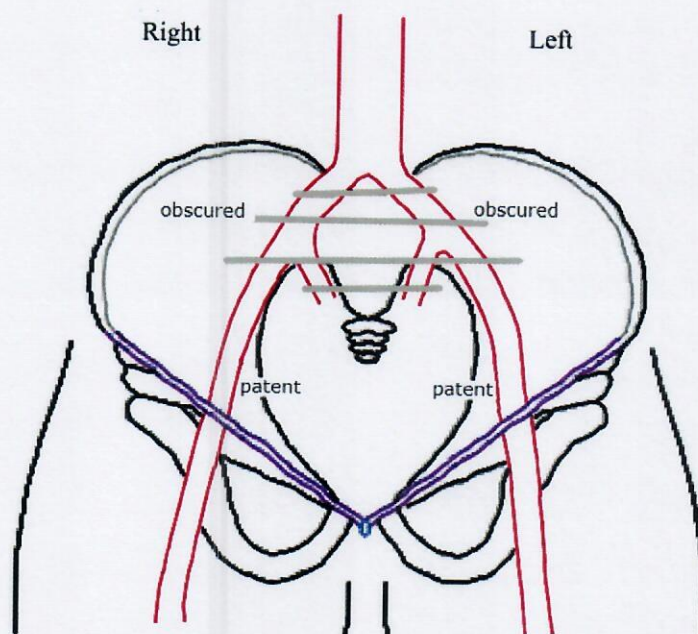
CFA - patent with triphasic waveforms, PSV 158cm/s.
PFA - patent with biphasic waveforms, PSV 117cm/s.
SFA - patent with mild dense and calcified disease, biphasic waveforms, PSV 98-92-61cm/s.
PopA - patent and calcified, biphasic waveforms, PSV 53cm/s.
TPT - patent and calcified with evidence of 3x vessel run off identified.
ATA and PTA - patent and mildly calcified, bi/triphasic waveforms, PSV 56cm/s and 91cm/s, respectively.
PerA - no flow identified ?calcified.

LEFT

CIA - Not adequately visualised due to vessel movement with respiration and overlying bowel gas.
EIA - patent with biphasic waveforms, PSV 181-129cm/s.

CFA - patent with triphasic waveforms, PSV 158cm/s.
PFA - patent with biphasic waveforms, PSV 117cm/s.
SFA - patent in the prox-mid vessel with mild dense and calcified disease, biphasic waveforms, PSV 71cm/s. Mid-distal vessel becomes heavily calcified with the mid vessel being obscured for a length of 3.12cm, however waveforms obtained distal to this remain biphasic, PSV 78-55cm/s.
PopA - patent and calcified, biphasic waveforms, PSV 58cm/s.
TPT - patent and calcified with evidence of 2x vessel run off identified.
ATA and PTA - patent and mildly calcified, triphasic waveforms, PSV 68cm/s and 61cm/s, respectively.
PerA - no flow identified ?calcified.

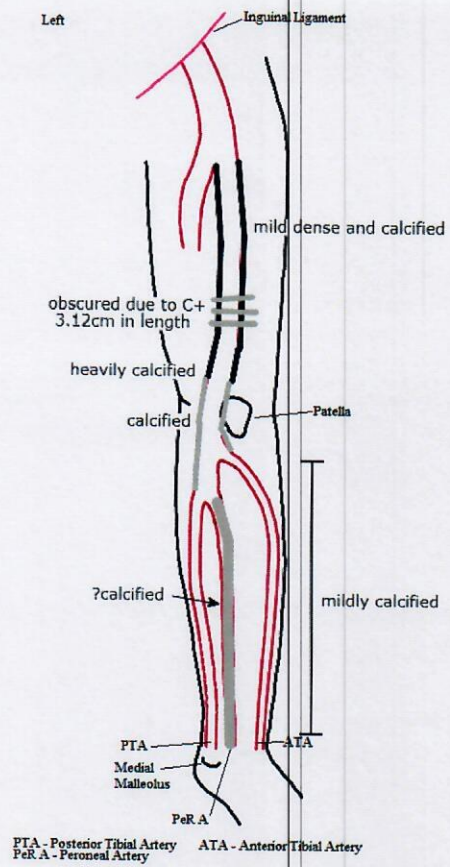
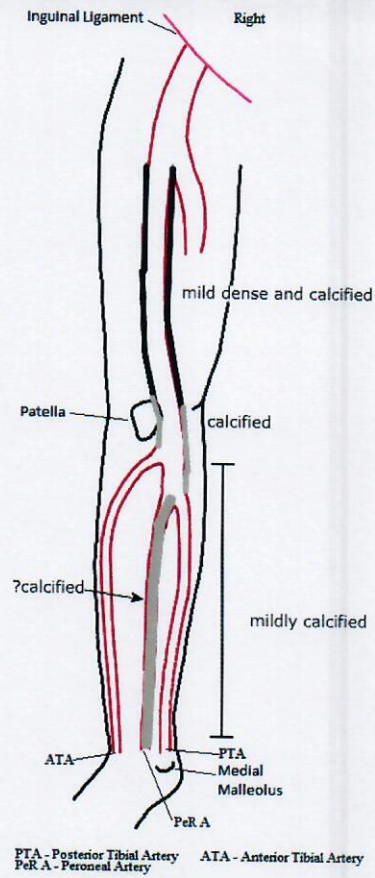
Resting right and left ABPI are within normal limits and remain so following a 1 minute foot-flex exercise challenge.



Assessed by Jimmy Chen

Printed on 07/12/2018 at 10:13 am

Checked by



Assessed by Jimmy Chen
Printed on 07/12/2018 at 10:13 am

Checked by

Reason Routine
Outcome Calcified, Patent

Right

115

1.00

Brachial

Common Femoral

Good

High Thigh

Low Thigh

Popliteal

Good

High Calf

Peroneal

Slightly Reduced

Anterior Tibial

Good

130

1.13

105

0.91

Posterior Tibial

Good

Dorsalis Pedis

Toe Pressure

Foot Flex

120

1.04



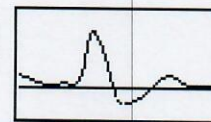
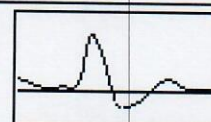
Post Exercise

Foot Flex

120

1.04

Left



Notes

LEFT LOWER LIMB ARTERIAL DUPLEX ASSESSMENT

CFA - patent with triphasic waveforms, PSV 105cm/s.

PFA (origin) - patent with triphasic waveforms, PSV 89cm/s.

SFA - patent along length with triphasic waveforms, PSV 95-75-75cm/s.

PopA - patent with triphasic waveforms, PSV 58cm/s.

TPT - patent with evidence of at least 2x vessel run off identified.

ATA and PTA - patent and mildly calcified, triphasic waveforms, PSV 58cm/s and 64cm/s respectively.

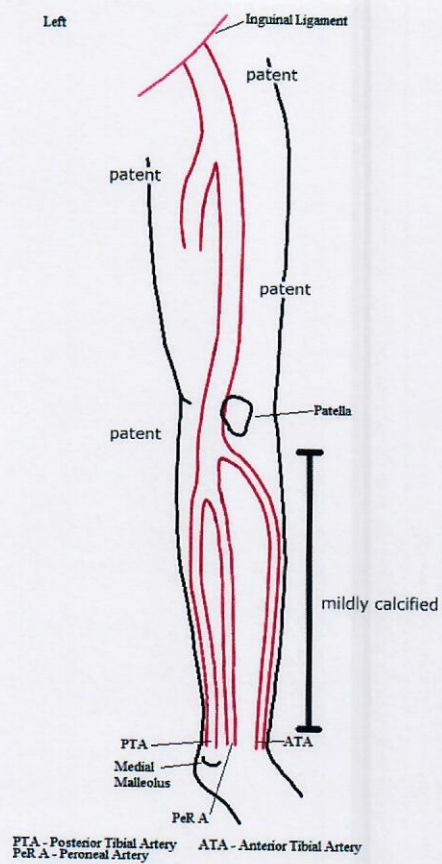
Assessed by Jimmy Chen

Printed on 07/12/2018 at 10:14 am

Checked by

PeRA - patent and calcified, mono/biphasic waveforms, PSV 19cm/s.

Resting right and left ABPI are within normal limits and remain so following a 1 minute foot-flex exercise challenge.







Assessed by Jimmy Chen

Printed on 07/12/2018 at 10:14 am

Checked by

Reason Ischaemia, Stent
Outcome Calcified, Stenosis Moderate

Right		Left	
	160 1.00 Slightly Reduced	Brachial	
	Reduced	Common Femoral	
		High Thigh	
		Low Thigh	
		Popliteal	
		High Calf	
		Peroneal	
	Reduced 120 0.75	Anterior Tibial	150 0.94
	Reduced	Posterior Tibial	
		Dorsalis Pedis	
		Toe Pressure	
		Post Exercise	

Notes

RIGHT LOWER LIMB ARTERIAL DUPLEX ASSESSMENT - (Prev. Right SFA Angioplasty)

RIGHT

CFA appears patent, mild dense disease, triphasic waveforms, PSV 199cm/s.

PFA (origin) appears patent, no mild disease, triphasic waveforms, PSV 170cm/s.

SFA - moderate stenosis identified at the origin extending for a length of ~1.05cm, elevated velocities obtained with turbulent monophasic waveforms, PSV 335cm/s. Stent identified in the mid vessel which is patent, monophasic waveforms, PSV 104cm/s. Distal vessel is patent with mild dense and calcified

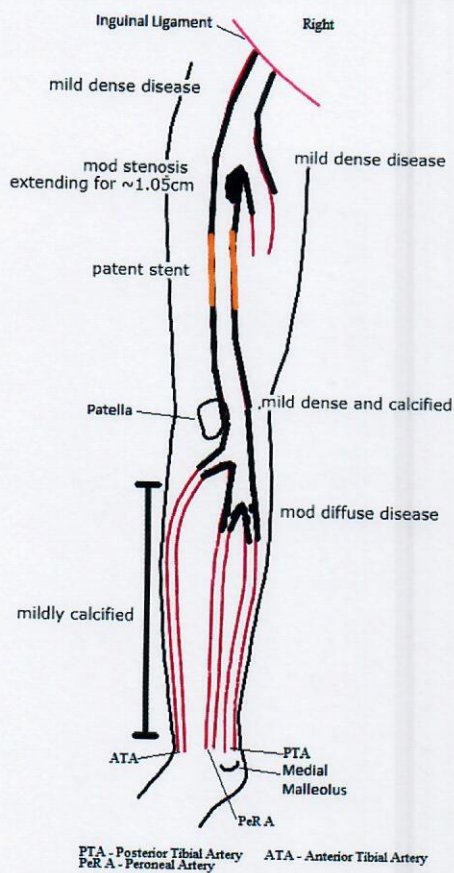
Assessed by Jimmy Chen

Printed on 07/12/2018 at 10:17 am

Checked by

disease. Monophasic waveforms, PSV 104cm/s.
 POPA appears patent, no mild dense and calcified disease, monophasic waveforms, PSV 63cm/s. TPT
 appears patent with moderate diffuse disease; origins of 2x vessel runoff noted
 ATA and PTA appears patent and mildly calcified, monophasic waveforms, PSV 69cm/s and 64cm/s
 respectively.

Resting ABPI are reduced in the right and within normal limits in the left.




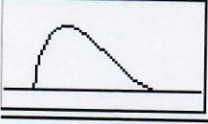


Assessed by Jimmy Chen

Printed on 07/12/2018 at 10:17 am

Checked by

Reason: Angioplasty, Angioplasty crural
 Outcome: Obscured, Calcified, Poor images

Right			Left
	130	1.00	
	Good	Brachial	
		Common Femoral	
		High Thigh	
		Low Thigh	
	Slightly Reduced	Popliteal	
		High Calf	
		Peroneal	
	Reduced	Anterior Tibial	
	240	1.85	240
	Reduced	Posterior Tibial	
		Dorsalis Pedis	
		Toe Pressure	
		Post Exercise	

Notes

RIGHT LOWER LIMB ARTERIAL DUPLEX ASSESSMENT - PREVIOUS SFA AND ATA ANGIOPLASTY

Abdominal aorta is patent with biphasic waveforms and PSV 39cm/s. The abdominal aorta appears of normal calibre (maximum AP = 1.81cm), with no evidence of focal dilatation or aneurysm identified.

CIA - patent with biphasic waveforms, PSV 49cm/s.

EIA - patent with biphasic waveforms, PSV 71cm/s.

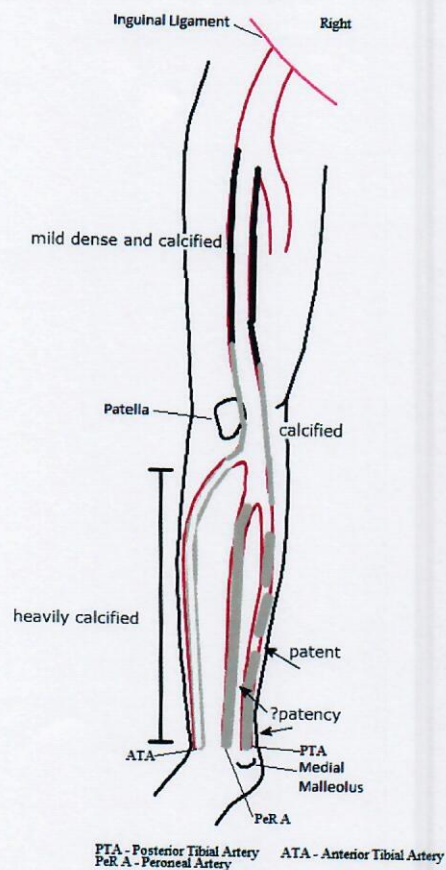
Assessed by Jimmy Chen

Printed on 07/12/2018 at 10:18 am

Checked by

CFA - patent with slightly reduced biphasic waveforms, PSV 88cm/s.
PFA (origin) - patent with slightly reduced biphasic waveforms, PSV 45cm/s.
SFA - patent in the prox-mid vessel with mild dense and calcified disease, slightly reduced biphasic waveforms, PSV 56-57cm/s. Distal vessel/adductor canal is heavily calcified with slightly reduced biphasic waveforms, PSV 47cm/s.
PopA - patent and calcified, slightly reduced biphasic waveforms, PSV 37cm/s.
TPT - patent and calcified, evidence of 3x vessel run off identified.
ATA - patent and heavily calcified, monophasic waveforms, PSV 143cm/s.
PTA - heavily calcified however vessel appears patent in the mid calf with monophasic waveforms, PSV 40cm/s. No flow identified at the ankle ?calcified ?patency.

Resting right and left ABPI are falsely elevated due to calcified crural vessels.



Assessed by Jimmy Chen


Printed on 07/12/2018 at 10:18 am

Checked by

Reason Stent
Outcome Widely patent

Right

115 1.00




Good

Brachial

Common Femoral

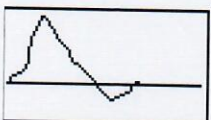
High Thigh

Low Thigh



Slightly Reduced

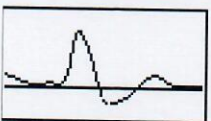
Popliteal



Slightly Reduced

High Calf

Peroneal




Good

Anterior Tibial

125 1.09

130 1.13



Good

Posterior Tibial

Dorsalis Pedis

Toe Pressure

Foot Flex

130 1.13

Post Exercise

Foot Flex

120 1.04

Left

Notes

RIGHT LOWER LIMB ARTERIAL DUPLEX ASSESSMENT - PREVIOUS RIGHT CIA STENT

Abdominal aorta is widely patent with biphasic waveforms and PSV 83cm/s. The abdominal aorta appears of normal calibre (maximum AP = 1.86cm), with no evidence of focal dilatation or aneurysm identified.

CIA - stent appears widely patent with bi/triphasic waveforms, PSV 171cm/s.

EIA - patent with triphasic waveforms, PSV 79cm/s.

CFA - patent with triphasic waveforms, PSV 122cm/s.

Assessed by Jimmy Chen

Printed on 07/12/2018 at 10:21 am

Checked by

PFA (origin) - patent with triphasic waveforms, PSV 83cm/s.

SFA - patent in the prox-mid vessel with triphasic waveforms, PSV 98-97cm/s. Distal vessel/adductor canal is calcified with triphasic waveforms, PSV 72cm/s.

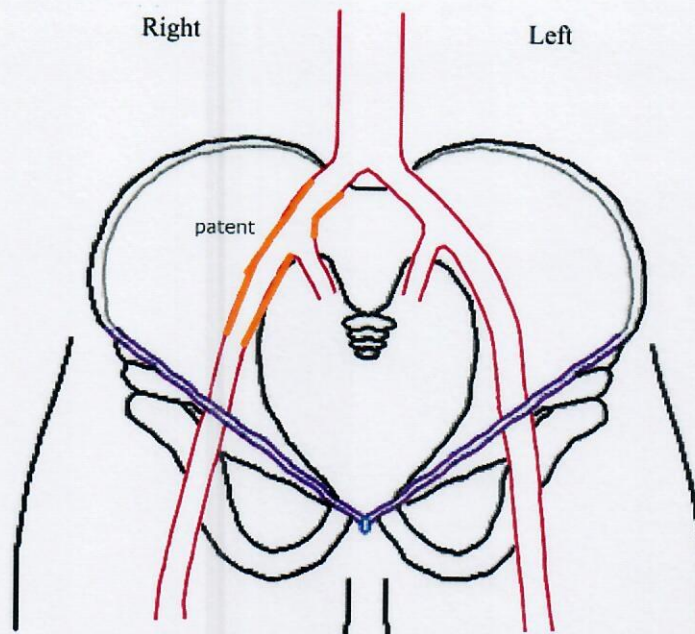
PopA - patent with slightly reduced triphasic waveforms, PSV 47cm/s.

TPT - patent with evidence of 3x vessel run off identified.

ATA and PTA - patent with triphasic waveforms, PSV 61cm/s and 57cm/s respectively.

PerA - patent and calcified with biphasic waveforms, PSV 20cm/s.

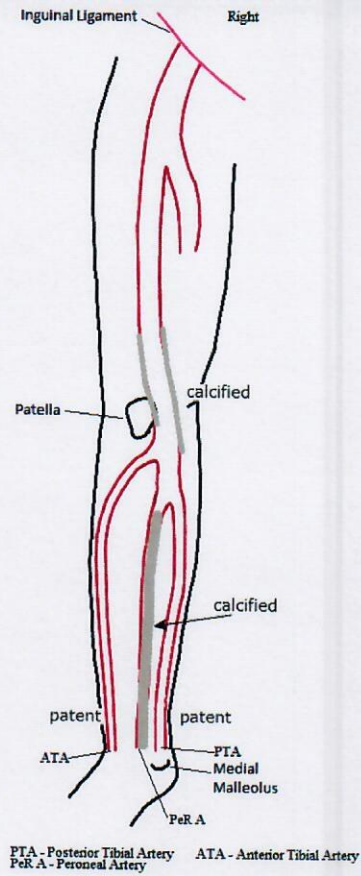
Resting right and left ABPI are within normal limits and remain so following a 1 minute foot-flex exercise challenge.



Assessed by Jimmy Chen

Printed on 07/12/2018 at 10:21 am

Checked by



Assessed by Jimmy Chen
Printed on 07/12/2018 at 10:21 am

Checked by

Reason Stent
Outcome Patent, Calcified

Right

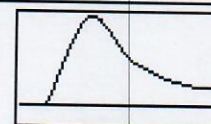
120 1.00

Left

Brachial

Common Femoral

Slightly Reduced

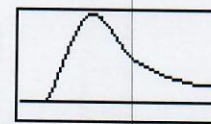


High Thigh

Low Thigh

Popliteal

Slightly Reduced




High Calf

Peroneal

Anterior Tibial


Slightly Reduced



Posterior Tibial

Slightly Reduced

110 0.92



Dorsalis Pedis

Toe Pressure

Post Exercise

Notes

LEFT LOWER LIMB ARTERIAL DUPLEX ASSESSMENT - PREVIOUS CFA-SFA STENT.

Abdominal aorta is patent with monophasic waveforms and PSV 84cm/s. The abdominal aorta appears of normal calibre (maximum AP = 1.68cm), with no evidence of focal dilatation or aneurysm identified.

CIA - patent with monophasic waveforms, PSV 121cm/s.

EIA - patent with monophasic waveforms, PSV 165cm/s.

CFA - stent appears patent with monophasic waveforms, PSV 127cm/s.

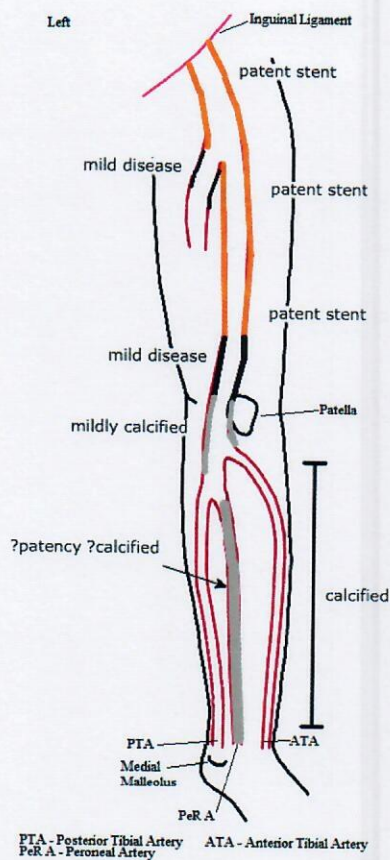
Assessed by Jimmy Chen

Printed on 07/12/2018 at 10:23 am

Checked by

PFA (origin) - patent with mild disease, monophasic waveforms. Elevated velocities obtained however no obvious evidence of significant stenosis/disease identified, PSV 301cm/s.
 SFA - stent appears patent along length with monophasic waveforms, PSV 164- 117cm/s. Distal vessel is patent with mild disease, monophasic waveforms, PSV 241cm/s.
 PopA - patent and mildly calcified, monophasic waveforms, PSV 144cm/s.
 TPT - patent and calcified, evidence of 2x vessel run off identified.
 ATA and PTA - patent and calcified, monophasic waveforms, PSV 88cm/s and 111cm/s respectively.
 PerA - no flow identified ?patency ?calcified.

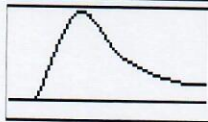
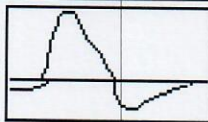

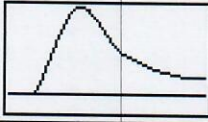



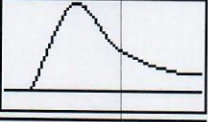
Resting ABPI is significantly reduced in the right and within normal limits in the left lower limb .



Assessed by Jimmy Chen
 Printed on 07/12/2018 at 10:23 am

Checked by

Reason Routine
 Outcome Occlusion, Calcified, Poor images, Stenosis Severe

Right		Left
 <div>135 1.00</div> <div>Slightly Reduced</div>	Brachial	
 <div>Reduced</div>	Common Femoral	
	High Thigh	
	Low Thigh	
	Popliteal	<div>Reduced</div>
	High Calf	
	Peroneal	
 <div>Weak</div>	Anterior Tibial	
 <div>Reduced</div> <div>50 0.37</div>	Posterior Tibial	 <div>Slightly Reduced</div> <div>120 0.89</div>
	Dorsalis Pedis	
	Toe Pressure	
	Post Exercise	

Notes

BILATERAL LOWER LIMB ARTERIAL DUPLEX ASSESSMENT

Abdominal aorta is patent with slightly reduced triphasic waveforms and 87PSV cm/s. The abdominal aorta appears of normal calibre (maximum AP = 1.71cm), with no evidence of focal dilatation or aneurysm identified.

RIGHT

CIA - patent with mild dense disease, monophasic waveforms, PSV 85cm/s.

EIA - prox-mid vessel is patent with severe diffuse disease extending for a length of ~1.78cm. Turbulent

Assessed by Jimmy Chen

Printed on 07/12/2018 at 10:24 am

Checked by

monophasic waveforms, PSV 552cm/s. Distal vessel is patent with mild/mod disease, monophasic waveforms, PSV 160cm/s.

CFA - patent with mild disease, monophasic waveforms, PSV 136cm/s.

PFA (origin) - patent with mild disease, monophasic waveforms, PSV 153cm/s.

SFA - patent at origin with pre-occlusive waveforms, PSV 68cm/s. Distal to the origin, vessel is occluded from 68cm (prox to MM) and reforms at 50cm (prox to MM) with reduced monophasic waveforms, PSV 20cm/s. A focal severe stenosis identified at 48cm (prox to MM), with velocities increasing from PSV 20cm/s to 172cm/s - stenosis extends for a length of ~0.74cm. Distal vessel is patent and calcified, monophasic waveforms, PSV 68cm/s.

PopA - patent and calcified, monophasic waveforms, PSV 41cm/s.

TPT - patent and calcified, evidence of at least 2x vessel run off identified.

ATA and PTA - heavily calcified, however patent at ankle with monophasic waveforms, PSV 14cm/s and 45cm/s, respectively.

LEFT

CIA - patent with mild dense disease, biphasic waveforms, PSV 172cm/s.

EIA - patent with mild dense disease, biphasic waveforms, PSV 318cm/s.

CFA - patent with mild disease, biphasic waveforms, PSV 202cm/s.

PFA (origin) - patent with mild disease, biphasic waveforms, PSV 187cm/s.

SFA - patent with mild, dense and calcified disease in the prox-mid vessel with biphasic waveforms, PSV 232-205cm/s. A focal severe stenosis identified in the mid-distal vessel at 55cm (prox to MM), with turbulent bi/triphasic waveforms, PSV 371cm/s - stenosis extends for a length of ~1.24cm. Distal to the stenosis, vessel is patent and calcified, monophasic waveforms, PSV 90cm/s.

PopA - patent and calcified, monophasic waveforms, PSV 54cm/s.

TPT - patent and calcified, evidence of at least 2x vessel run off identified.

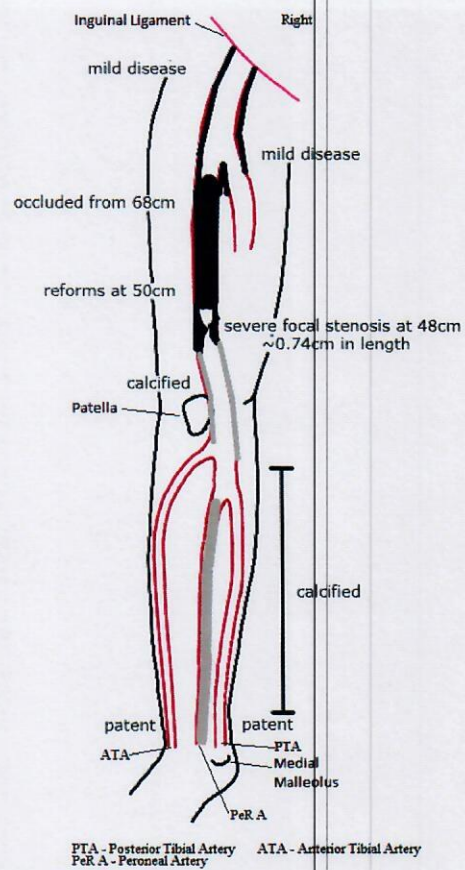
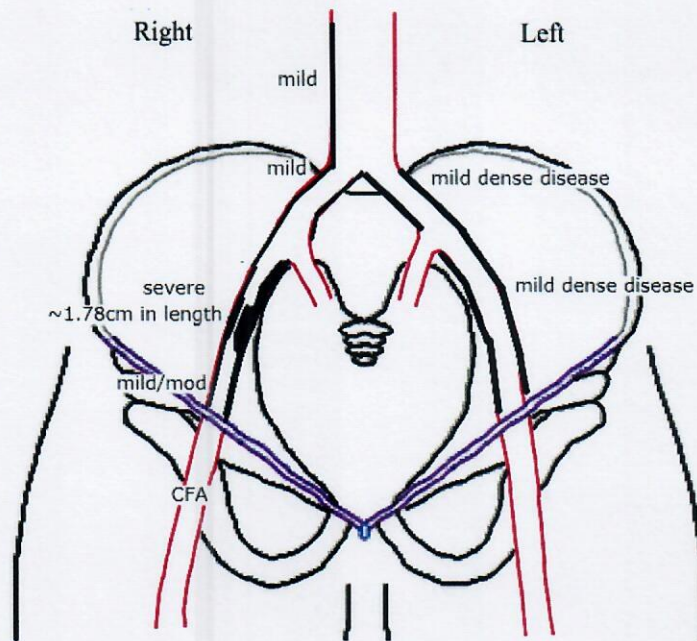
ATA and PTA - heavily calcified, however patent at the ankle, monophasic waveforms, PSV 60cm/s and 134cm/s, respectively.

Resting ABPI is significantly reduced in the right and within normal limits in the left lower limb.

Assessed by Jimmy Chen

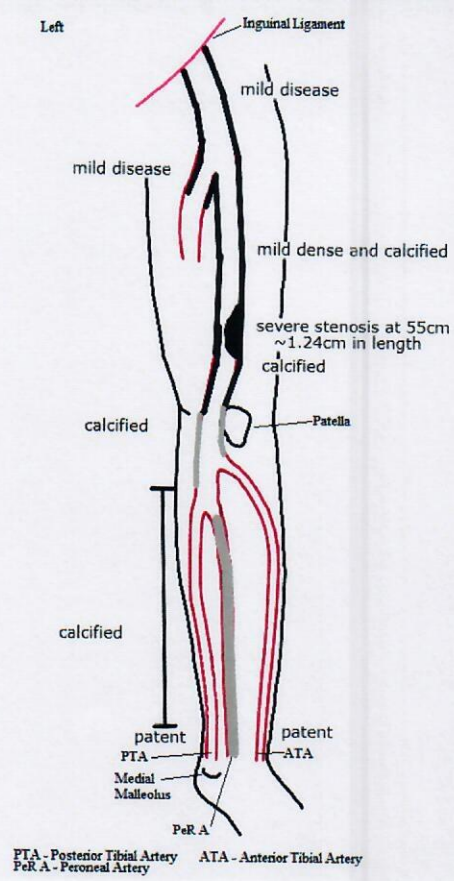
Printed on 07/12/2018 at 10:24 am

Checked by



Assessed by Jimmy Chen
 Printed on 07/12/2018 at 10:24 am

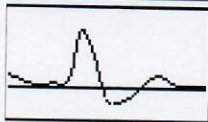
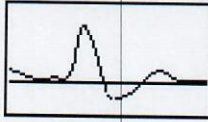




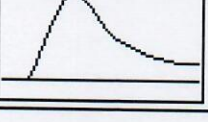

Checked by



Assessed by Jimmy Chen
Printed on 07/12/2018 at 10:24 am

Checked by

Reason Rest pain
Outcome Obscured, Poor images, Patent, Calcified

Right		Left
 130 1.00 Good	Brachial	 Good
	Common Femoral	
	High Thigh	
	Low Thigh	
 Good	Popliteal	 Good
	High Calf	
	Peroneal	
 Good	Anterior Tibial	 Reduced
 Good 160 1.23	Posterior Tibial	 Good 150 1.15
	Dorsalis Pedis	
	Toe Pressure	
Foot Flex 160 1.23	Post Exercise	Foot Flex 140 1.08

Notes

BILATERAL LOWER LIMB ARTERIAL DUPLEX ASSESSMENT

Where seen, abdominal aorta is patent with mild calcified disease. triphasic waveforms and PSV 70cm/s. The abdominal aorta appears of slightly ectatic (maximum AP TS = 2.2cm), with no evidence of focal dilatation or aneurysm identified.

RIGHT

CIA - prox vessel is patent with bi/triphasic waveforms, PSV 101cm/s. Mid-distal vessel not adequately visualised due to overlying bowel gas.

Assessed by Jimmy Chen

Printed on 07/12/2018 at 10:26 am

Checked by

EIA -prox-mid vessel not visualised due to overlying bowel gas. Distal vessel is patent with triphasic waveforms, PSV 101cm/s.

CFA - patent with triphasic waveforms, PSV 91cm/s.

PFA (origin) - patent with triphasic waveforms, PSV 114cm/s.

SFA - patent in the prox vessel with triphasic waveforms, PSV 114cm/s. Waveforms become monophasic in the mid-distal vessel with no evidence of significant disease identified. PSV 76- 117cm/s. Vessel becomes calcified in the adductor canal.

PopA - patent and calcified with monophasic waveforms, PSV 85-96cm/s.

TPT - calcified with evidence of 2x vessel run off identified.

ATA and PTA - calcified, however patent with monophasic waveforms, PSV 43cm/s and 127cm/s, respectively.

PerA - no flow identified ?calcified.

LEFT

CIA - prox vessel is patent with biphasic waveforms, PSV 92cm/s. Mid-distal vessel not adequately visualised due to overlying bowel gas.

EIA -prox-mid vessel not visualised due to overlying bowel gas. Distal vessel is patent with triphasic waveforms, PSV 127cm/s.

CFA - patent with triphasic waveforms, PSV 166cm/s.

PFA (origin) - patent with triphasic waveforms, PSV 55cm/s.

SFA - patent with monophasic waveforms, no evidence of significant disease identified along length. PSV 87-162-126cm/s. Vessel becomes calcified in the adductor canal.

PopA - patent and calcified with monophasic waveforms, PSV 105-98cm/s.

TPT - calcified with evidence of 2x vessel run off identified.

ATA and PTA - calcified, however patent with monophasic waveforms, PSV 29cm/s and 115cm/s, respectively.

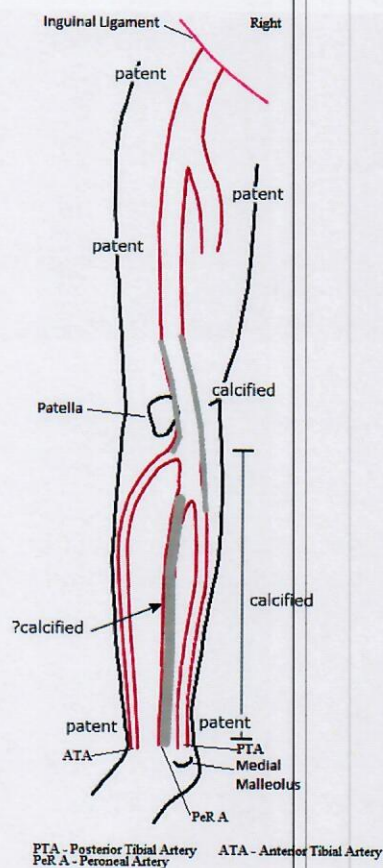
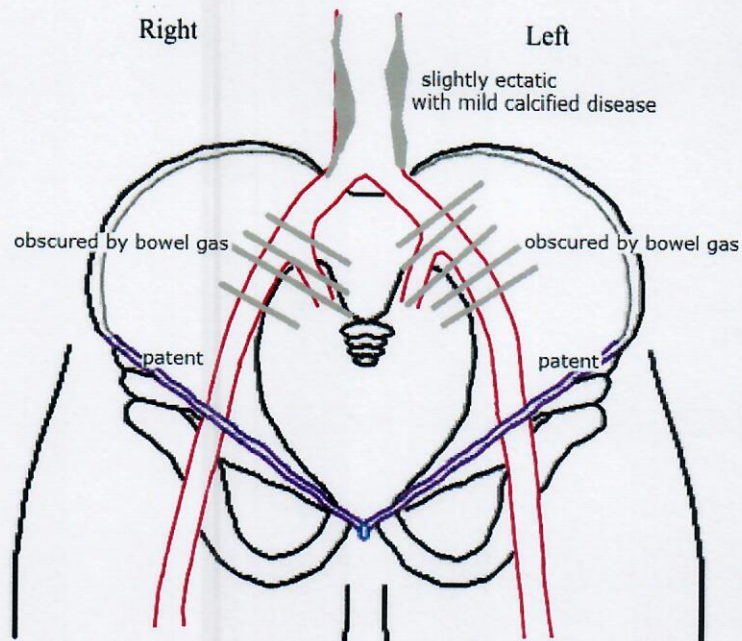
PerA - no flow identified ?calcified.

Resting right and left ABPI are within normal limits and remains so following a 1 minute foot-flex exercise challenge.

Assessed by Jimmy Chen

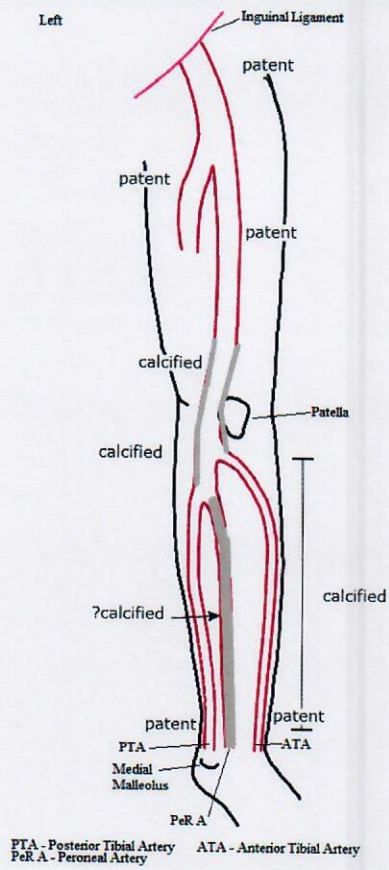
Printed on 07/12/2018 at 10:26 am

Checked by



Assessed by Jimmy Chen
 Printed on 07/12/2018 at 10:26 am

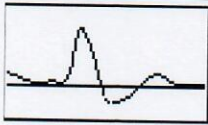







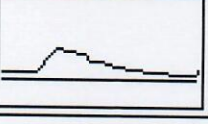

Checked by



Assessed by Jimmy Chen
Printed on 07/12/2018 at 10:26 am

Checked by

Reason Ulceration
Outcome Obscured, Calcified, Poor images, patient habitus

Right		Left
 <div>1601.00</div> <div>Good</div>	Brachial	 <div>Good</div>
 <div>Slightly Reduced</div>	Common Femoral	 <div>Good</div>
 <div>Absent</div>	High Thigh	 <div>Absent</div>
 <div>Absent</div>	Low Thigh	 <div>Absent</div>
 <div>Reduced</div> <div>2401.50</div>	Popliteal	 <div>Reduced</div> <div>2401.50</div>
	High Calf	
	Peroneal	
	Anterior Tibial	
	Posterior Tibial	
	Dorsalis Pedis	
	Toe Pressure	
	Post Exercise	

Notes

BILATERAL LOWER LIMB ARTERIAL DUPLEX SCAN – Scanned in clinic

*challenging scan with sub-optimal images obtained due to patient habitus, patient discomfort, poor mobility and heavily calcification.

Aorta – not visualised due to associated vessel depth.

RIGHT

CIA – not visualised due to associated vessel depth.

Assessed by Jimmy Chen

Printed on 07/12/2018 at 10:30 am

Checked by

EIA – prox-mid vessel not visualised due to associated vessel depth and patient discomfort. Patent in the distal vessel with good triphasic flow, PSV 103cm/s.
CFA – Patent with mild dense and calcified disease, triphasic flow, PSV 139cm/s.
PFA (origin) – patent with biphasic flow, PSV 116cm/s.
SFA – patent in the prox-mid vessel with dense and calcified disease, tri-biphasic waveforms, PSV 116-76cm/s. No flow identified in the distal vessel/adductor canal ?due to heavy calcification.
POP – Prox vessel poorly visualised - unable to exclude significant stenosis/disease from these images. Distal vessel is patent and calcified with mono/triphasic waveforms, PSV 57-64cm/s.
TPT – calcified, evidence of at least 1 vessel run off identified.
ATA – no flow identified ?patency ?calcified.
PTA – heavily calcified, however patent in the mid calf with monophasic waveforms, PSV 47cm/s.
PerA – no flow identified ?patency ?calcified.

LEFT

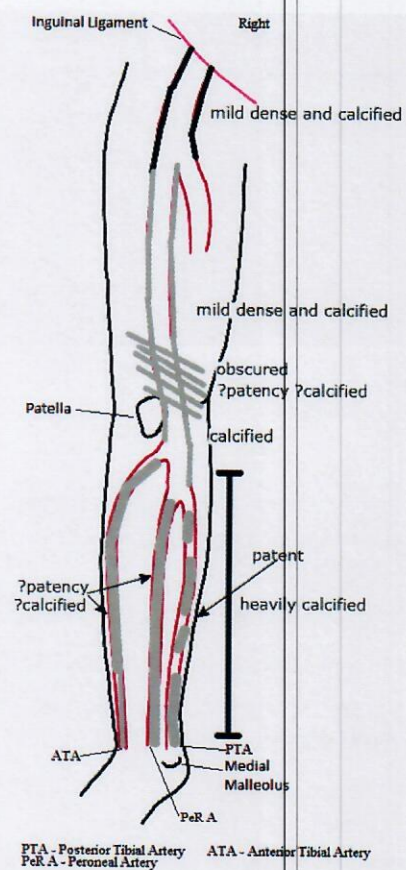
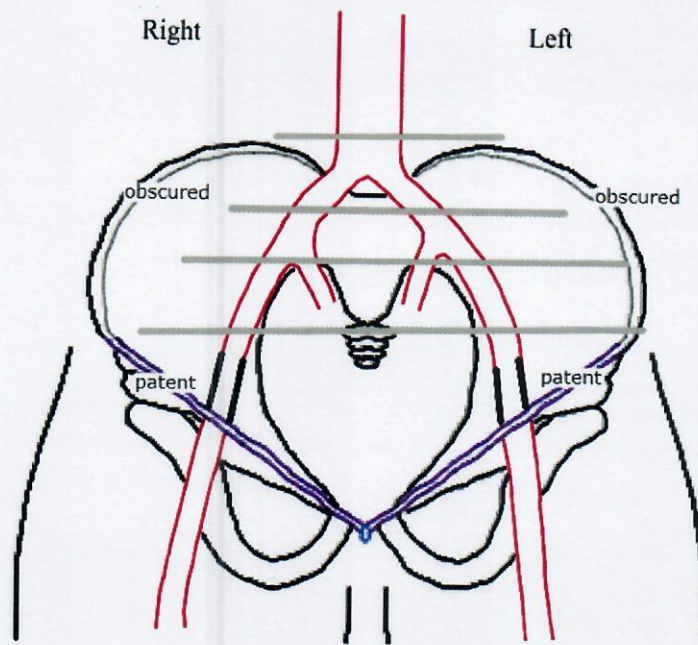
CIA – not visualised due to associated vessel depth.
EIA – prox-mid vessel not visualised due to associated vessel depth and patient discomfort. Patent in the distal vessel with good triphasic flow, PSV 116cm/s.
CFA – Patent with mild dense and calcified disease, triphasic flow, PSV 114cm/s.
PFA (origin) – patent with biphasic flow, PSV 72cm/s.
SFA – patent in the prox vessel with dense and calcified disease, triphasic waveforms, PSV 88cm/s.
Multiple obscured areas in the mid-distal vessel due to extensive calcification, where seen vessel is patent with mono/triphasic waveforms, PSV 112-80cm/s - unable to fully exclude significant stenosis/disease within obscured areas.
POP – patent and calcified with triphasic waveforms, PSV 63cm/s.
TPT – calcified ?patency
ATA – no flow identified ?patency ?calcified.
PTA – no flow identified, however reduced monophasic waveforms obtained using HHD.
PerA – no flow identified ?patency ?calcified.

Resting right and left ABPI are falsely elevated due to calcified crural vessels .

Assessed by Jimmy Chen

Printed on 07/12/2018 at 10:30 am

Checked by



Assessed by Jimmy Chen
 Printed on 07/12/2018 at 10:30 am

Checked by

