


<b>Vascular Studies Unit</b>  <b>VSU Protocol: Lower limb Arterial Duplex Scan</b>  <b>RRCV</b>	University Hospitals of Leicester  NHS Trust  <b>VSU Reference Number: 012</b>
---	--

<b>Approved By:</b>	<b>Matt Bown, Head of Vascular Service</b>
<b>Date Implemented:</b>	<b>Sept 2022</b>
<b>Version:</b>	<b>V6</b>
<b>Supersedes:</b>	<b>V5 Jan 2021</b>
<b>Author / Originator(s):</b>	<b>Jo Walker, Chief Clinical Vascular Scientist Sophie McDermott, Clinical Vascular Scientist</b>
<b>Reviewed by:</b>	<b>VSU Clinical Scientist Working Group</b>
<b>Next Review Date:</b>	<b>Sept 2024</b>

Abbreviations	
EIA	External iliac artery
CIA	Common iliac artery
DP	Dorsalis Pedis
TPT	Tibio-peroneal trunk
SFA	Superficial femoral artery
PFA	profunda femoris/femoral artery
ATA	Anterior tibial artery
PTA	Posterior tibial artery
CFA	Common femoral artery
COPD	chronic obstructive pulmonary disease
PSV	peak systolic velocity

Changes Made	By	Date
Review, removed generic equipment & safety section, now separate doc	JW	April 2016
Planned Review, Updated indications/contraindications list, aligned with SVT protocol	All / JW	Sept 2019
Reformatting & planned review	PK	Jan 2021

Updated the popliteal artery entrapment scan section	JW	Nov 2021
Added extending scope of scan	JW	Sept 2022

## **VSU Protocol: Lower Limb Arterial Duplex Scan**

### **Purpose**

The scan is performed on patients to ascertain the presence and site of stenotic or occlusive lesions affecting the lower limb arteries. These lesions can reduce blood flow to the foot and muscle compartments, additionally thrombus collected within aneurysmal dilatations may act as an embolic source. Additionally, a scan may be performed to assess for popliteal entrapment – see Appendix 1.

Duplex scanning allows imaging of all or some of the lower limb vessels from the aorta to the ankle. The colour facility enables patency of the vessels to be determined and highlights areas of velocity increase. The Doppler facility is used to estimate percentage stenosis and to determine a range of flow-limiting or flow-enhancing states.

### **Common indications**

- Claudication
- Rest Pain/Critical limb Ischemia
- Ulceration/tissue loss/gangrene
- Surveillance following intervention
- Popliteal Entrapment
- Suspected aneurysmal disease, both native and as a result of intervention
- To exclude arterial disease where compression dressings are being considered

### **Contraindications and Limitations**

Contraindications for arterial duplex ultrasound are few; however, some limitations exist and these may include the following:

- Patients with high body mass index
- The presence of ulcers, wounds, bandaging or casts and for patients who have had recent surgery, ultrasound visualization may be limited due to oedema, haematoma, surgical staples, dressings
- Calcified plaque may cause acoustic shadowing limiting Doppler and B-mode image assessment
- Patients who are unable to lie with their limbs flat or still due to extreme pain or pre-existing co-morbidities e.g. chronic obstructive pulmonary disease (COPD) and arthritis – although these patients may be able to tolerate being examined seated with the limb dependent or with the head of the bed raised where practical.
- Patients who are unable to cooperate due to reduced cognitive functions e.g. Alzheimer's or dementia and through involuntary movements

- Examinations undertaken portably at the patient's bedside maybe limited due to equipment and room dimensions
- The presence of catheters or vascular access lines which limit visualization of the
- Vessels

### **Communication with patients**

The patient must be capable of lying still during the scan and where appropriate, an ability to lie flat will assist greatly in visualisation of the aorto-iliac segment. It is explained that the test is carried out to look at the leg arteries in order to identify any blockages or narrowings that may be contributing to their symptoms. The patient is reassured that the test is painless and advised of the approximate duration of the scan. Verify that the requested procedure correlates with the patient's clinical presentation.

### **Equipment**

Duplex Doppler ultrasound machine with high, medium & low-range frequency probes.



## Test Procedure

Select an appropriate frequency transducer, considering vessel depth and body habitus. For lower limb assessments, evaluation of the following arteries should be included, as appropriate:

- Aorta\*
- Common iliac artery (CIA)\*
- External iliac artery (EIA)\*
- Common femoral artery (CFA)
- Proximal profunda femoris artery (PFA)
- Superficial femoral artery (SFA)
- Popliteal artery\*\*
- Tibio-peroneal trunk (TPT)
- Posterior tibial artery (PTA)
- Peroneal artery
- Anterior tibial artery (ATA)
- Dorsalis Pedis (DP)
- Plantar artery

\*Demonstration of a sharp upstroke and a biphasic/triphasic signal usually rules out the necessity to scan the iliac vessels. The aorto-iliac segment is usually only scanned when a damped signal (a visualized increased systolic rise time) is identified in the CFA. However, Vascular Scientists should consider that younger patients may still demonstrate a triphasic CFA waveform in the presence of a significant iliac stenosis, therefore the aorto-iliac segment may need to be scanned.

\*\*If an incidental popliteal aneurysm is found, then the contralateral distal SFA and popliteal artery must also be scanned, along with an Abdominal aorta aneurysm screening scan (please see separate detailed protocol and charts).

It is required, where possible, to perform a full assessment of at least 2 tibial vessels.

The following appropriate techniques should be used to evaluate the lower arterial systems:

- B-mode should be used to image the artery and assess for, aneurysmal dilation and vessel contents e.g. atheromatous plaque
- Colour Doppler should be used to assess for the presence/absence of flow and aid the position of spectral Doppler when quantifying stenoses.
- Pulsed wave or spectral Doppler should be used to determine the direction or absence of flow, and measure the velocity of flow to enable assessment of stenoses/occlusions.

Any areas where the colour flow Doppler appears disturbed should always be interrogated with pulsed Doppler. The highest peak systolic velocity should be measured at the site of the disturbance or narrowing (Vs) and in a normal area of the artery just proximal to the narrowing (Vp). Care should be taken to ensure that the Doppler angle is 60° or less in line with flow, when recording velocity measurements. The scan should aim to determine patency, stenoses, diffuse disease and aneurysmal dilatations with a view to producing a site-specific, representative map. As a minimum, velocities and waveforms should be recorded in each of the vessel segments.

### **Extending the scope of the scan**

At the decision of the person performing the scan, the scope or extent of investigation can be expanded to include additional information which benefits patient safety or aid likely ongoing management or intervention. For example this may include vein mapping for patients presenting with critical limb ischaemia (CLI) who may require urgent bypass (especially relevant with acute appearance of occlusions) and aneurysm screening of aorta and contralateral limbs for situations where arterial aneurysms are incidentally discovered. Rarely an outpatient may present with new onset bilateral CLI or gangrene and the request may be for a unilateral assessment based on older presentation, and it would be relevant to perform a bilateral assessment at this time to expedite urgent treatment.

## Interpretation and grading of disease

The main criterion used to grade the degree of narrowing in the artery is the ratio of  $V_s$  to  $V_p$ , known as the peak systolic velocity (PSV) ratio. The PSV ratio is used to grade the severity of the narrowing. A PSV ratio of  $>2$  is generally used to define a stenosis that is causing a greater than 50% reduction in the diameter of the artery. A PSV ratio of  $>4$  is generally used to define a stenosis that is causing a greater than 75% reduction in the diameter of the artery. Historically in the VSU a  $\geq 3$  ratio is flagged as significant in a lower limb vein bypass grafts.

Changes in the shape of Doppler waveforms are important criteria in determining the presence of disease. Multiphasic waveforms are representative of normal flow, whereas monophasic/damped waveforms usually represent diseased flow.

Comment should be made on the heterogenicity and appearance of the arterial disease (such as highlighting acute thrombus or embolus, versus established atheroma, and significant calcification).

Diameter Reduction	Velocity Ratio ( $V_s/V_p$ )	Comments
0 – 49%	$<2$	Triphasic, mild spectral broadening and increase in EDV recorded as degree of narrowing approaches
50 – 74%	$\geq 2$	Bi- or monophasic waveform Some increase in EDV Spectral broadening +/- flow disturbance Some damping distally
75 – 99%	$\geq 4$	Usually monophasic Significant increase in EDV Marked turbulence + spectral broadening Damped flow distally
Occluded	No flow detected	High resistance flow proximally

Ref: Thrush & Hartshorne, Peripheral Vascular Ultrasound: How, Why, When (Second Edition) 2005

N.B. In the single visit clinic setting limited investigations may be carried out as per clinical requirements.

## Reporting of Results

The report is a recording and interpretation of observations made during the arterial duplex ultrasound examination; it should be written by the person undertaking the examination and viewed as an integral part of the whole examination. The report should include correct patient demographics; date of examination; examination type and the name and status of the person reporting the examination.

The report consists of a schematic diagram, and should include:

- An indication of which arteries have been assessed commenting on the presence/absence of flow, as appropriate
- The anatomical position and length of any occlusions or stenosis
- The anatomical position and size of any aneurysms
- Any limitations of the assessment e.g. due to body habitus/calcified vessels/ bowel gas
- Comments on the shape of the Doppler waveform at different locations

In the presence of an SFA occlusion it is helpful to the Radiologists to know whether a stump of patent vessel is identifiable proximally and whether any thrombus present appears fresh. Where no disease is noted, a reference velocity and waveform is noted in each vessel segment imaged.

Patients are not given a formal report by the Clinical Vascular Scientist at the time of attending for their scan but are informed that the report will be forwarded to the referring consultant. However, a verbal report may be given at the discretion of the Clinical Vascular Scientist.

The report should be signed by the operator carrying out the test. Where a computer generated reporting system is used, the locally agreed verification and authorization procedure should be followed. The report should be written as soon as possible following the assessment.

### Red Flags:

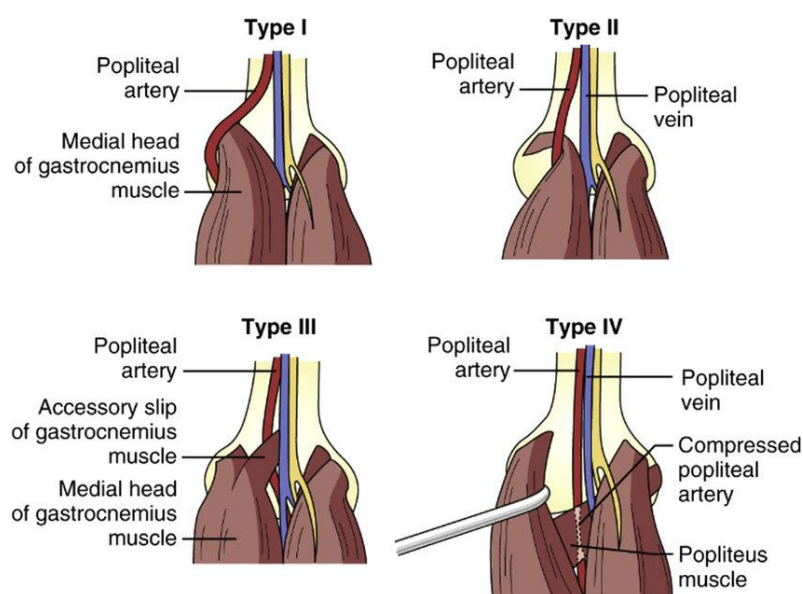
Any urgent findings, should be brought to the attention of the referring clinician immediately, and noted on the report.

- New Onset critical ischaemia
- Rest Pain
- Significant decline in symptoms since referral
- Large aneurysm
- Graft significant findings
- Clinical significant incidental findings or concerns (eg. new DVT)

## Popliteal Artery Entrapment Syndrome

### Introduction

Popliteal artery entrapment syndrome (PAES) is a rare condition which is most prevalent amongst young males. The patient presents with symptoms of claudication but with no apparent reduction in foot pulses at rest. Note patients may have a normal resting ABPI, however may demonstrate a pressure drop post exercise ABPI. Entrapment of the artery is assumed to result from intermittent intrinsic compression of the artery during exercise. Several anatomical and physiological variations have been described in PAES and are summarised as the four types listed below:



Ref: [Journal of Vascular Surgery Cases and Innovative Techniques](#) 3(4):232-235 · December 2017

### Scanning Technique

The patient is positioned prone with the ankle supported to introduce minor knee flexion. The feet should slightly overhang the couch to facilitate movement. Using an appropriate probe selection, the popliteal artery should be located and checked throughout its length for patency, stenosis, aneurysm, adventitial cysts and wall disease. The ankle is actively plantar flexed without resistance and external compression of the artery is checked. The mid and distal portions of the artery should be checked for entrapment during active plantar flexion with particular attention to the vessel at the level of the tibial condyle. The assessment is repeated where the Clinical Vascular Scientist or assistant adds resistance to the plantar flexion with manual pressure on the sole of the foot. Finally the patient is assessed in the erect standing position whilst plantar flexing by standing on toes, and then repositioning and adding further pressure through the leg by repositioning into a split stance position with weight bearing through the rear leg being assessed. Repeated plantar flexion until

the patient is symptomatic may be required to demonstrate the occlusion. Both leg pain and occlusion of the popliteal artery are required for a positive diagnosis of PAES. During all forms of provocation, the popliteal artery must be assessed from just above the knee joint (common location for gastrocnemius muscle compression) to below the knee joint (common location for plantaris muscle compression). If anterior leg symptoms are described, the proximal segment of the anterior tibial artery should also be assessed.

## Reporting of Results

The report should indicate patency or percentage occlusion of the vessel at rest and on independent forced and resisted plantar flexion. The site of findings should be noted.

Also some effort should be made to describe the degree of force required to produce entrapment. Where appropriate, reports of a positive result should include a statement recognising the potential for such changes to be demonstrated in normal subjects (see below).

## Discussion

Care should be taken in the interpretation of results. Studies have shown that 50-60% of normal subjects are able to affect popliteal artery occlusion during resisted plantar flexion and an 85% false positive rate has been reported when stenotic and pre-occlusive changes are included. It has been suggested that these asymptomatic subjects are demonstrating physiological PAES, the muscular hypertrophy variant. Subjects demonstrating high resistance/pre-occlusive waveforms in the distal popliteal may also be ascribed to the hypertrophy category.

In view of the poor specificity of vascular ultrasound in the diagnosis of PAES other, additional imaging techniques are performed. These include angiography and MRI to determine aberrations in the course of the popliteal artery and variations in the muscular anatomy.

## **Supporting References**

- NICE Guidelines (CG147) Aug 2012, Peripheral Arterial Disease: Diagnosis and Management
- Allard. L. *et al*, (1999). 'Review of the assessment of single level and multilevel arterial occlusive disease in lower limbs by duplex ultrasound'. Ultrasound in Medicine and Biology. 25(4): 495-502.
- Hatsukhami. T. *et al*. (1992). Colour Doppler Characteristics in Normal Lower Extremity Arteries. Ultrasound in Medicine and Biology. 18(2): 167-171.
- Lunt. Ni. (1999). Review of duplex and colour Doppler imaging of lower-limb arteries and veins. Journal of Tissue Viability. 9(2): 45-55.
- Sensier. Y. Bell. P.. London. N. (1998). 'The ability of qualitative assessment of the common femoral Doppler waveform to screen for significant aortoiliac disease'. European Journal of Vascular and Endovascular Surgery. 15(4): 35 7-64.
- Sensier. Y. *et al*. (1996). 'A Prospective Comparison of Lower Limb Colour-coded Duplex Scanning with Arteriography'. European Journal of Vascular and Endovascular Surgery. 11: 170-175.
- Thrush & Hartshorne, Peripheral Vascular Ultrasound: How, Why, When (Second Edition) 2005
- SVT Professional Performance Guidelines: Guidelines for Lower and Upper limb Arterial Duplex assessment, 2019
- Charles Williams, et al, A new diagnostic approach to popliteal artery entrapment syndrome, J Med Radiat Sci. 2015 Sep; 62(3): 226–229.
- Functional Popliteal Artery Entrapment Syndrome: Poorly Understood and Frequently Missed? A Review of Clinical Features, Appropriate Investigations, and Treatment Options (2014) Matthew Hislop, Dominic Kennedy, Brendan Cramp, and Sanjay Dhupelia, Journal of Sports Medicine
- Akkersdyk, W, *et al*, (1995) Colour Duplex Ultrasonographic Imaging and Provocation of Popliteal Artery Compression. European Journal of Vascular and Endovascular Surgery, 10: 342-345.
- Erdoes. L. *et al*. (1994). Popliteal vascular compression in a normal population. Journal of Vascular Surgery. 20(6): 978-986.



- Lambert. A. and Wilkins. D. (1999). Popliteal artery entrapment syndrome, British journal of Surgery, 86: 1365-1370.
- MacSweeney, S. *et al*, (1995). Colour Doppler ultrasonic imaging in the diagnosis of popliteal artery entrapment syndrome' Correspondence in British Journal of Surgery, 82(4): 569-570.
- Stager. A. and Clement. D. (1999). 'Popliteal artery entrapment syndrome.' Sports Medicine. 28(1): 61-70.



Example Report:

**VASCULAR STUDIES UNIT**

University Hospitals of Leicester **NHS**

NHS Trust

Level 6, Balmoral Building  
Leicester Royal Infirmary  
Tel: 0116 258 5440  
Fax: 0116 258 6821

**LOWER LIMB ARTERIAL DUPLEX SCAN REPORT**

Surname: \_\_\_\_\_  
Forename: \_\_\_\_\_  
DOB: \_\_\_\_\_  
Unit Number: \_\_\_\_\_  
(or use patient label)

**Resting ankle pressures**

	DP	PT	Per	BP	Index
Right					
Left					

**Post-exercise pressures**

	DP	PT	Per	BP	Index
Right					
Left					

Time walked: \_\_\_\_\_ mph

Comment:

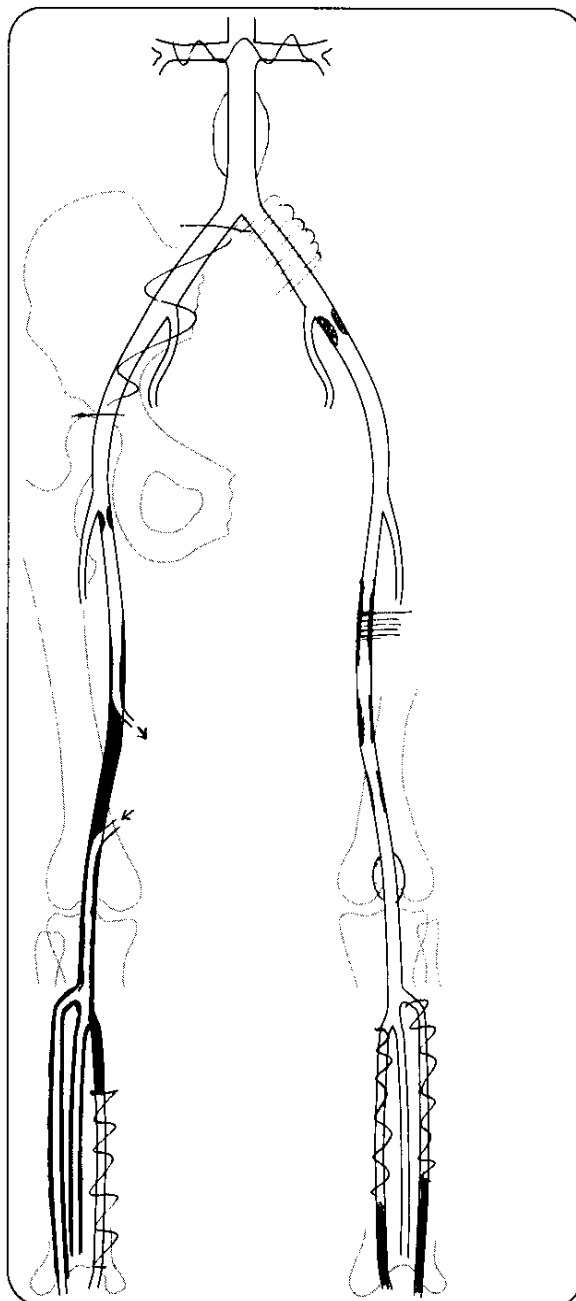
Scan comment:

Image Quality: GOOD ☐ ☐ ☐ POOR

SIGNED: \_\_\_\_\_  
CLINICAL VASCULAR SCIENTIST

PRINT NAME: \_\_\_\_\_

DATE: \_\_\_\_\_



Waker 22277 06 08 04 iw

# Lower Limb Arterial Duplex Scan Report



Referring Consultant: [redacted]

Clinical History: VALS

① foot ulcer

Scan & Report completed by:

Name:

Alex Paim

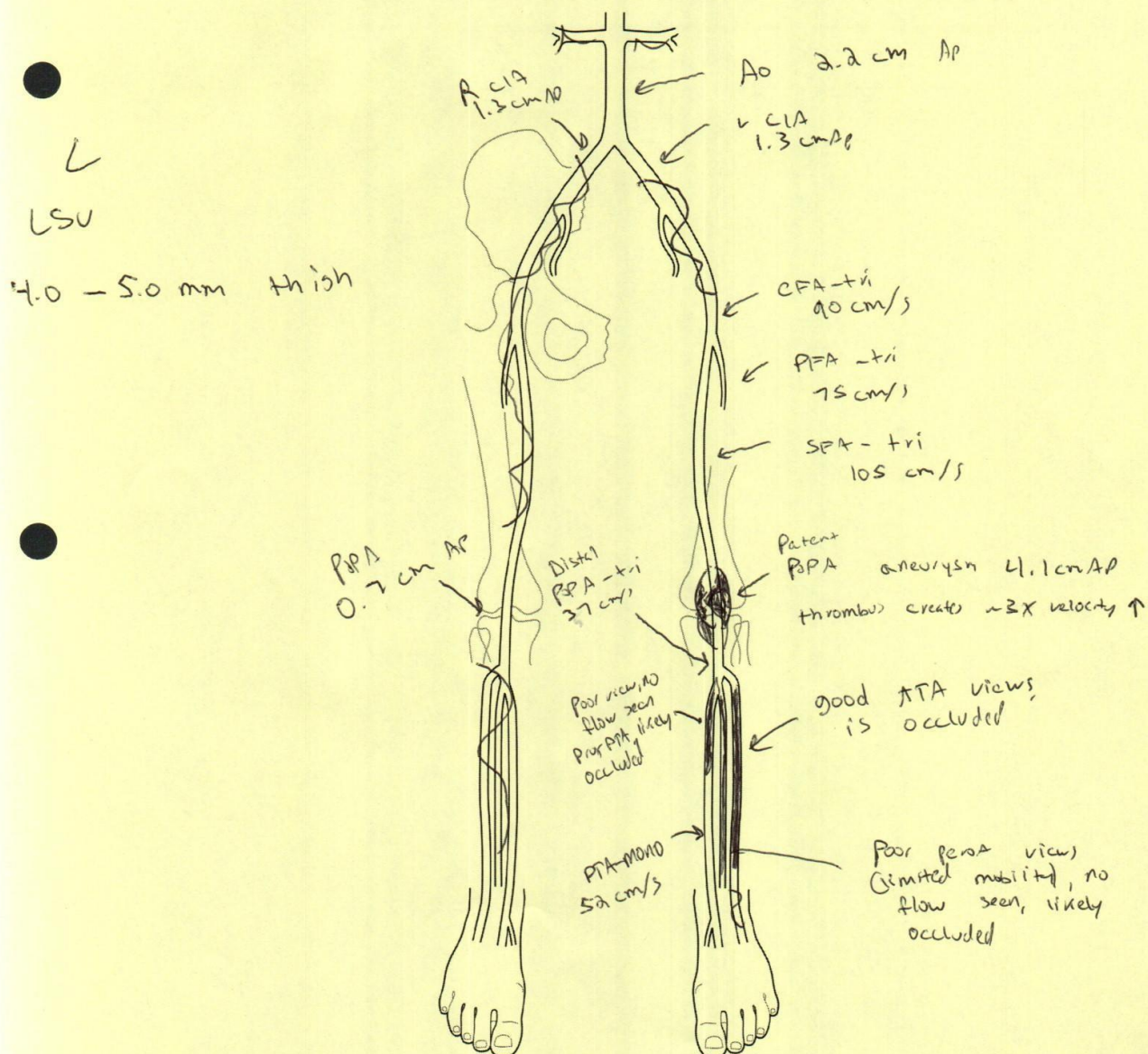
Clinical Vascular Scientist / Technician

Signed:

[Signature]

Date:

24/5/23





## Lower Limb Arterial Duplex Scan Report

Patient Details:



Referring Consultant:

Clinical History:



VALS

no pulse Bk PeL

TP ~ 48 mmHg

Scan & Report completed by:

Name:

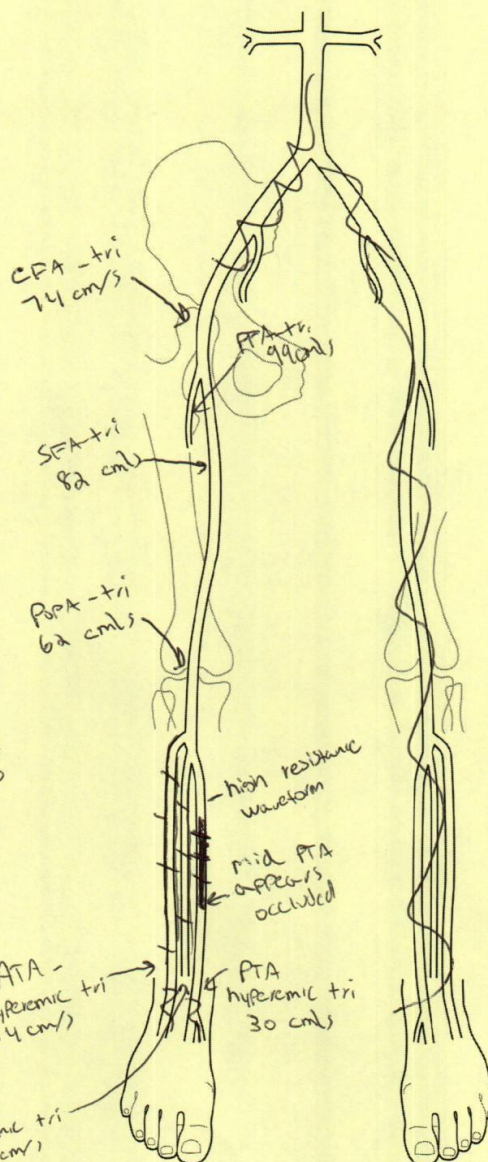
Alex Pason

Clinical Vascular Scientist / Technician

Signed:

Date:

24/05 / 2023



Heavily calcified tibials,  
sub-optimal views due to  
shadowing. Appears to be  
2x vessel runoff





## Lower Limb Arterial Duplex Scan Report



Referring Consultant: *Day*

Clinical History: *VACS*

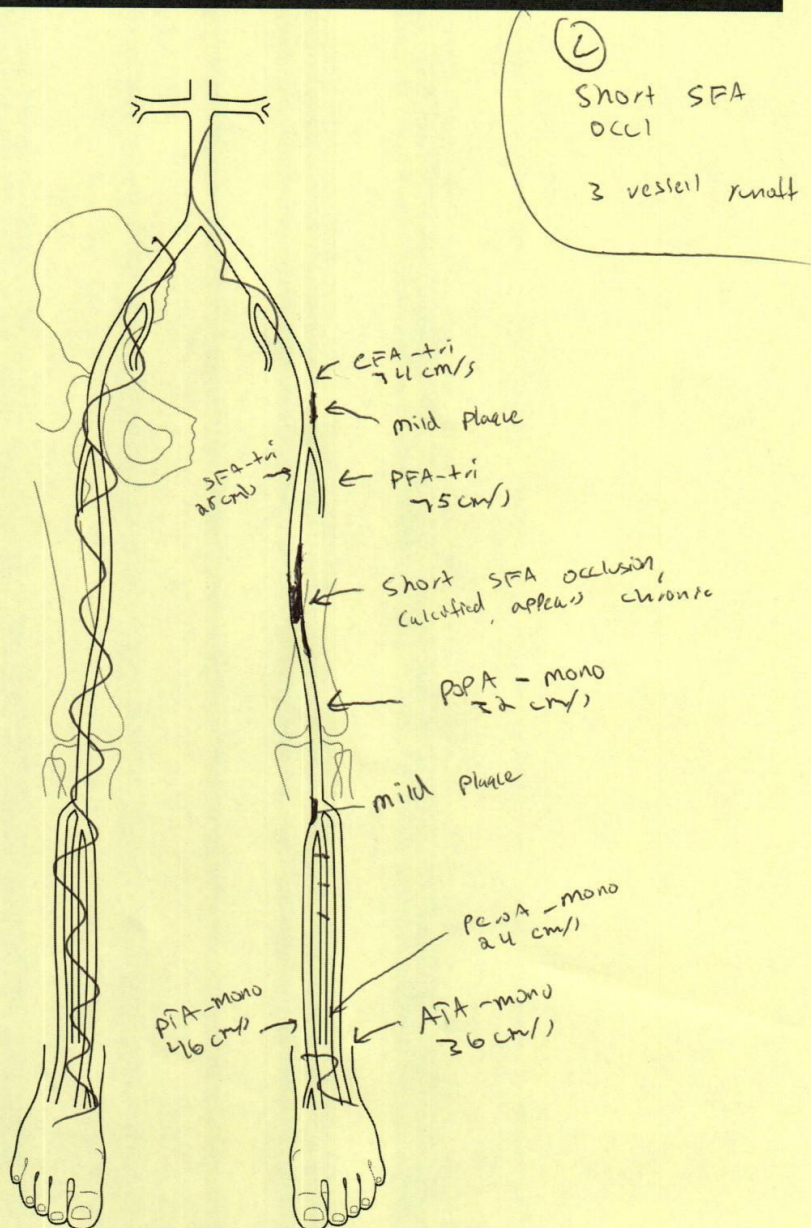
Scan & Report completed by:

Name: *Alex Pason*

Clinical Vascular Scientist / Technician

Signed: *[Signature]*

Date: *24/5/23*





University Hospitals of Leicester  
NHS Trust



LEICESTER  
VASCULAR INSTITUTE  
VASCULAR STUDIES UNIT

## Lower Limb Arterial Duplex Scan Report



Referring Consultant: [redacted]

Clinical History: ulcer



Previous SFA  
Plasty

Scan & Report completed by:

Name:

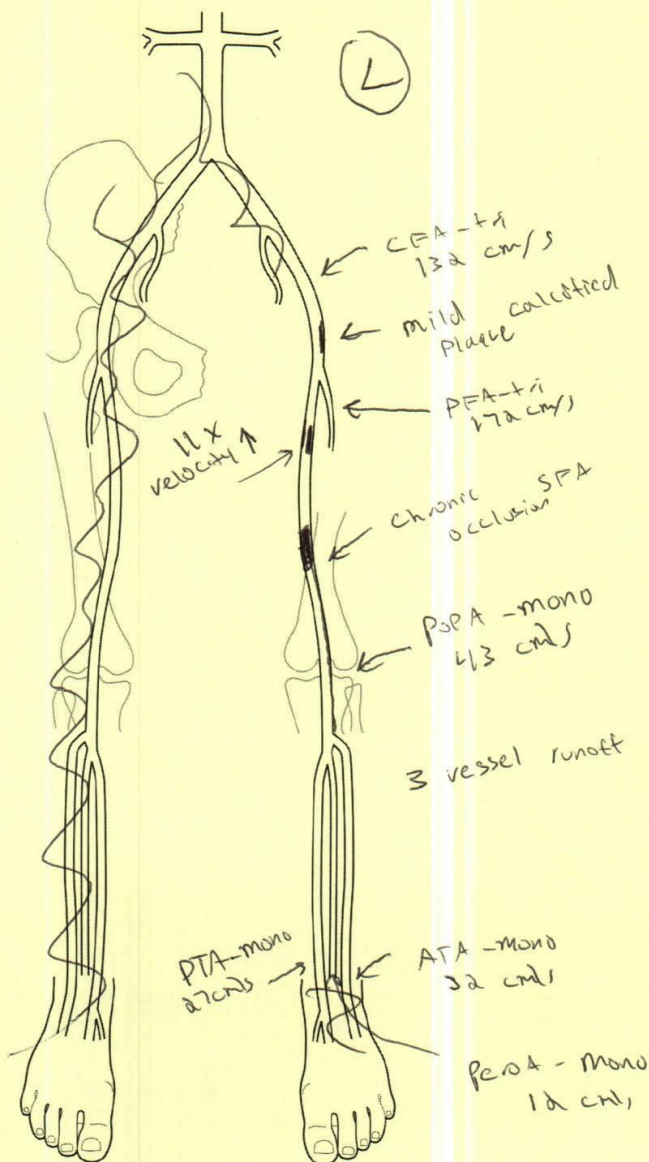
Alex Pason

Clinical Vascular Scientist / Technician

Signed:

Date:

15/05/2023





**Lower Limb Arterial Bypass Graft Duplex Scan Report**

**CENSORED**

Referring Consultant: \_\_\_\_\_

History: low ABPI (L)

g Status: \_\_\_\_\_

tion: \_\_\_\_\_

ms: \_\_\_\_\_

Follow-up: \_\_\_\_\_

an Date: \_\_\_\_\_

Scan & Report completed by: \_\_\_\_\_

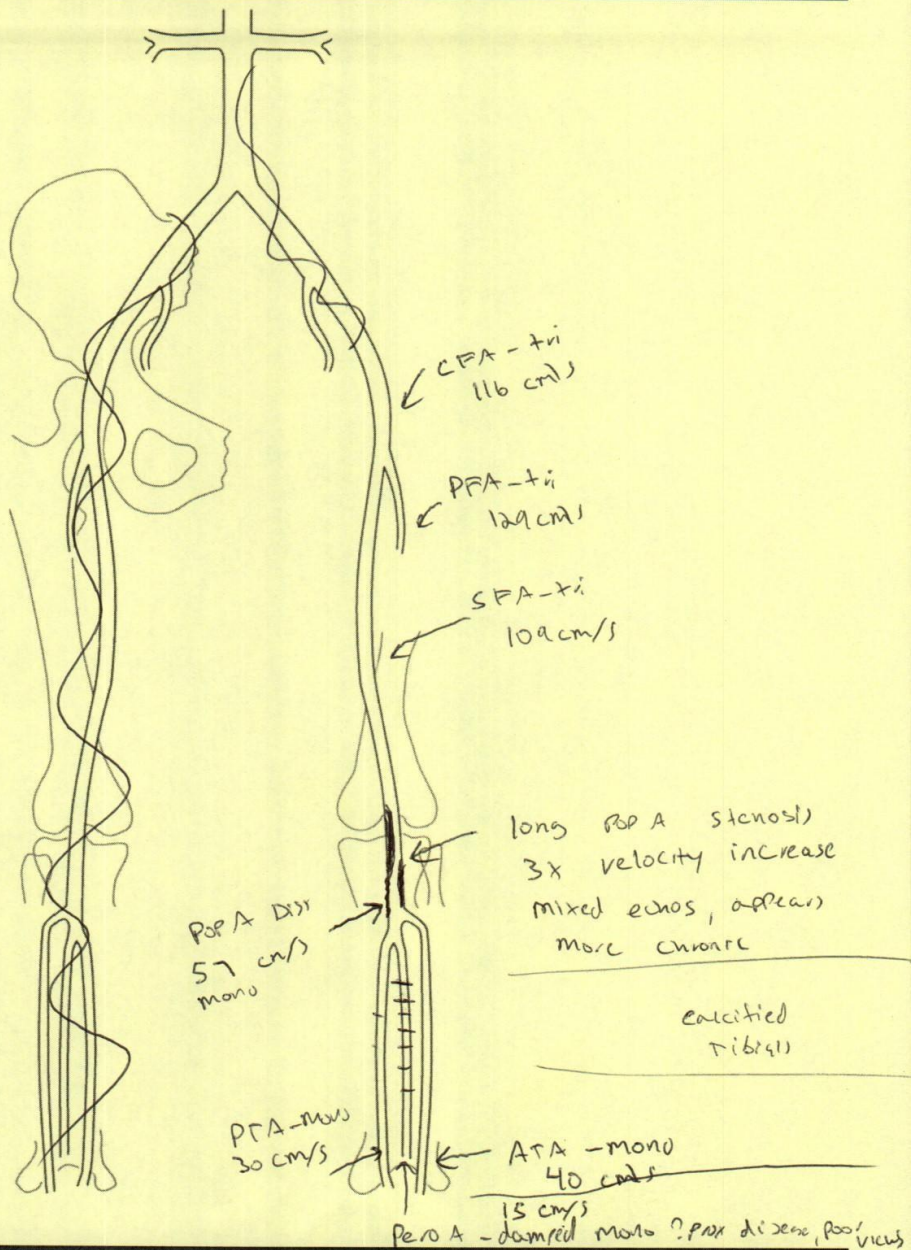
Name: \_\_\_\_\_

Alex Pason

Clinical Vascular Scientist / Technician

Signed: \_\_\_\_\_

Date: 11/5/23







**Lower Limb Arterial Bypass Graft Duplex Scan Report**

**CENSORED**

Referring Consultant: \_\_\_\_\_

Scan & Report completed by: \_\_\_\_\_

Clinical History: \_\_\_\_\_

Name: \_\_\_\_\_

Smoking Status: \_\_\_\_\_

Alex Pasun

Medication: \_\_\_\_\_

Clinical Vascular Scientist / Technician

Symptoms: \_\_\_\_\_

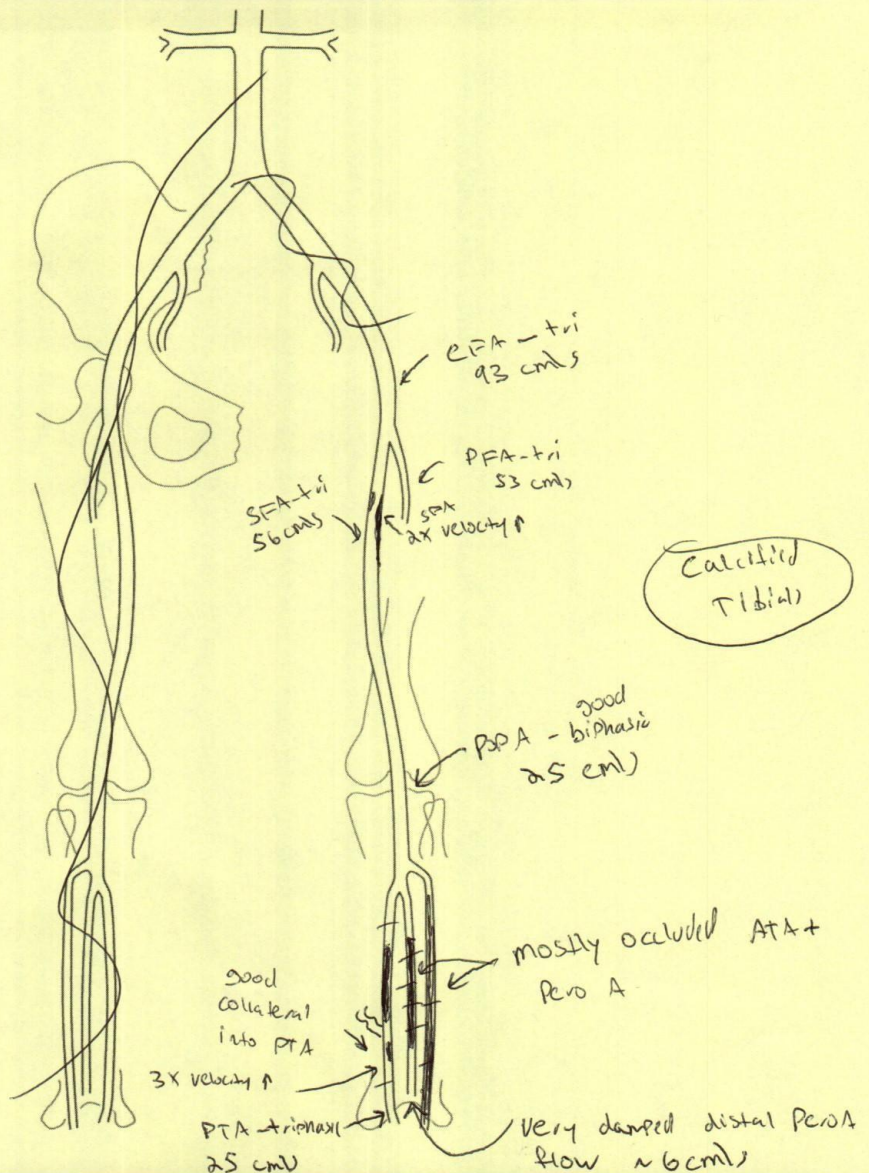
Signed: \_\_\_\_\_

Planned Follow-up: \_\_\_\_\_

Date: \_\_\_\_\_

Next Scan Date: \_\_\_\_\_

11/5/23





# Lower Limb Arterial Duplex Scan Report

**CENSORED**

Referring Consultant: [Redacted]

Clinical History:

Scan & Report completed by:

Name:

Alex Pasun

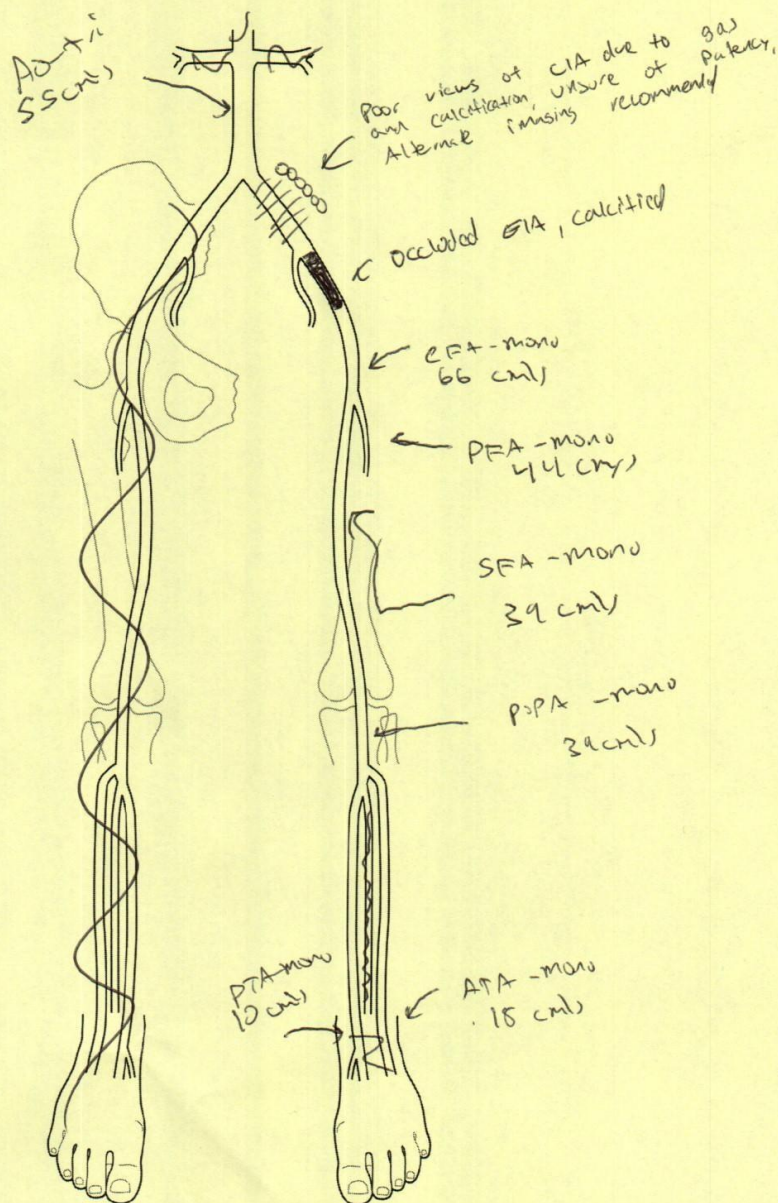
Clinical Vascular Scientist / Technician

Signed:

[Signature]

Date:

11/5/23





# Lower Limb Arterial Duplex Scan Report



Referring Consultant:

Clinical History: (L) previous acute limb isch self-discharge from ward, now in VAS

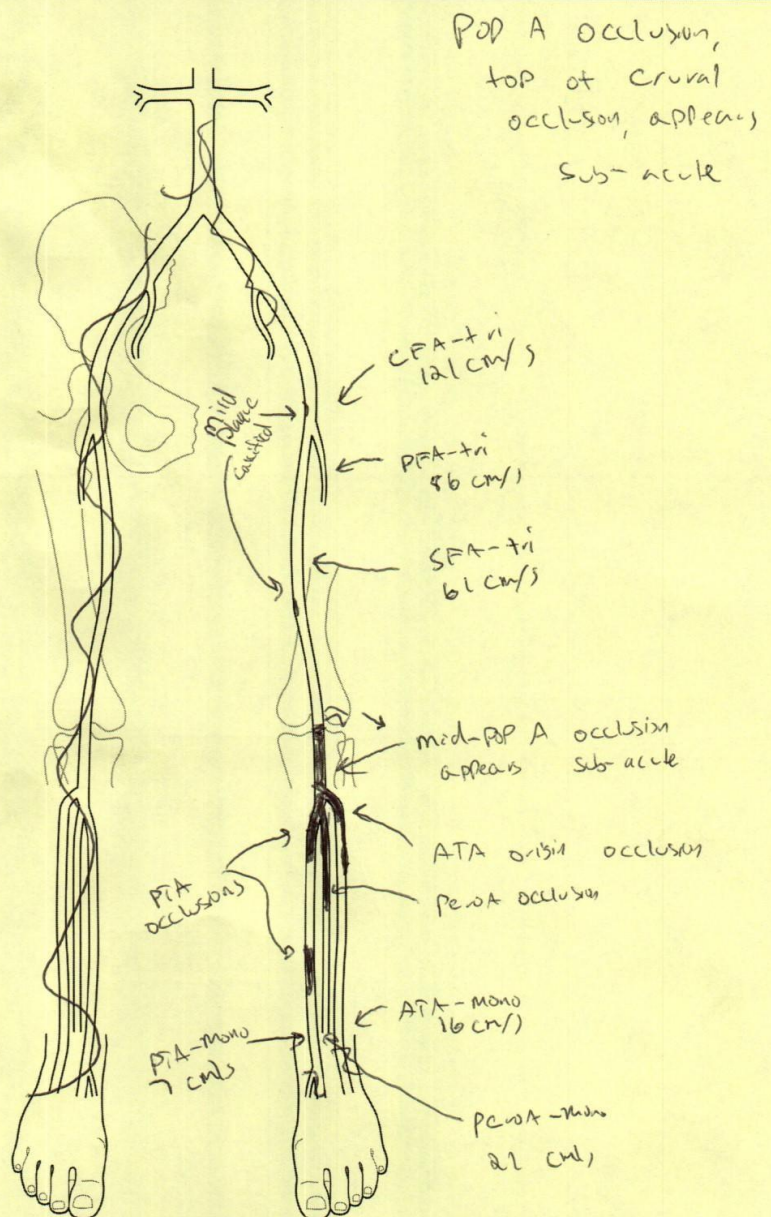
Scan & Report completed by:

Name: Alex Paine

Clinical Vascular Scientist / Technician

Signed: [Signature]

Date: 11/5/23





University Hospitals of Leicester  
NHS Trust



LEICESTER  
VASCULAR INSTITUTE  
VASCULAR STUDIES UNIT

## Lower Limb Arterial Duplex Scan Report

Patient Details:

Referring Consultant:

Scan & Report completed by:

Name:

Alex Pasun

Clinical Vascular Scientist / Technician

Signed:

Date:

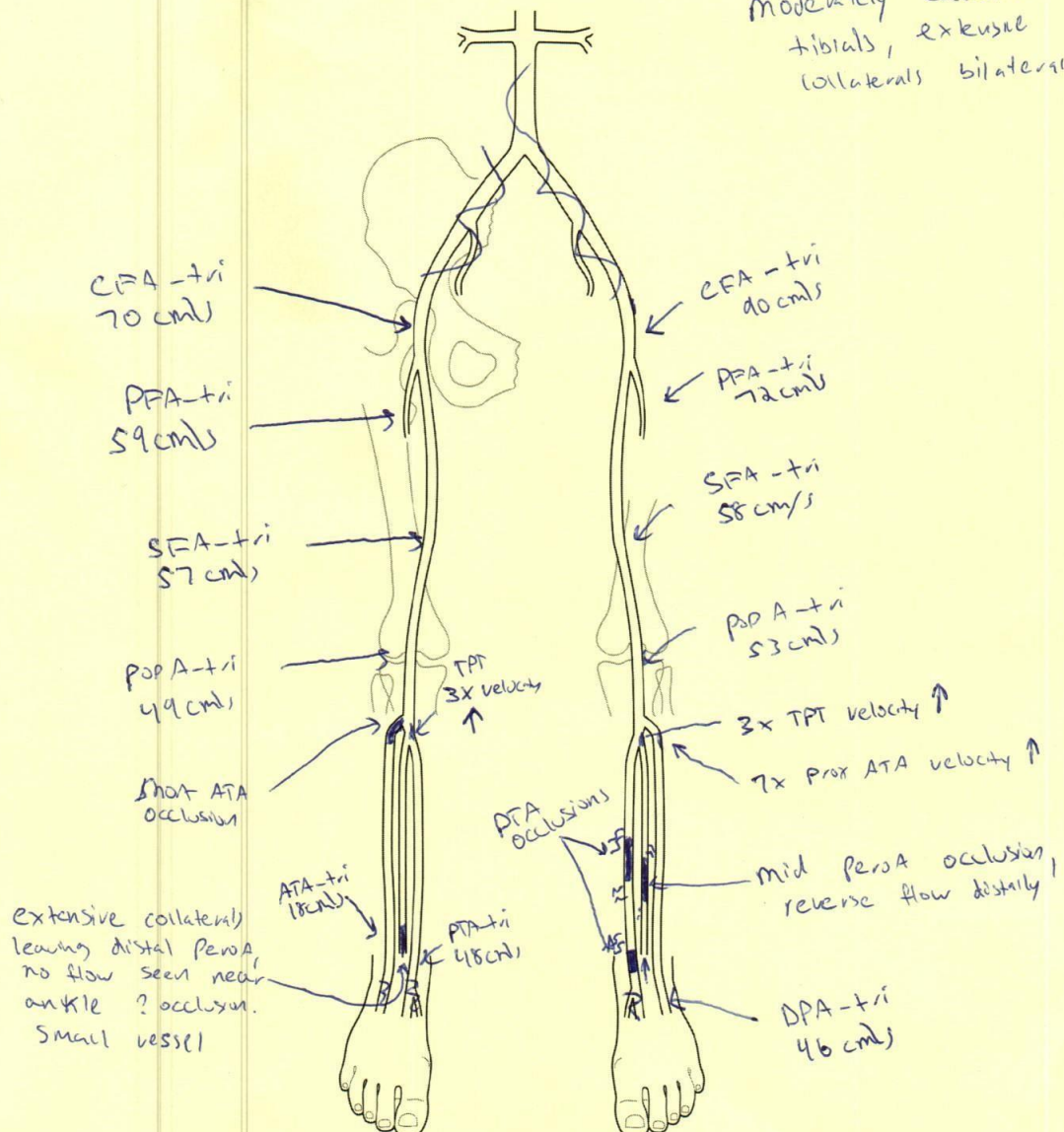
4/5/23

**CENSORED**

Clinical History:

b/l blue feet

moderately calcified  
tibials, exclude  
collaterals bilaterally





## Lower Limb Arterial Duplex Scan Report

Patient Details:

Referring Consultant:

Clinical History:

Scan & Report completed by:

Name:

Alex Parn

Clinical Vascular Scientist / Technician

Signed:

Date: 3-5-23

**CENSORED**

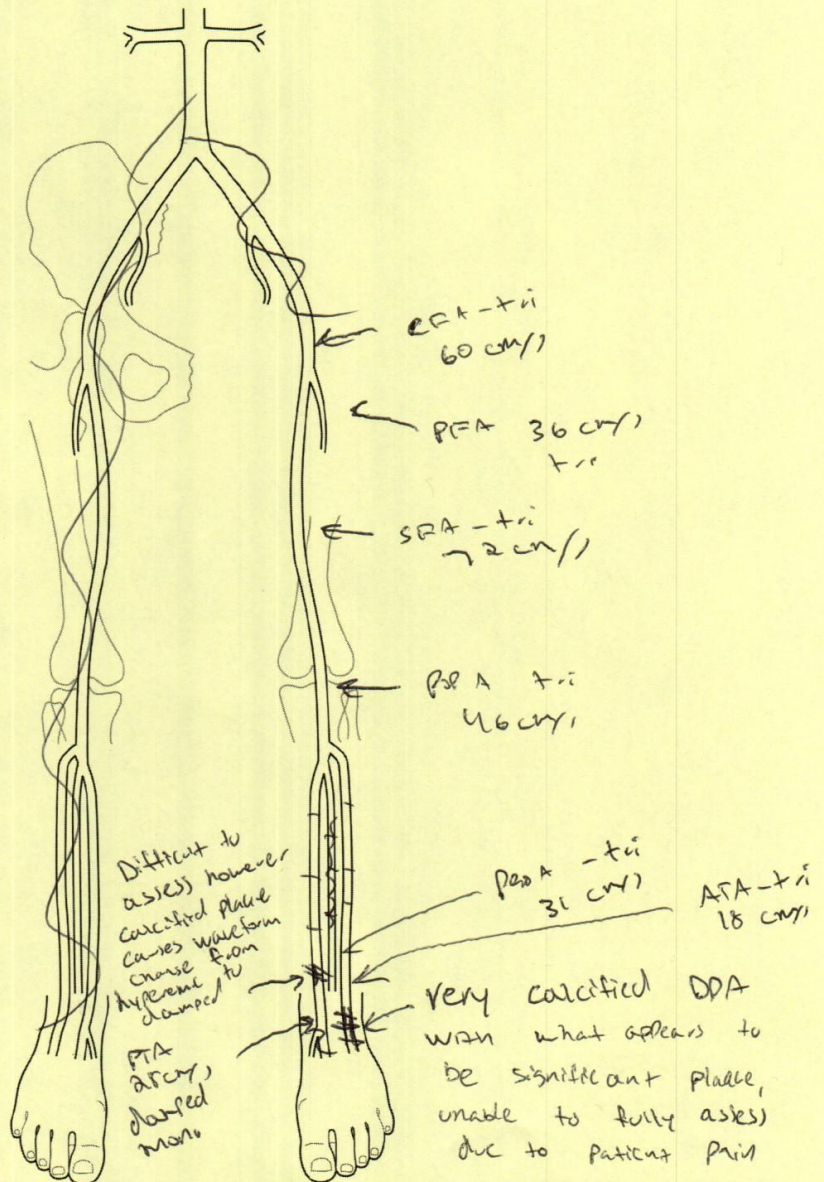
● (1)

Triphasic flow from  
CFA to PPA.

Significant PTA stenosis,  
likely diseased DPA

●

Limited assessment,  
~~poor~~ poor patient tolerability  
due to pain





# Lower Limb Arterial Duplex Scan Report



Referring Consultant: [redacted]

Clinical History:

R heel ulcer

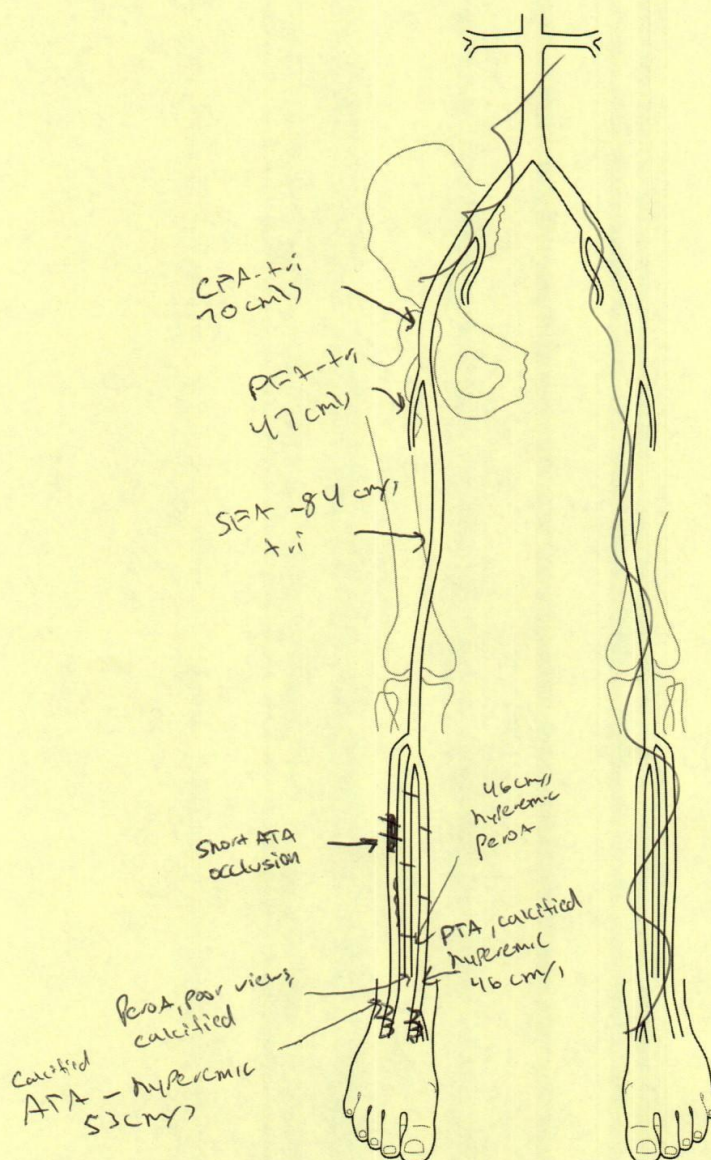
Scan & Report completed by:

Name: Alex Pash

Clinical Scientist / Technician

Signed:

Date: 3-2-23





## Lower Limb Arterial Duplex Scan Report



Consultant:

Ref:

10 toe  
gangrene

Scan & Report completed by:

Name:

Alex Pan

Clinical Vascular Scientist / Technician

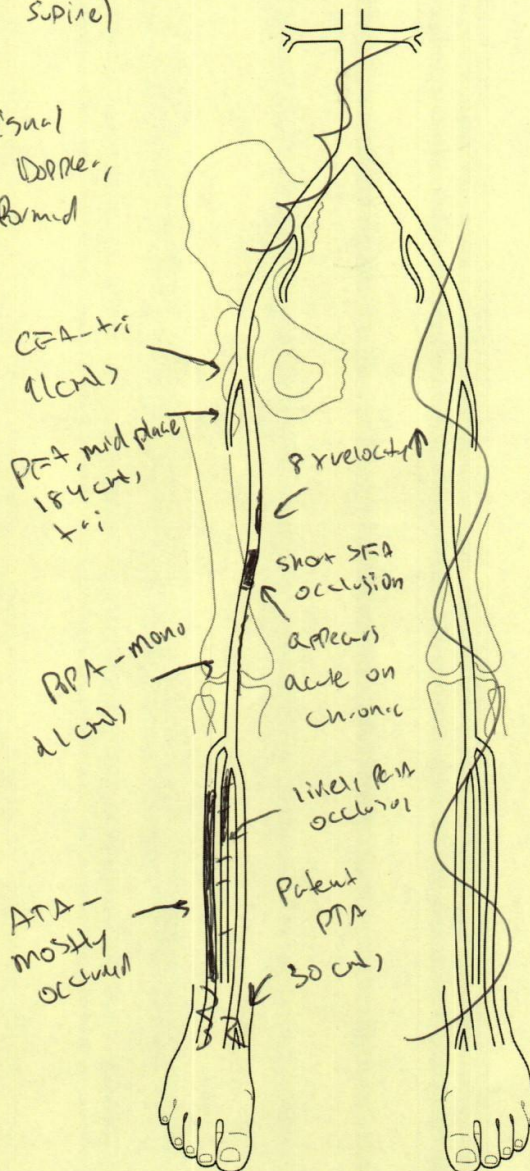
Signed:

[Signature]

Date: 3-5-21

10 CW in thigh 1)  
~20mm (Patient supine)

no PTA or Ato signal  
on handheld CW Doppler,  
ABPI not performed





# VASCULAR STUDIES UNIT

Level 1  
Glenfield Hospital  
Tel: 0116 258 5440

**NHS**

University Hospitals  
of Leicester  
NHS Trust

## LOWER LIMB ARTERIAL DUPLEX SCAN REPORT

**CENSORED**

### Resting ankle pressures

Right	DP	PT	Per	BP	Index
Left	DP	PT	Per		

### Post-exercise pressures

Right	DP	PT	Per	BP	Index
Left	DP	PT	Per		

Time walked \_\_\_\_\_ mph

Comment:

### Scan comment:

Poor views, heavy calcification  
throughout

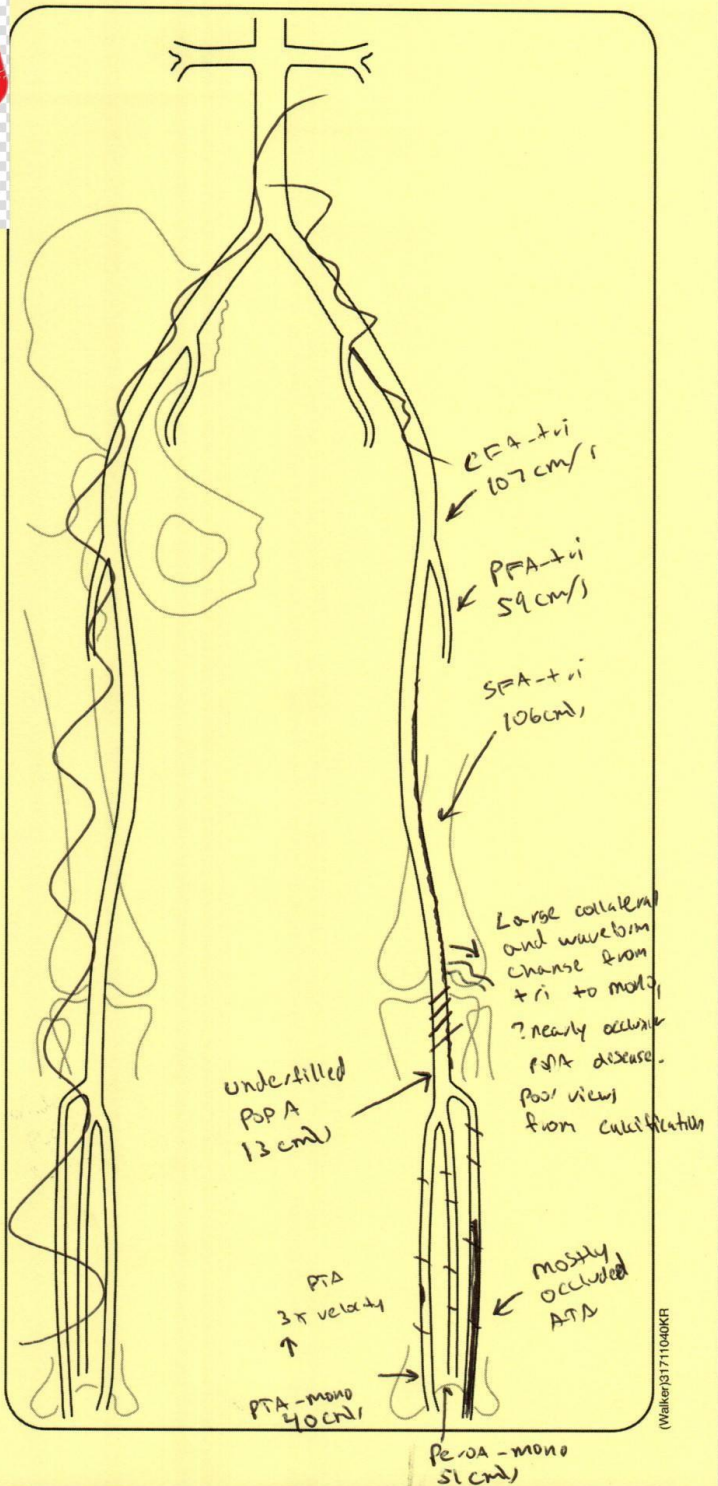
Triphasic inflow,  
Severe ~~PPA~~ disease,  
2x vessel runoff

Image Quality: GOOD ☐ ☐ ☒ POOR

SIGNED: \_\_\_\_\_  
CLINICAL VASCULAR SCIENTIST

PRINT NAME: Alex Paz

DATE: 24/4/13



(Walker)31711040K6

# VASCULAR STUDIES UNIT

Level 1  
Glenfield Hospital  
Tel: 0116 258 5440



University Hospitals  
of Leicester  
NHS Trust

## LOWER LIMB ARTERIAL DUPLEX SCAN REPORT



### Resting ankle pressures

Right	DP	PT	Per	BP	Index
Left	DP	PT	Per		

### Post-exercise pressures

Right	DP	PT	Per	BP	Index
Left	DP	PT	Per		

Time walked \_\_\_\_\_ mph

Comment:

### Scan comment:

Triphasic flow  
throughout  
mid-PTA stenosis

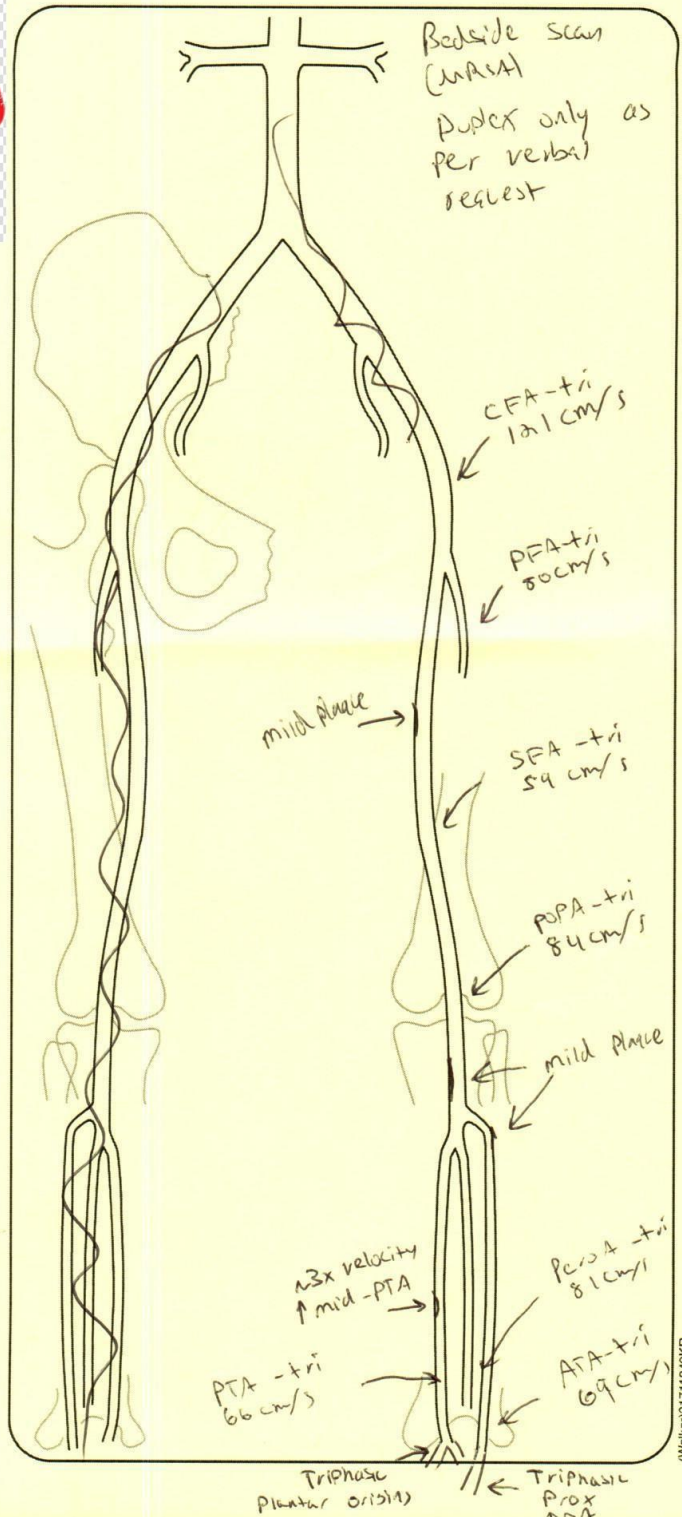
Image Quality: GOOD ☐ ☒ POOR

SIGNED: \_\_\_\_\_

CLINICAL VASCULAR SCIENTIST

PRINT NAME: \_\_\_\_\_

DATE: \_\_\_\_\_



(Walker)3171040KR



# VASCULAR STUDIES UNIT

Level 1  
Glenfield Hospital  
Tel: 0116 258 5440



University Hospitals  
of Leicester  
NHS Trust

## LOWER LIMB ARTERIAL DUPLEX SCAN REPORT



### Resting ankle pressures

Right	DP	PT	Per	BP	Index
Left	DP	PT	Per		

### Post-exercise pressures

Right	DP	PT	Per	BP	Index
Left	DP	PT	Per		

Time walked \_\_\_\_\_ mph

Comment:

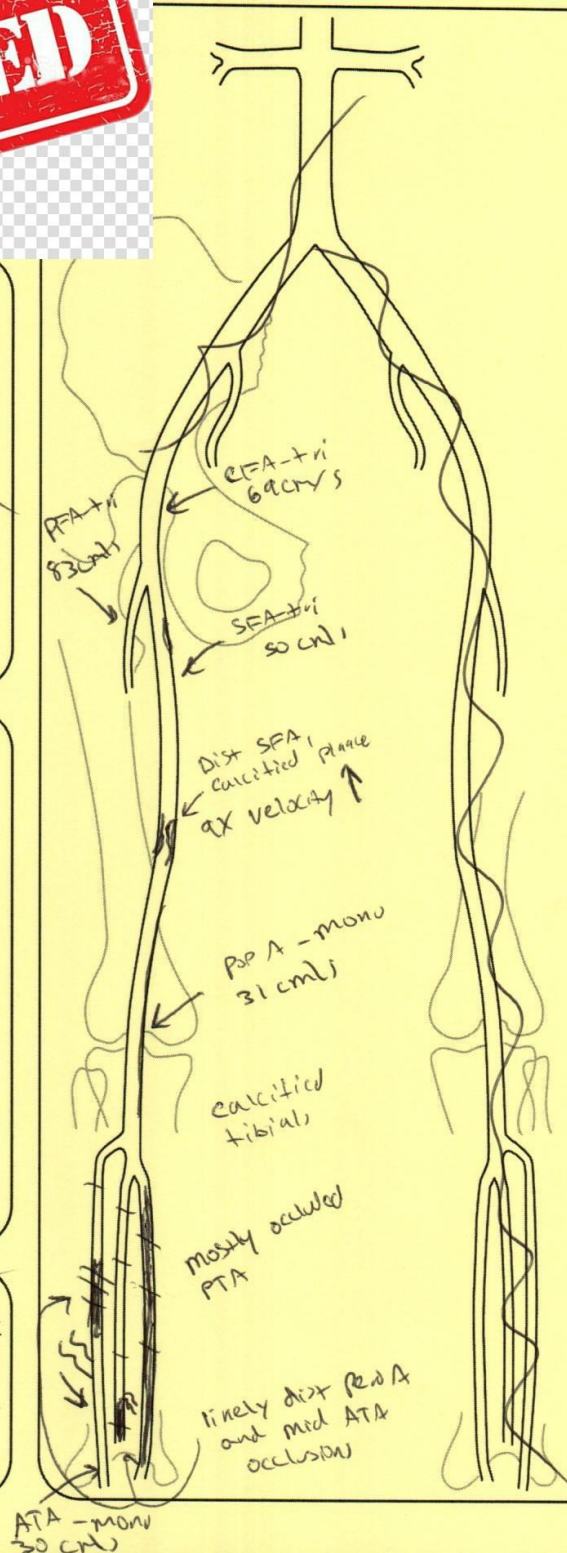
### Scan comment:

Image Quality: GOOD ☐ ☒ POOR ☐

SIGNED:   
CLINICAL VASCULAR SCIENTIST

PRINT NAME: Alex Pasan

DATE: 18/4/23





# VASCULAR STUDIES UNIT

Level 1  
Glenfield Hospital  
Tel: 0116 258 5440



University Hospitals  
of Leicester  
NHS Trust

## LOWER LIMB ARTERIAL DUPLEX SCAN REPORT



### Resting ankle pressures

Right DP PT Per BP Index

Left DP PT Per

### Post-exercise pressures

Right DP PT Per BP Index

Left DP PT Per

Time walked \_\_\_\_\_ mph

Comment:

### Scan comment:

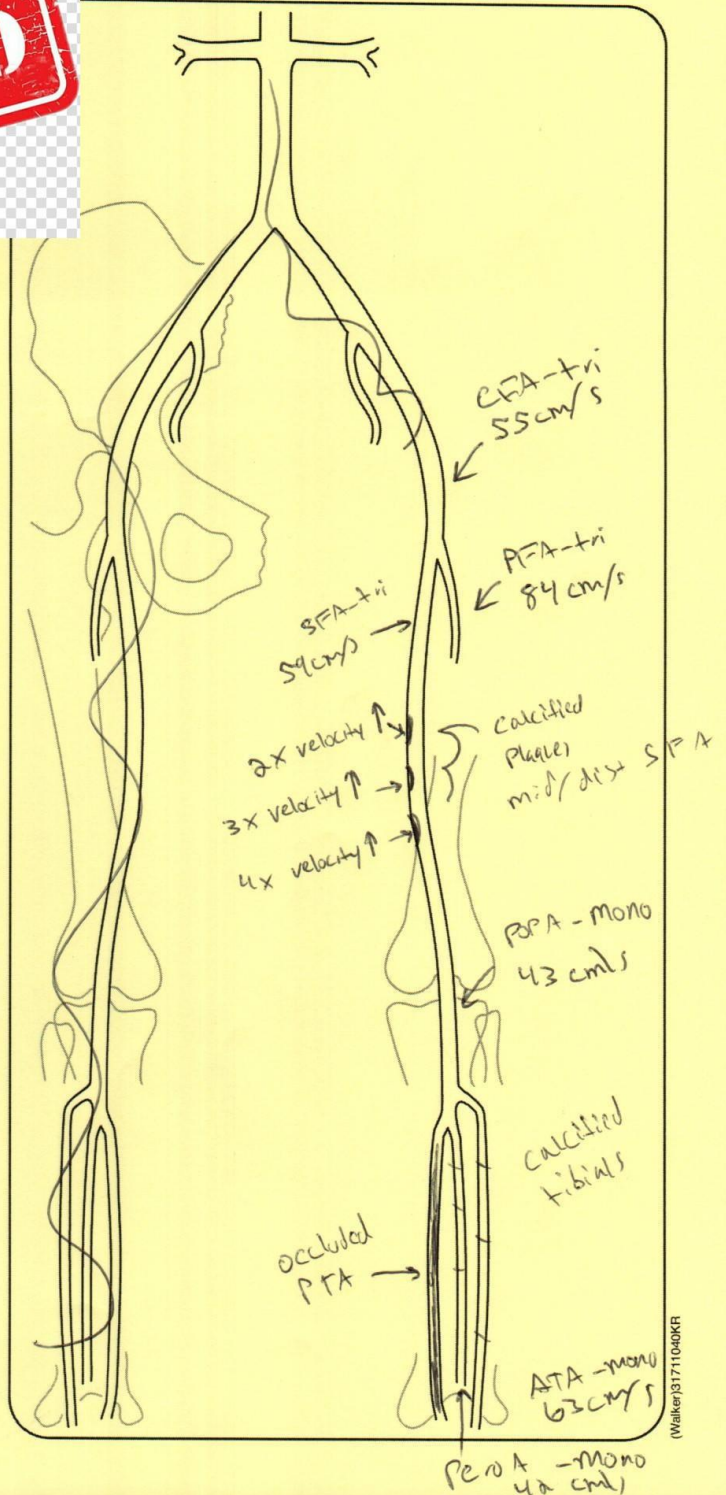
Image Quality: GOOD ☐ ☒ POOR

SIGNED: \_\_\_\_\_

CLINICAL VASCULAR SCIENTIST

PRINT NAME: Alex Pason

DATE: 18/4/23





# VASCULAR STUDIES UNIT

Level 1  
Glenfield Hospital  
Tel: 0116 258 5440

**NHS**

University Hospitals  
of Leicester  
NHS Trust

## LOWER LIMB ARTERIAL DUPLEX SCAN REPORT

**CENSORED**

### Resting ankle pressures

Right	DP	PT	Per	BP	Index
Left	DP	PT	Per		

### Post-exercise pressures

Right	DP	PT	Per	BP	Index
Left	DP	PT	Per		

Time walked \_\_\_\_\_ mph

Comment:

### Scan comment:

(R) Severe CFA  
disease, good result

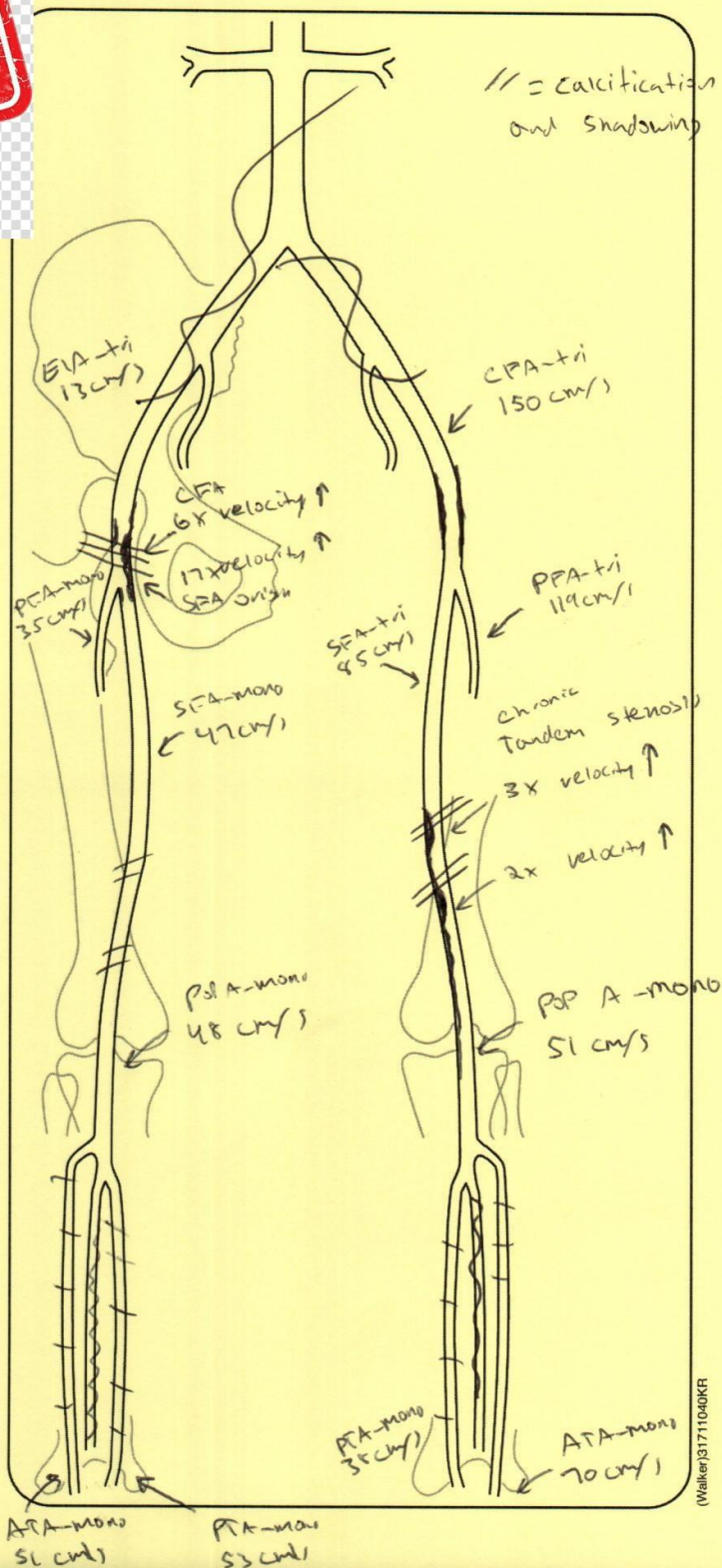
(L) Dist SFA/  
Pop POPA  
disease, good  
result

Image Quality: GOOD ☐ ☒ POOR

SIGNED: \_\_\_\_\_  
CLINICAL VASCULAR SCIENTIST

PRINT NAME: Alex Pash

DATE: 18/4/23



# VASCULAR STUDIES UNIT

Level 1  
Glenfield Hospital  
Tel: 0116 258 5440



University Hospitals  
of Leicester  
NHS Trust

## LOWER LIMB ARTERIAL DUPLEX SCAN REPORT



### Resting ankle pressures

Right	DP	PT	Per	BP	Index
Left	DP	PT	Per		

### Post-exercise pressures

Right	DP	PT	Per	BP	Index
Left	DP	PT	Per		

Time walked \_\_\_\_\_ mph

Comment:

Scan comment: Scanned bedside

A Triphasic CFA - PPA

Hyperemic ATA + PPA

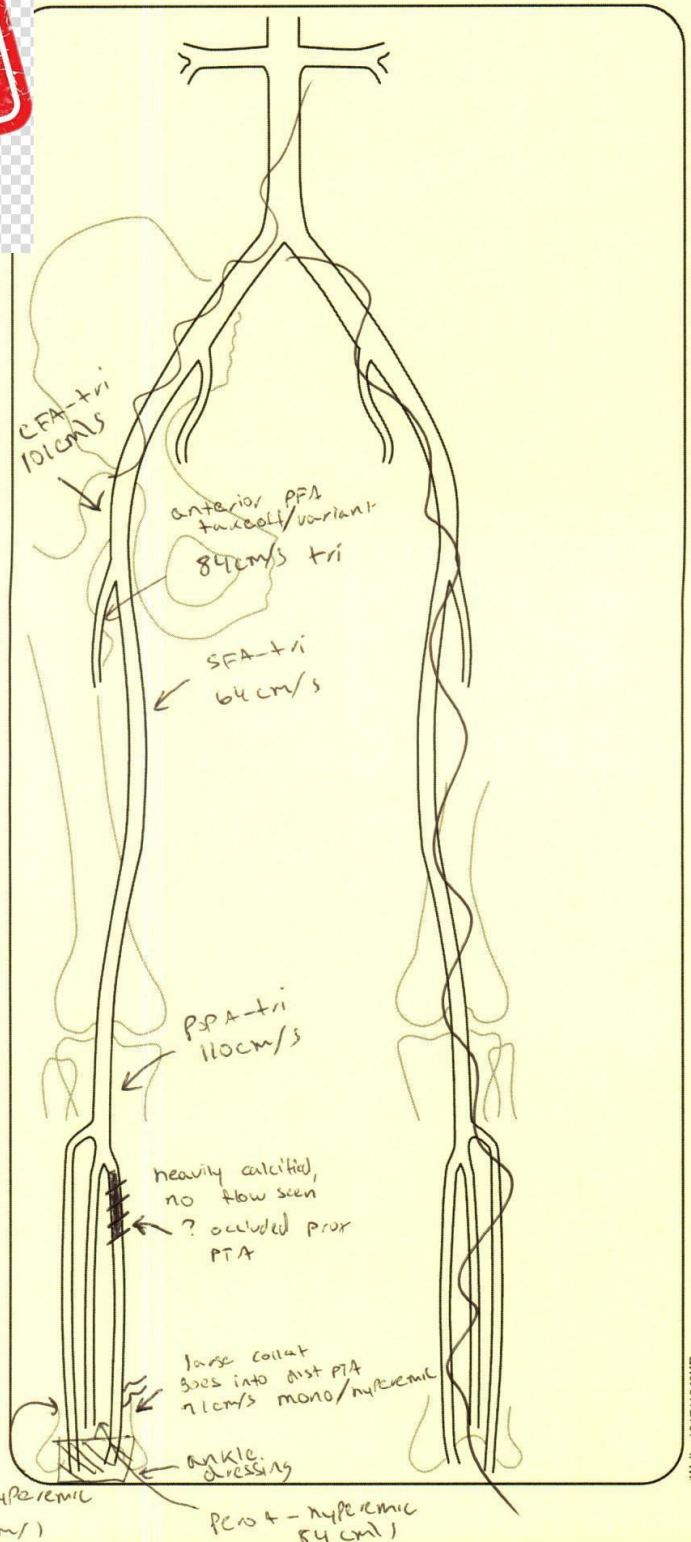
? prox PTA occlusion

Image Quality: GOOD ☐ ☒ POOR

SIGNED: \_\_\_\_\_  
CLINICAL VASCULAR SCIENTIST

PRINT NAME: Alex Paxton

DATE: 17/4/23





# VASCULAR STUDIES UNIT

Level 1  
Glenfield Hospital  
Tel: 0116 258 5440



University Hospitals  
of Leicester  
NHS Trust

## LOWER LIMB ARTERIAL DUPLEX SCAN REPORT



### Resting ankle pressures

Right	DP	PT	Per	BP	Index
Left	DP	PT	Per		

### Post-exercise pressures

Right	DP	PT	Per	BP	Index
Left	DP	PT	Per		

Time walked \_\_\_\_\_ mph

Comment:

### Scan comment:

No significant  
Ren-Ren disease  
seen

? PTA disease

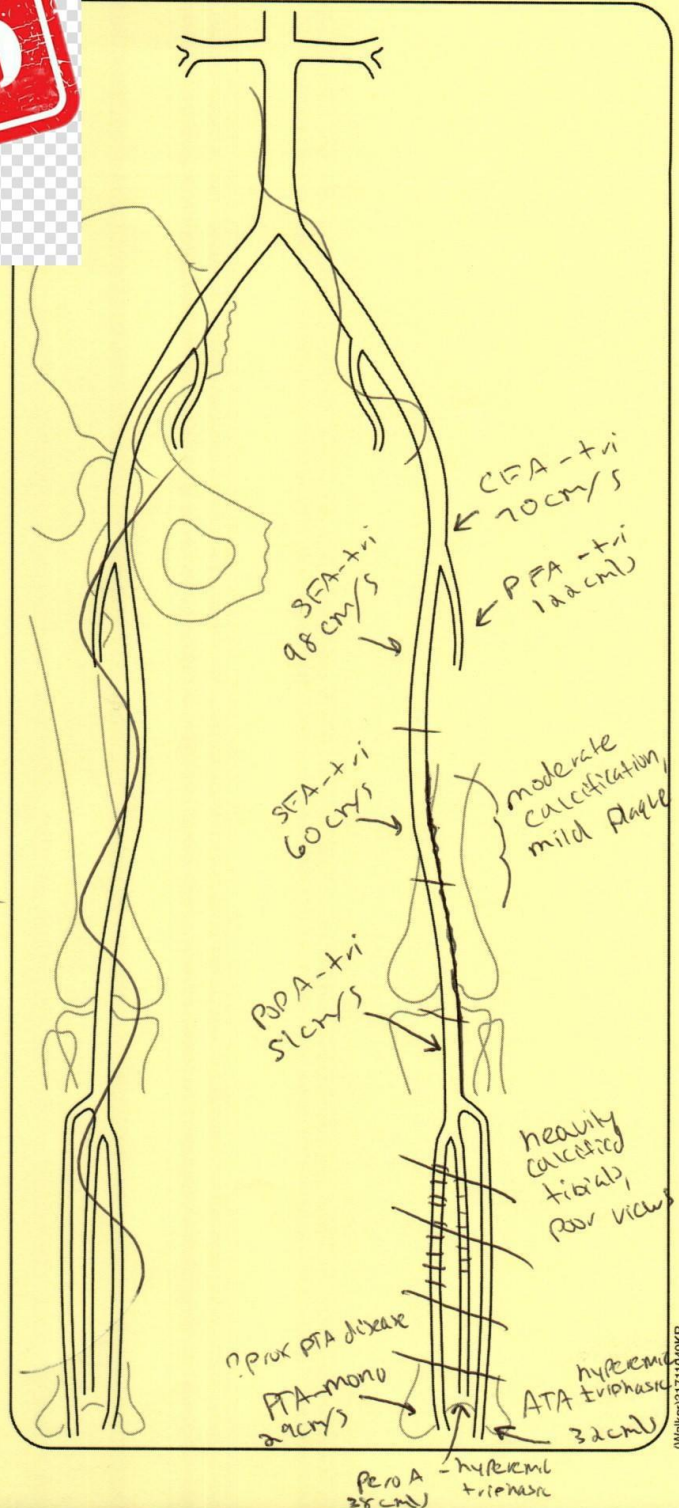
ATA + PerOA appear  
patent where seen

Image Quality: GOOD ☐ ☐ ☒ POOR

SIGNED:   
CLINICAL VASCULAR SCIENTIST

PRINT NAME: Alex Parn

DATE: 13/4/23





# VASCULAR STUDIES UNIT

Level 1  
Glenfield Hospital  
Tel: 0116 258 5440



University Hospitals  
of Leicester  
NHS Trust

## LOWER LIMB ARTERIAL DUPLEX SCAN REPORT



### Resting ankle pressures

Right	DP	PT	Per	BP	Index
Left	DP	PT	Per		

### Post-exercise pressures

Right	DP	PT	Per	BP	Index
Left	DP	PT	Per		

Time walked \_\_\_\_\_ mph

Comment:

### Scan comment:

Right LSV: Small calibre  
in most of the thigh, sizeable  
LV noted

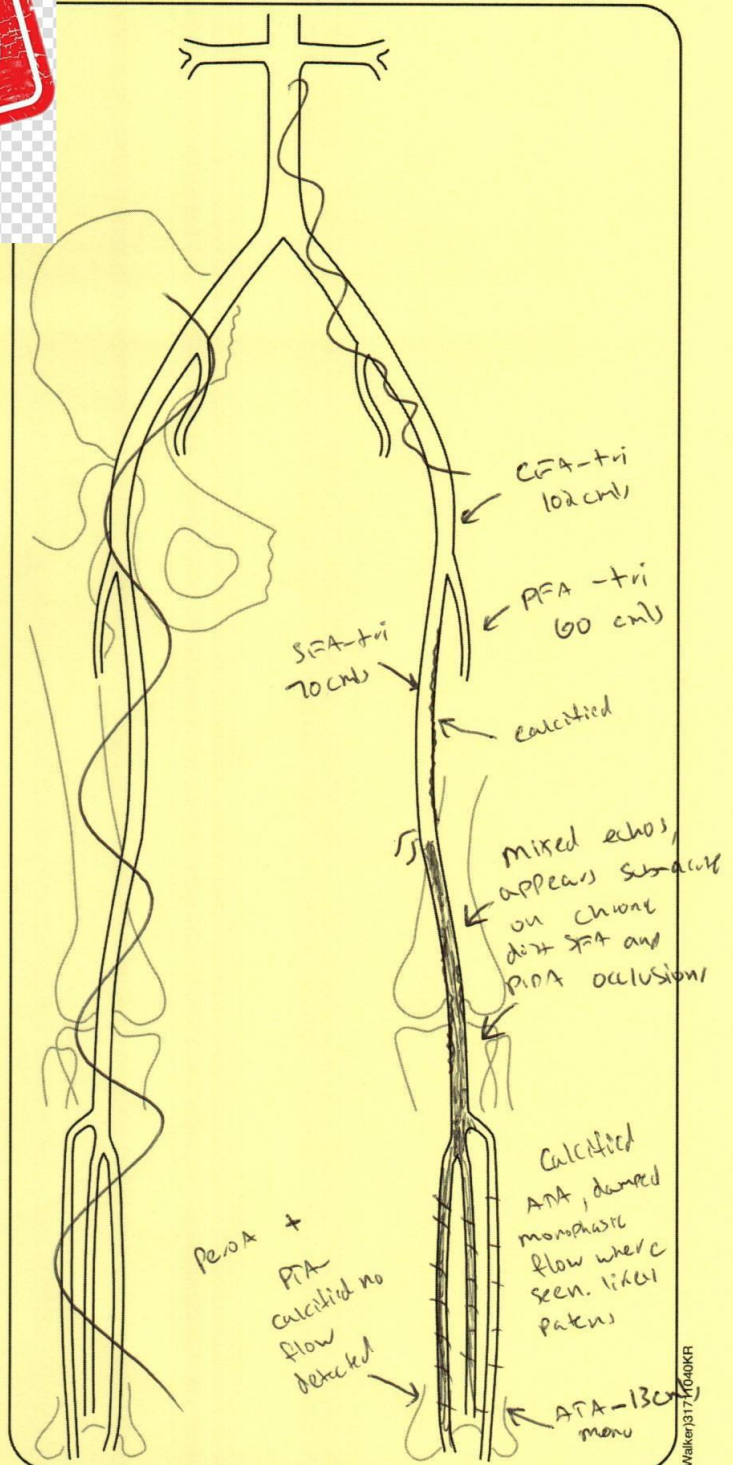
Left LSV: Small calibre  
in the thigh

Image Quality: GOOD ☐ ☒ POOR

SIGNED: CLINICAL VASCULAR SCIENTIST

PRINT NAME: Alex Pash

DATE: 4/4/23





# VASCULAR STUDIES UNIT

Level 1  
Glenfield Hospital  
Tel: 0116 258 5440

**NHS**  
University Hospitals  
of Leicester  
NHS Trust

## LOWER LIMB ARTERIAL DUPLEX SCAN REPORT

ABPI +/- Duplex



no	60				
Right	DP	PT	Per	BP	Index
Left	DP	PT	Per	BP	Index
no signal mono					
Post-exercise pressures					
Right	DP	PT	Per	BP	Index
Left	DP	PT	Per	BP	Index
Time walked					
mph					
Comment:					

### Scan comment:

CTA recommended for  
? Distal disease, Incomplete  
views

Right LSL: Small in the  
thigh (< 3.0mm)

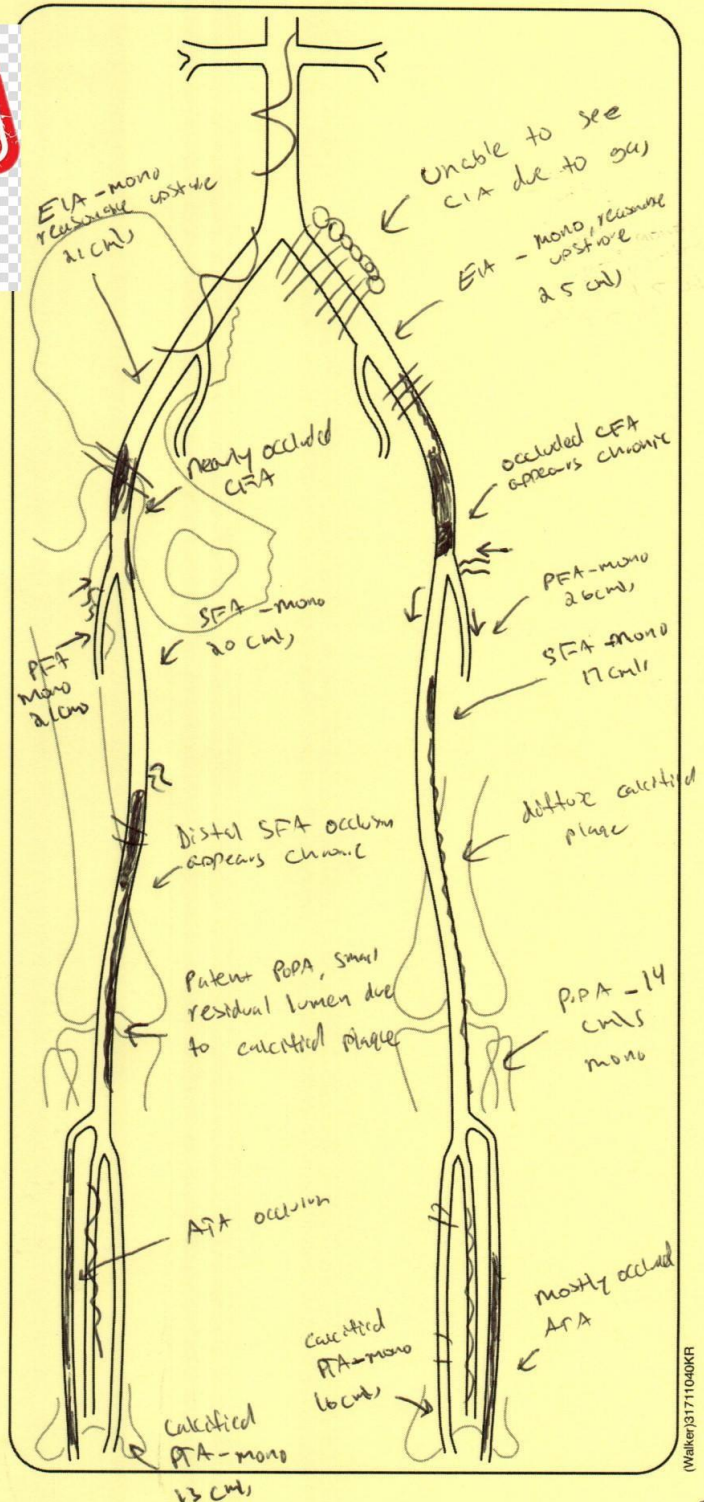
Left LSL: ~ 3.0mm in the  
thigh

Image Quality: GOOD ☐ ☐ ☒ POOR

SIGNED:   
CLINICAL VASCULAR SCIENTIST

PRINT NAME:

DATE: 4/4/23





# VASCULAR STUDIES UNIT

Level 1  
Glenfield Hospital  
Tel: 0116 258 5440



University Hospitals  
of Leicester  
NHS Trust

## LOWER LIMB ARTERIAL DUPLEX SCAN REPORT



### Resting ankle pressures

	Right	DP	PT	Per	BP	Index
Left	DP	PT	Per			

### Post-exercise pressures

	Right	DP	PT	Per	BP	Index
Left	DP	PT	Per			

Time walked: \_\_\_\_\_ mph

Comment:

### Scan comment:

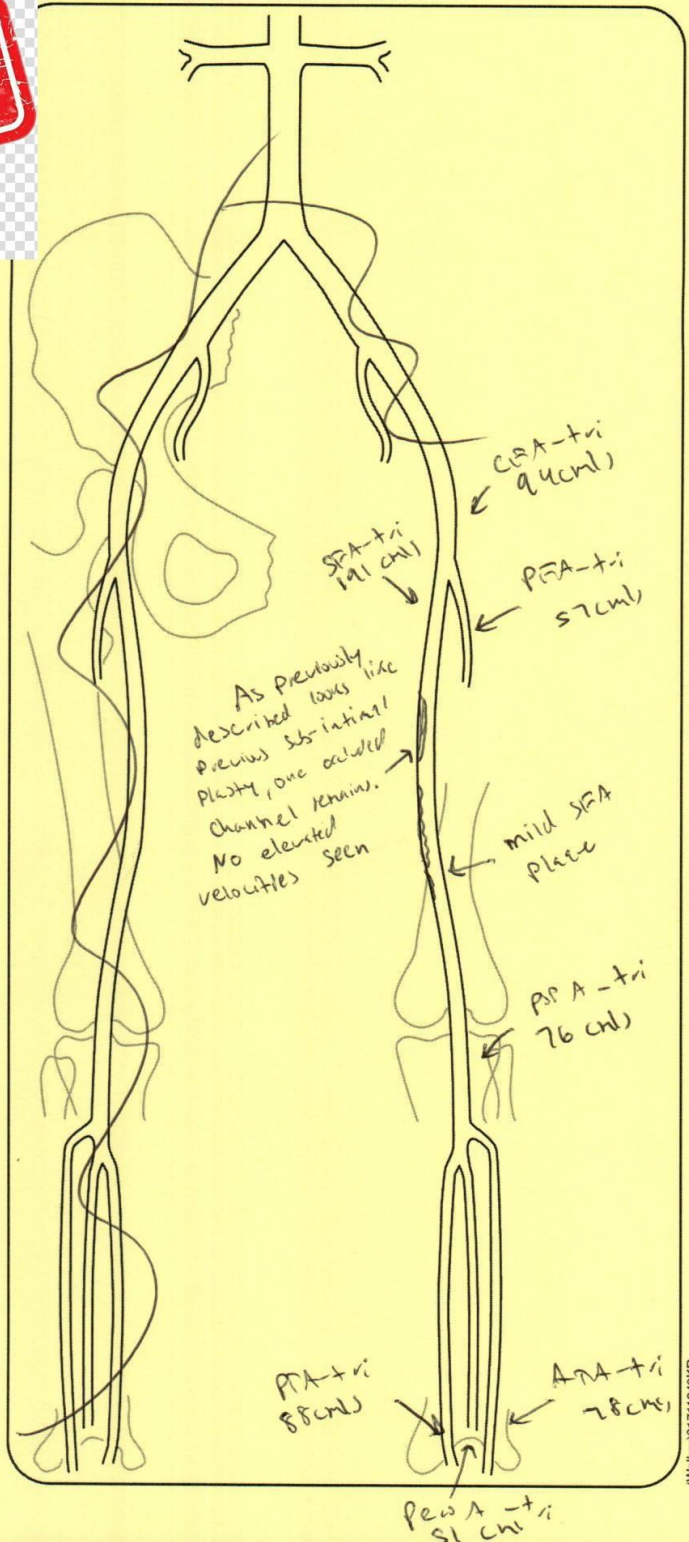
NO change since previous scan. Triphasic flow  
3 vessel runoff

Image Quality: GOOD ☒ ☐ ☐ POOR

SIGNED: \_\_\_\_\_  
CLINICAL VASCULAR SCIENTIST

PRINT NAME: Alex Parn

DATE: 3-4-23



# VASCULAR STUDIES UNIT

Level 1  
Glenfield Hospital  
Tel: 0116 258 5440



University Hospitals  
of Leicester  
NHS Trust

## LOWER LIMB ARTERIAL DUPLEX SCAN REPORT



### Resting ankle pressures

Right DP PT Per BP Index

Left DP PT Per

### Post-exercise pressures

Right DP PT Per BP Index

Left DP PT Per

Time walked \_\_\_\_\_ mph

Comment:

### Scan comment:

Right thigh LSV  
~4.0mm

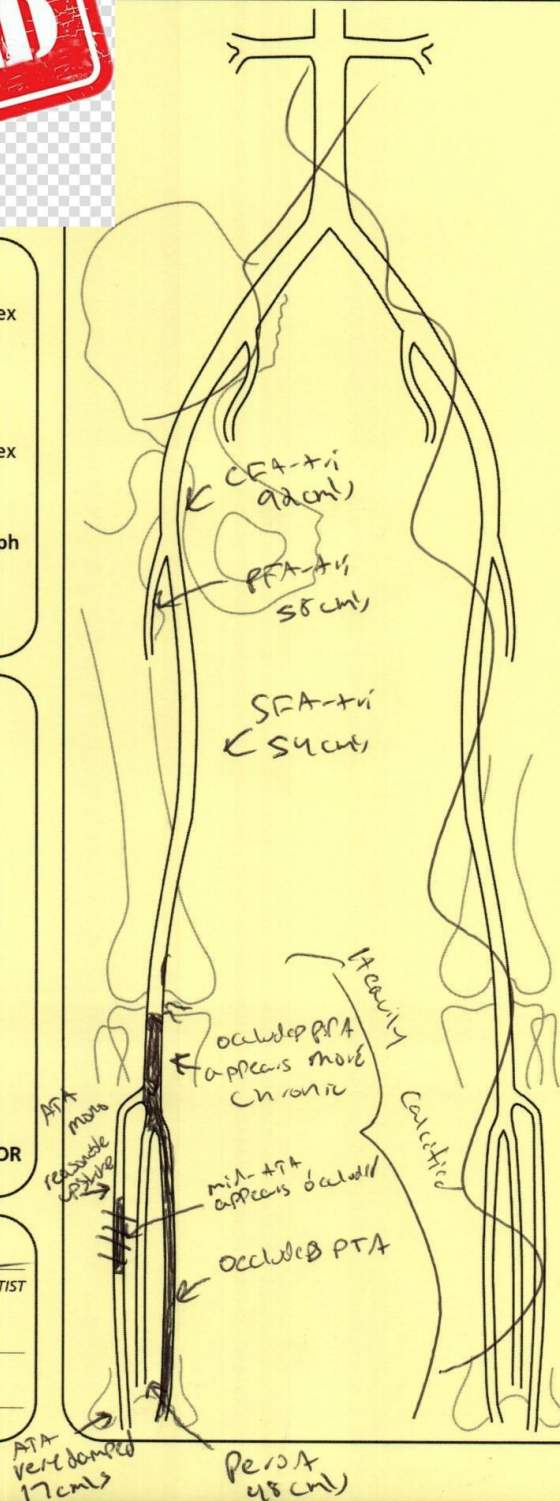
Image Quality: GOOD ☐ ☐ ☐ POOR

SIGNED: \_\_\_\_\_

CLINICAL VASCULAR SCIENTIST

PRINT NAME: \_\_\_\_\_

DATE: \_\_\_\_\_





# VASCULAR STUDIES UNIT

Level 1  
Glenfield Hospital  
Tel: 0116 258 5440



University Hospitals  
of Leicester  
NHS Trust

## LOWER LIMB ARTERIAL DUPLEX SCAN REPORT



### Resting ankle pressures

Right	DP	PT	Per	BP	Index
Left	DP	PT	Per		

### Post-exercise pressures

Right	DP	PT	Per	BP	Index
Left	DP	PT	Per		

Time walked \_\_\_\_\_ mph

Comment:

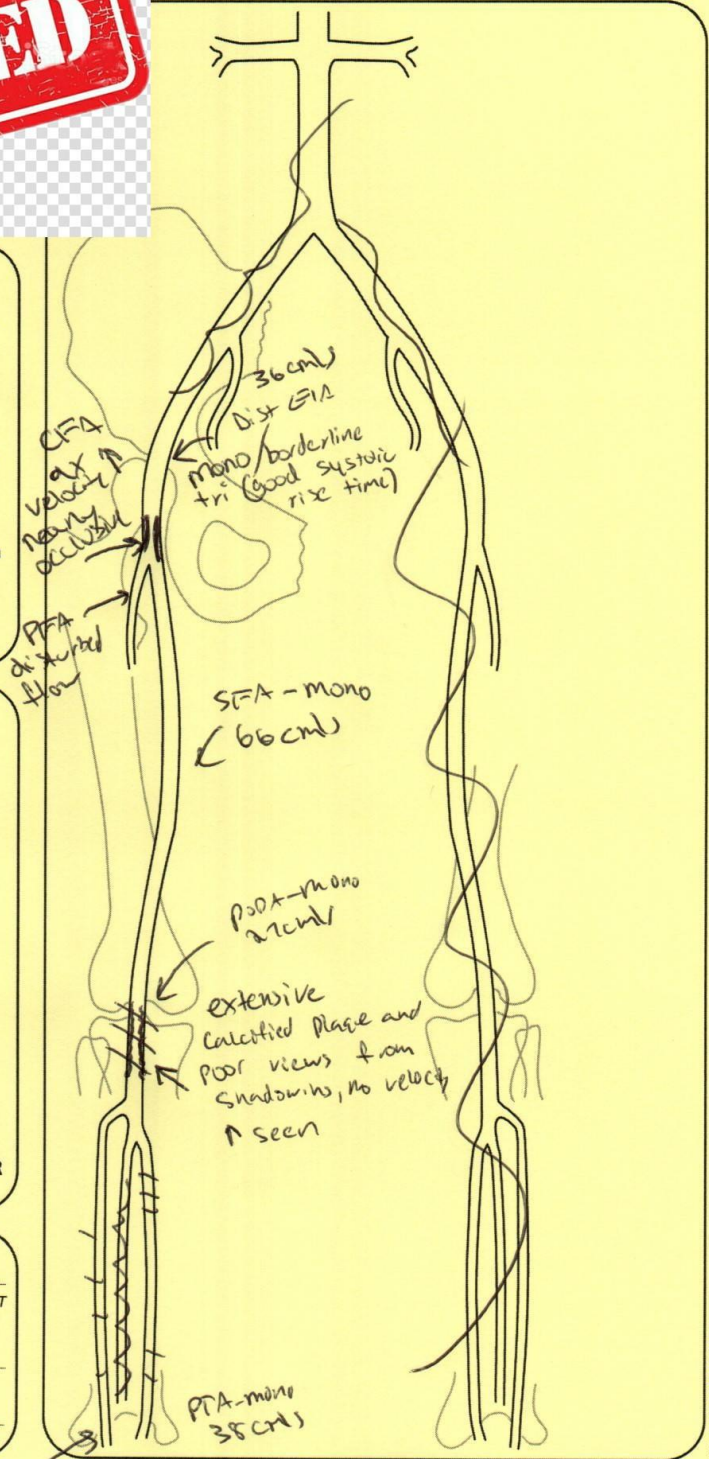
### Scan comment:

Image Quality: GOOD ☐ ☒ POOR

SIGNED: CLINICAL VASCULAR SCIENTIST

PRINT NAME: Alex Pash

DATE: 29-3-23



# VASCULAR STUDIES UNIT

Level 1  
Glenfield Hospital  
Tel: 0116 258 5440



University Hospitals  
of Leicester  
NHS Trust

## LOWER LIMB ARTERIAL DUPLEX SCAN REPORT



### Resting ankle pressures

Right	DP	PT	Per	BP	Index
Left	DP	PT	Per		

### Post-exercise pressures

Right	DP	PT	Per	BP	Index
Left	DP	PT	Per		

Time walked: \_\_\_\_\_ mph

Comment:

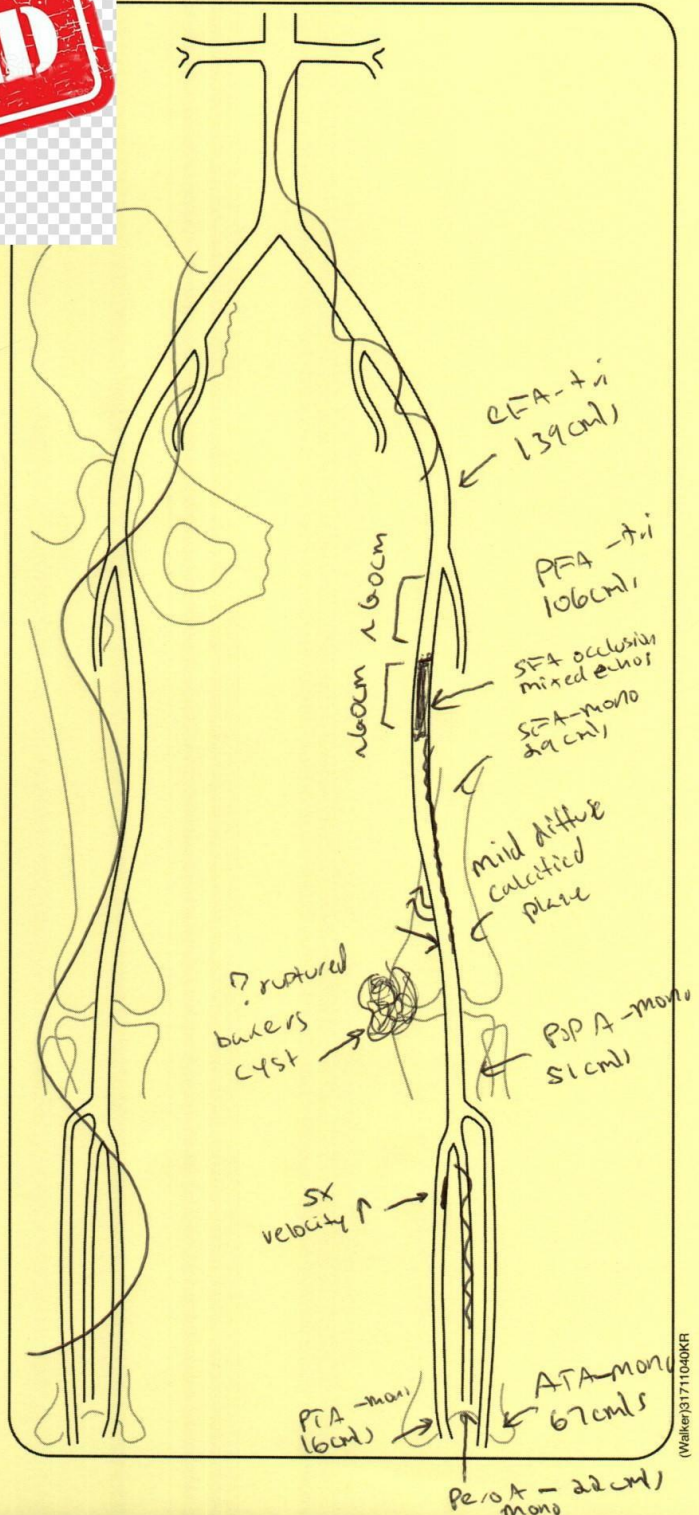
### Scan comment:

Image Quality: GOOD ☐ ☒ POOR ☐

SIGNED: \_\_\_\_\_  
CLINICAL VASCULAR SCIENTIST

PRINT NAME: Av P

DATE: 29-3-07



(Walker) 31711040RF



# VASCULAR STUDIES UNIT

Level 1  
Glenfield Hospital  
Tel: 0116 258 5440

**NHS**

University Hospitals  
of Leicester  
NHS Trust

## LOWER LIMB ARTERIAL DUPLEX SCAN REPORT



### Resting ankle pressures

Right DP PT Per BP Index

Left DP PT Per

### Post-exercise pressures

Right DP PT Per BP Index

Left DP PT Per

Time walked \_\_\_\_\_ mph

Comment:

### Scan comment: **R**


Triphasic flow  
into pop A.

PTA - mostly occluded

ATA - likely prox occlusion,  
good collaterals

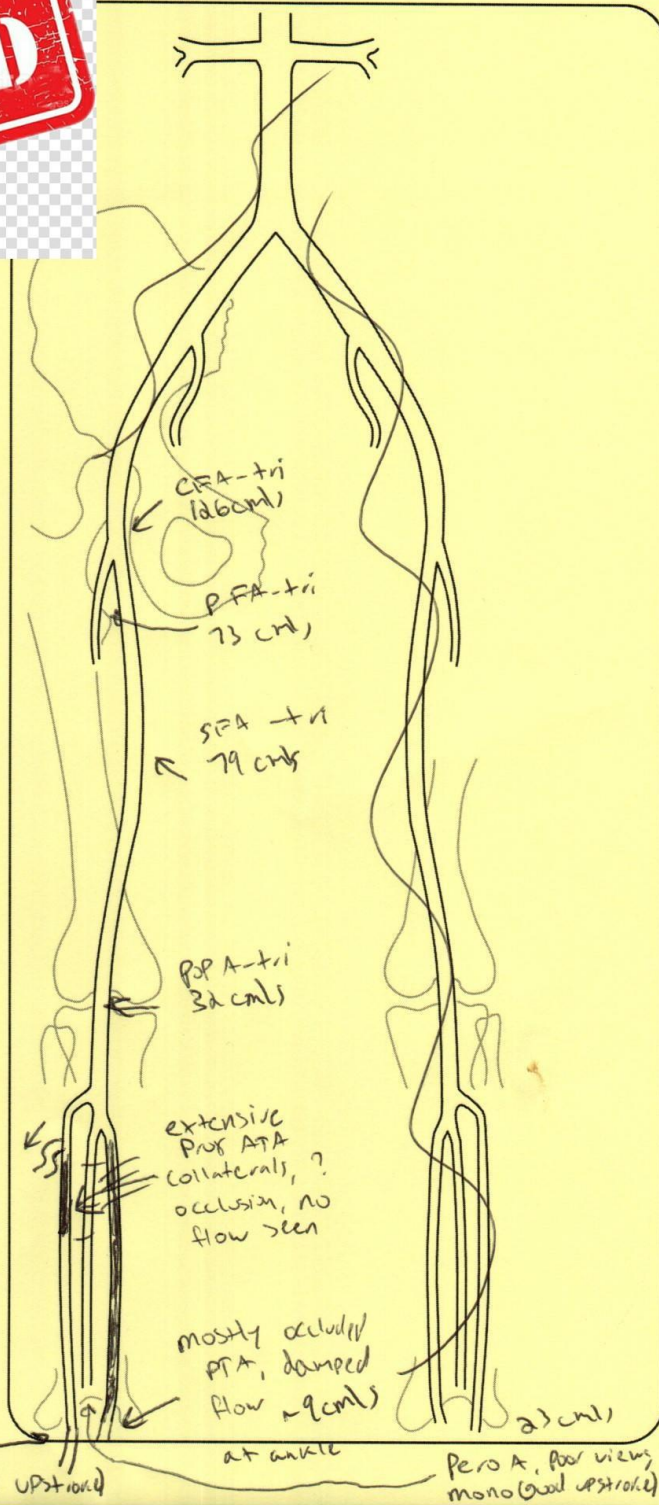
Per A - likely patent,  
poor view

Image Quality: GOOD ☐ ☒ POOR

SIGNED:   
CLINICAL VASCULAR SCIENTIST

PRINT NAME: Alex Per

DATE: 29-3-23



# ABDOMINAL VASCULAR DUPLEX SCAN REPORT



Consultant:

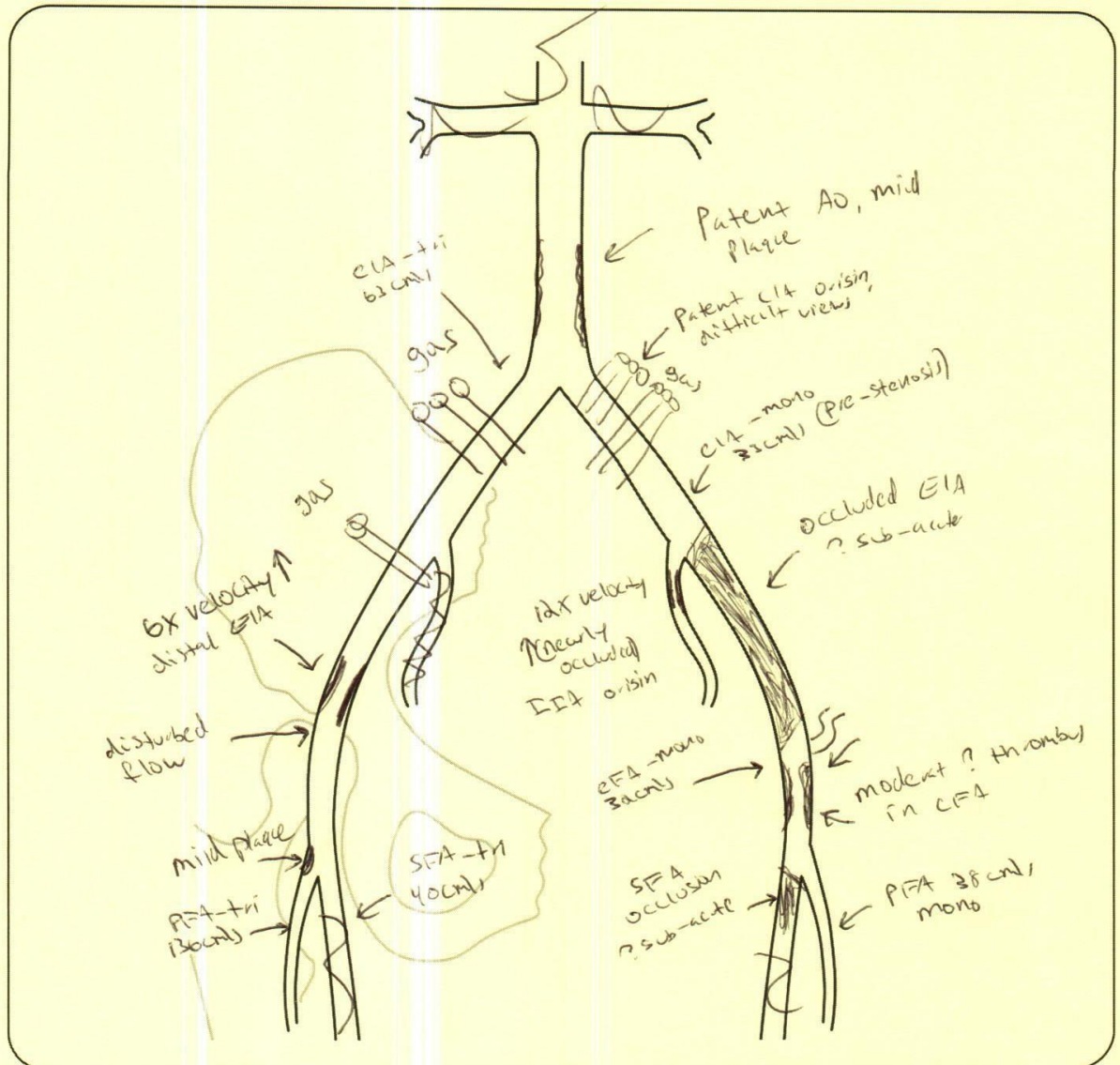
Clinical History: CLT

Comments:

Difficult to use but Iliac disease on left appears sub-acute

Dept: F&S

Hospital: G&H



SIGNED:

CLINICAL VASCULAR SCIENTIST

PRINT NAME:

Alex Pasu

DATE:

28-3-23

Image Quality:

GOOD

☐

☐

☒

POOR



# VASCULAR STUDIES UNIT

Level 1  
Glenfield Hospital  
Tel: 0116 258 5440



University Hospitals  
of Leicester  
NHS Trust

## LOWER LIMB ARTERIAL DUPLEX SCAN REPORT



### Resting ankle pressures

	Right	DP	PT	Per	BP	Index
Left	DP	PT	Per			

### Post-exercise pressures

	Right	DP	PT	Per	BP	Index
Left	DP	PT	Per			

Time walked \_\_\_\_\_ mph

Comment:

### Scan comment:

Triphasic flow  
throughout and into  
the foot

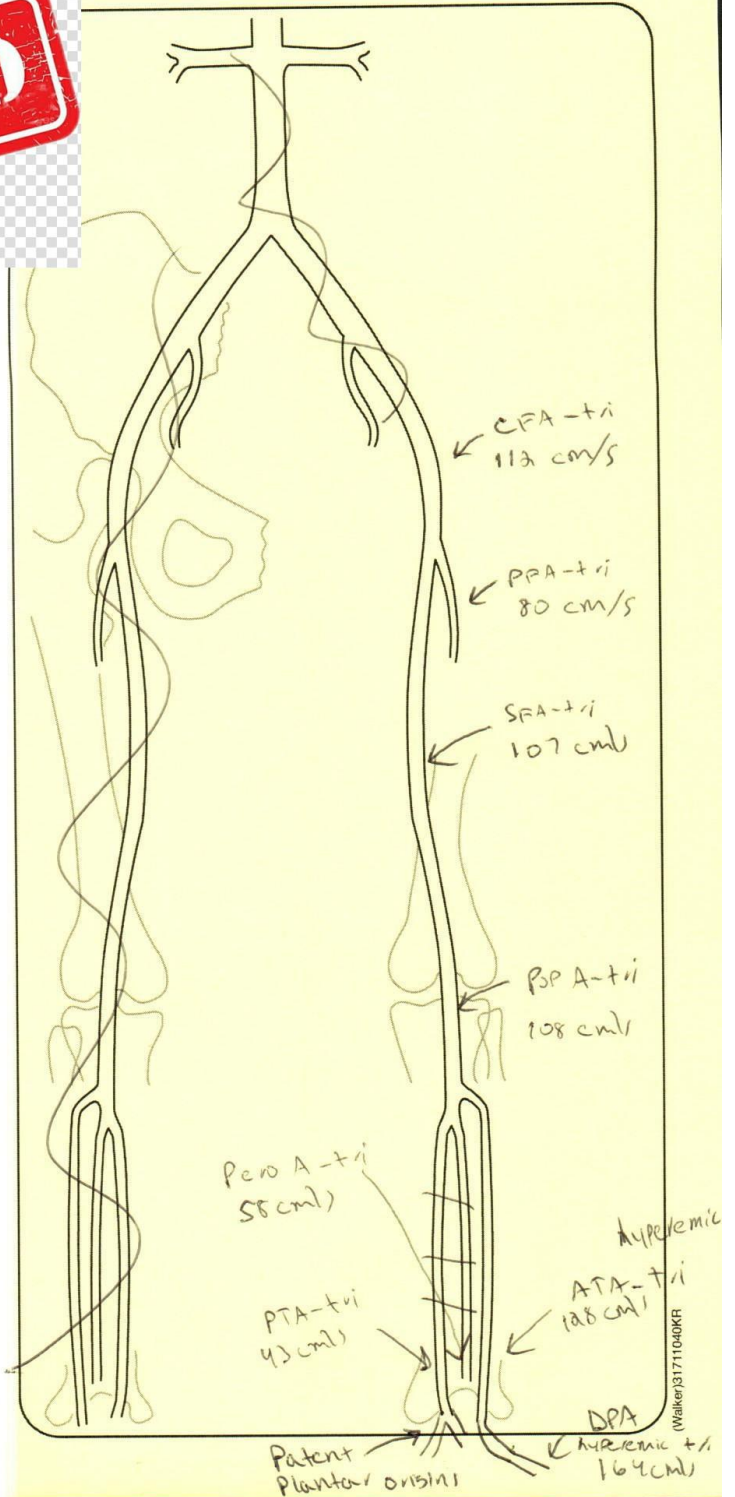
Image Quality: GOOD ☒ POOR ☐

SIGNED: \_\_\_\_\_

CLINICAL VASCULAR SCIENTIST

PRINT NAME: Alex Parson

DATE: 27-3-23



Walker/31711040KR

# VASCULAR STUDIES UNIT

Level 1  
Glenfield Hospital  
Tel: 0116 258 5440



University Hospitals  
of Leicester  
NHS Trust

## LOWER LIMB ARTERIAL DUPLEX SCAN REPORT

**CENSORED**

### Resting ankle pressures

Right	DP	PT	Per	BP	Index
40	30	PT	Per	BP	0.2
40	30	PT	Per	BP	0.2

Post-exercise pressures

Right	DP	PT	Per	BP	Index
40	30	PT	Per	BP	0.2
40	30	PT	Per	BP	0.2

Time walked \_\_\_\_\_ mph

Comment:

### Scan comment:

Damped Ao flow?  
proximal disease

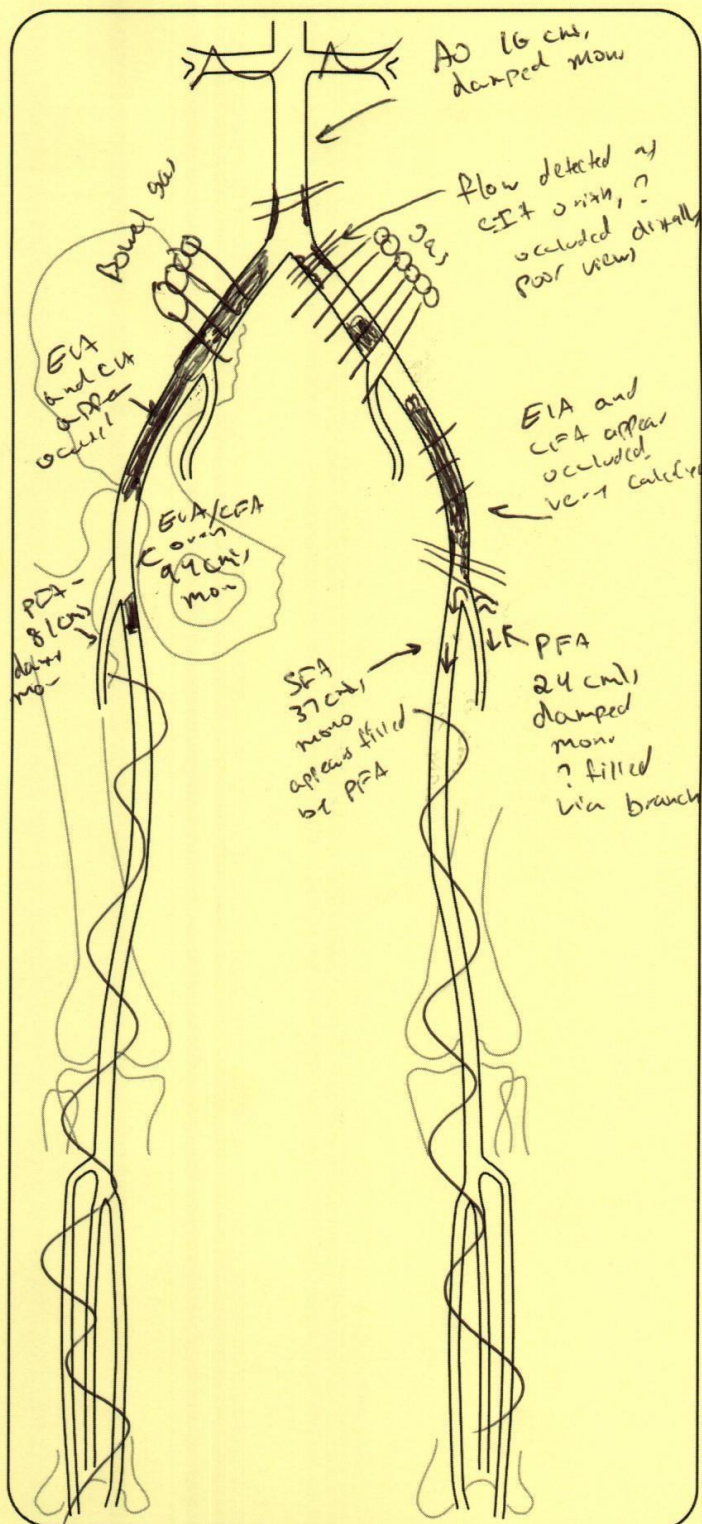
Bilateral Distal occlusion  
likely lower pop  
views. CTA recommended

Image Quality: GOOD ☐ ☐ ☒ POOR

SIGNED: \_\_\_\_\_  
CLINICAL VASCULAR SCIENTIST

PRINT NAME: Avr P

DATE: 23-3-23





Level 1  
Glenfield Hospital  
Tel: 0116 258 5440

**University Hospitals  
of Leicester**  
NHS Trust

Resting ankle pressures					
Right	DP	PT	Per	BP	Index
Left	DP	PT	Per		

Post-exercise pressures					
Right	DP	PT	Per	BP	Index
Left	DP	PT	Per		

Time walked \_\_\_\_\_ mph

Comment:

Scan comment:

Right:

Triphasic CFA, SFA, PFA

PTA + plantar, ~~ATA + PFA~~

ATA occlusion, more positive flow into DPA (good collaterals)

---

Left:

Triphasic CFA, SFA, PFA

ATA and PTA occlusion.

Patent PFA

Image Quality: GOOD ☐ ☐ ☒ POOR

SIGNED: \_\_\_\_\_

CLINICAL VASCULAR SCIENTIST

PRINT NAME: Alex Padi

DATE: 03-3-20