



2. Gourgiotis, S., Aggelakas, J., Salemis, N., Elias, C., Georgiou, C. 2008. Diagnosis and surgical approach of popliteal artery entrapment syndrome: a retrospective study. *Vascular health and risk management*. 4(1), pp83-86.
3. Wright, L.B., Matchett, W.J., Cruz, C.P., James, C.A., Culp, W.C., Eidt, J.F., McCowan, T.C. 2004. Popliteal artery disease: diagnosis and treatment. *Radiographics*. 24(2), pp.467-479.
4. Roche-Nagle, G., Wong, K.T., Oreopoulos, G. 2009. Vascular claudication in a young patient: popliteal entrapment syndrome. *Hong Kong medical journal*. 15(5), pp.388-390.
5. Soobrah, R., Nawaz, A., Hussain, T. 2010. Popliteal artery entrapment syndrome presenting with acute limb ischaemia: a case report. *Case reports in medicine*. 2010(281925), pp.1-3
6. Lamb, C.M., Davies, C.G., Whitbread, T. 2010. Two Cases of Misdiagnosed Popliteal Artery Entrapment Syndrome. *European Society for Vascular Surgery*. 20, pp.e16-e18.
7. Levien, L.J., Veller, M.G. 1999. Popliteal artery entrapment syndrome: more common than previously recognized. *Journal of vascular surgery*. 30(4), pp.587-598
8. Thrush, A., Hartshorne, T. 2010. *Vascular ultrasound: How, Why and When*. 3rd ed. Churchill Livingstone. Elsevier.

CL1.7**7. Lower limb venous duplex assessment****a) General**

Where possible, patients are assessed whilst standing, the majority of weight on the contra-lateral limb. The ipsilateral limb should be non-weight bearing to avoid muscular contraction of the veins. The knee should be slightly flexed and the foot turned outwards.¹² For assessment of the popliteal and calf veins, the patient may sit on the edge of the bed placing their foot in the CVS's lap, alternatively their feet may be placed on a raised stool. The thigh should slope downwards avoiding compression from the bed; the knee should be flexed with the calf muscles as relaxed as possible.²

A mid frequency linear array transducer should be used (12-3 MHz linear array) to image the proximal leg and calf veins.¹ A lower frequency curvilinear array transducer (5-1 MHz curvilinear array) should be used if it is necessary to image the iliac veins and inferior vena cava (IVC).¹ An appropriate venous default setting should be selected on the machine to ensure that low venous flow can be detected^{1,3}.

On calf augmentation all veins should fill from wall-to-wall with uniform blue colour. If the vein does not fill wall-to-wall, thrombus may be present. Investigation using different steering angles, lower colour PRF and wall filter settings should be utilised to optimise colourfilling.³ On release of the calf there should be no or very slight (<0.5s) retrograde flow, which indicates no significant reflux disease.⁴ Vein patency or obstruction should also be confirmed by ultrasound-compression.¹

**b) Deep Venous Thrombosis Assessment (12-3MHz linear array)**

The transducer is placed in the groin in transverse plane and the common femoral vein (CFV) is identified medial to the common femoral artery.³

The Doppler sample volume is placed in the CFV, corrected to a 60 degree angle and steered to align parallel with common femoral vein flow. The sample volume gate should span the full diameter of the lumen.^{1,8} Venous flow should be phasic with respiration. The patient is asked to perform a Valsalva manoeuvre, i.e. a cough. If a cough does not produce a satisfactory response, a full Valsalva manoeuvre should be performed.^{1,6} Ask the patient to take a breath in and hold it, then to increase the pressure in their thorax. This is achieved by asking the patient to 'bear down' – pretending to go to toilet.^{1,4} This should result in a temporary reversal of venous flow and indicate patency of proximal veins. With a proximal obstruction, flow in the CFV will be continuous and aphasic with respiration, with poor or no response to Valsalva manoeuvre.¹ If this occurs then the CVS should scan the iliac veins and IVC to assess whether there is a proximal DVT and/or a mass causing external compression of the vein.^{1,5,6}

Following completion of the Valsalva manoeuvre, the common femoral vein should be compressed using external transducer pressure, to confirm patency.¹ Assessment of competency (using colour/spectral Doppler) and patency (using compression) of all other deep proximal veins should be performed as follows. The distal CFV bifurcates into two deep veins. The deeper vein is the profunda femoris vein, the more superficial vein is the superficial femoral vein (SFV). The profunda femoris origin should be assessed whilst the SFV should be assessed along its length, adopting an increasingly antero-medial approach.^{2,5} The popliteal vein is located within the popliteal fossa – care should be taken to scan as proximally as possible to overlap with the distal SFV.¹

Manual compression of the deep veins should be repeated at regular intervals (2-3cm); failure to fully compress the veins may indicate the presence of thrombus.² The echogenicity of the thrombus indicates its age.¹¹ Thrombus becomes increasingly echogenic over time, as it becomes more organised.¹ In time, the vessel may begin to re-canalise – old residual thrombus can be seen to produce a scarred appearance, with multiple channels of flow seen.¹ Slow or partial re-canalisation can result in deep venous insufficiency.¹ Competency is assessed by calf augmentation using both colour and spectral Doppler - on release of the calf there should be no or very slight (<0.5sec) retrograde flow, which indicates no significant reflux.⁴

Deep calf veins should be assessed using manual compression, colourflow and spectral Doppler to assess competency. The transducer is placed into the popliteal fossa and the popliteal vein is identified lateral to the mid line. Up to eight gastrocnemius veins may be visualised in the proximal calf, within the gastrocnemius muscle.² The soleal veins are imbedded in the soleus muscle and are often less easily identified. Several soleal veins may be present which may have connections with other deep calf veins – often the posterior tibial or peroneal veins. Soleal veins are identified more distally than the



gastrocnemius veins.² If gastrocnemius or soleal veins appear particularly dilated, they should be assessed for competency using colour/spectral Doppler.

The anterior tibial veins may be seen as the first deep communication with the popliteal vein. Distal to this junction the tibio-peroneal trunk veins divide to form the posterior tibial and peroneal veins.^{1,12} It is sometimes easier to trace the deep calf veins from the ankle proximally. Placing the transducer posterior to the medial malleolus, both posterior tibial veins can be visualised adjacent to the posterior tibial artery.² If the probe is angled slightly posteriorly the peroneal artery and veins should be visualised deep to the posterior tibial vessels.² Placing the transducer on the anterior aspect of the ankle, the anterior tibial artery and veins can be visualised and traced.¹⁴ Placing your thumb and first finger on the antero-medial or antero-lateral aspects of the ankle and applying pressure can augment flow in posterior tibial, anterior tibial and peroneal veins in order to assess competency.^{1,2}

When a DVT scan is requested the LSV, SSV and their junctions with the deep venous system should be assessed for superficial thrombophlebitis and obvious signs of incompetence.^{1,2,11} If the LSV is incompetent within 0.5cm of the SFJ, it is assumed that the SFJ is slightly incompetent even if no reflux is seen in the CFV.

Differential diagnoses of clinical DVT include (but are not limited to): Bakers cysts, superficial oedema, cellulitis, lymphoedema, thrombophlebitis, popliteal arterial aneurysms and superficial venous incompetence. If you identify an abnormal lesion during the course of your scan, note site, dimensions and descriptive information.

Iliac Vein Scanning

We do not routinely scan the iliac veins when scanning for a DVT as the cough or Valsalva manoeuvre is usually sufficient to diagnose any proximal disease. However there are certain scenarios when we need to scan the iliac veins to be clinically certain:

- Negative or poor Valsalva response
- Obvious leg swelling in the thigh
- Evidence of collateral veins in the proximal thigh/groin/abdomen
- Evidence of thrombus in the common femoral or bifurcation
- Previous known iliac DVT
- Unable to adequately visualise the common femoral or bifurcation (eg due to scarring, infection, injection site etc).

Rescan Policy

In some situations it is difficult to be certain that a vein is patent along its length. In such cases we state that we are “unable to fully exclude a DVT”. The scan is equivocal and upon the clinicians discretion usually requires a rescan 6-8 days later to check for DVT progression.² Local protocols differ slightly as below:



Oldham/NM: The patient is brought back to have a further scan following an equivocal result. The equivocal vein and up to the popliteal vein is rescanned assessing for progression of the potential DVT.

South Manchester/Bury/Stepping Hill: The patient is brought back to have a further scan following an equivocal result. The symptomatic leg is fully rescanned from the CFV to ankle.

Bolton/Blackpool/Arrowe Park/: The patient is brought back to have a further scan following an equivocal result. The symptomatic leg is rescanned from the CFV to popliteal vein only, assessing for progression of the potential DVT in line with NICE guidelines

Stepping Hill – Additional Information

DVT referrals can be accepted from HASU (ED or A10) or the rapid access stroke clinics to aid patient flow through the ward/clinic. The patients are sent back to the ward/clinic with the result and the ward/clinician is informed of an equivocal result so that the patient can be brought back in a week for a rescan. The ward or clinician in clinic should arrange this and send us a repeat referral.

c) Varicose Vein Assessment

A full DVT scan is performed, as per the above protocol. Evidence of deep venous insufficiency and previous DVT should be clearly noted in the report. The superficial system should be assessed as below:

Long Saphenous Vein

Moving distally along the common femoral vein, the long saphenous vein (LSV) will appear as a superficial medial branch. Assessment of competency at the level of the sapheno-femoral junction (SFJ) should be performed by calf augmentation using colour/spectral Doppler.¹ If the LSV is incompetent within 0.5cm of the SFJ, it is assumed that the SFJ is slightly incompetent, even if no reflux is seen in the CFV. The (LSV) should be traced along its length in longitudinal and transverse planes, as isolated segments of incompetence may be identified. Any incompetent branches/perforators should be noted.²

Short Saphenous Vein

The short saphenous vein (SSV) is identified in the upper calf and traced distally to ensure that it remains within the fascia into the lower calf. The SSV is checked for competency and patency and then traced proximal to its junction with the popliteal vein.¹⁰ Any incompetent branches/perforators should be noted.² In the presence of SSV incompetence, the popliteal vein must be viewed proximal and distal to the sapheno-popliteal junction (SPJ) to determine whether the junction is incompetent.¹ In some cases an SPJ may not be identified and/or the SSV may communicate with the vein of Giacomini which lies just beneath the fascia and extends into the proximal posterior thigh and may connect to the LSV.¹²

If the SPJ is incompetent, then its location needs to be recorded – the distance measured proximal to the knee crease and lateral/medial to the mid line.^{2,5}

The distance of any incompetent perforators from the medial malleolus should be noted and marked if the patient is undergoing superficial venous surgery.²

Table: Grading of incompetence.¹

Grade	Reflux Duration
Normal	<0.5 seconds
Slightly Incompetent	0.5 – 1.0 seconds
Incompetent	>1.0 seconds

Primary Varicose Vein Protocol

The Vascular Consultant will review patient referral letters and specifically request the limited protocol outlined below.¹³

The protocol should be used in conjunction with the Section 5 ‘Lower limb venous duplex assessment’ from ‘Protocols for non-invasive and minimally invasive assessments’ for explanation of patient positioning probe, colourflow and Doppler settings.²

1. Assess common femoral vein for patency and competency.¹
2. Comment of absence or presence of sapheno-femoral junction (SFJ) and its competency.²
3. Comment on absence or presence of long saphenous vein (LSV) and its competency.¹³
4. Comment on the absence or presence of anterior or posterior veins which form junctions to the LSV within 3cm of the SFJ, measure the distance of the junction to the SFJ, and comment on the competency of the vein.^{2,13}
5. If an incompetent thigh vein is identified but the SFJ is absent, the position the vein reforms should be identified and measured and any incompetent thigh perforators identified and measured.¹⁷
6. Assess popliteal vein for patency and competency.^{2,13}
7. Comment of absence or presence of sapheno-popliteal junction (SPJ) and its competency.¹
8. Comment on absence or presence of short saphenous vein (SSV) and its competency.^{2,13}
9. Incompetent thigh veins and SSV should be assessed for suitability for EVLT or VNUS as per full EVLT protocol (see copy below).
10. All other deep veins do not need assessment unless there is evidence of thrombus in the common femoral or popliteal veins.¹⁴
11. Calf perforators do not need to be assessed or measured.^{2,13}

Patient will be reviewed by the Vascular Consultant and if necessary referred for full Venous duplex protocol.

Endovenous Laser Treatment/ VNUS protocol



The inclusion criteria are as follows:

1. The LSV needs to follow a relatively straight course; it will be difficult to pass the laser up a tortuous vein. If the LSV leaves the fascia or becomes tortuous state the distance from the medial malleolus and also comment on general position.
2. It needs to be checked whether the LSV is bifid – both veins can be treated providing they are of suitable diameter.
3. The vein diameter (AP) needs to be measured at the junction, mid-thigh, knee level and the minimum diameter stated. If the LSV dilates make another diameter measurement and its distance from medial malleolus.
4. Need to ensure LSV is widely patent – no evidence of recent/old thrombophlebitis.
5. Any incompetent branches close to the SFJ need to be measured. If there is an incompetent branch less than 1-1.5cm from the SFJ then the patient will not be suitable for EVLT. Other major branches should also be identified.
6. Redo LSV's can be retreated with the laser if they are of a suitable diameter so provide measurements as above. State whether there is an intact/reformed SFJ or not.
7. As with all superficial venous procedures the whole deep venous system needs to be competent and patent (Except for simple varicose vein assessments, where the patency and competency of the CFV and popliteal vein only need to be checked).
8. Incompetent thigh accessory veins can be treated with EVLT/VNUS. Minimum and maximum diameters of these veins must be recorded, and if they exit the fascia, the approximate treatable length should be measured (from the SFJ to point at which they leave the fascia).

d) Venous marking

The patient should be asked to point out the major varicose veins or where they feel discomfort.¹⁴ Under direction of the patient any obvious varicosities should be traced to their junctions with the major venous branches and marked. Any perforators should be marked. The sapheno-femoral and sapheno-popliteal junctions should be marked if incompetent.¹⁵

When marking the SPJ or perforators prior to surgery you need to ensure the mark is directly above the structure of interest.^{2,15} In the longitudinal section, move the leading edge of the probe so the structure is just off the screen and mark either side of the leading edge.¹ In TS, again move the leading edge so the structure is just off the screen and mark the skin on the upper edge of the probe.^{1,15} This should result in three marks on the skin surface and where the imaginary lines bisect marks the structure. Extend the dots towards the bisecting point but do not join up as the permanent ink has been known to tattoo the skin during surgery. The final mark should resemble an upside 'T' without a connecting section.^{2,15}

e) Long (LSV) and short saphenous vein (SSV) mapping, 12-3MHz probe



In some cases of lower limb bypass surgery the saphenous veins are used as the conduits. Surgery that uses an autogenous vein can be greatly aided by a detailed preoperative venous assessment.^{2,15} Patient is assessed, when possible, in a standing position or sitting to facilitate maximum filling of veins.¹ The LSV or SSV are identified, (outlined above in “venous duplex assessment”) and traced along their length in L.S. and T.S. to confirm patency and compression should be used to exclude thrombus/incompetency.¹⁴

In transverse section – A.P. diameters are measured in the proximal, mid and distal thigh for the LSV, and proximal, mid and distal calf for the LSV and SSV. In transverse section the probe is moved so the vein is just off the edge of the screen (ensuring probe is perpendicular to vessel) and marks are made along its length using the indelible pen to map out the vein.^{1,2,16}

The course of the vein is marked on leg, allowing improved use of veins and better planning of the specific surgical approach. It minimises the dissection and reduces the frequency of wound complications.¹⁵

To be suitable as a bypass the vein has to be greater than 0.30cm and not varicose, thrombosed or tortuous.^{2,15}

A full length review of the LSV will be produced with the tributaries marked and specific measurements recorded;

Vessel Inner Diameter (These will be recorded at 6 specific points)

Proximal Thigh, Mid-Thigh, Distal Thigh, Proximal Calf, Mid Calf, Distal Calf

Varicosities/Tributaries (including perforators)

The location and number of tributaries and possible varicosities will be marked and recorded.

Intramural Thrombus

The presence and location of any intramural thrombus will be noted.

Total usable length

The total usable length will be recorded based on a diameter greater than 0.3 cm and is measured from the sapheno-femoral junction.

Depth from skin surface

The depth from the skin surface will be marked.

REFERENCES

- 1) Thrush and Hartshorne, Vascular Ultrasound, How, Where and When, 3rd Edition, 2010.



- 2) Vascular Laboratory Practice Part III, IPEM, 1st Edition, 2001.
- 3) Iu22 Ultrasound System. Getting started handbook. Philips, September 2005.
- 4) Abu-Own A et al, 1994, Saphenous vein reflux without incompetence at the sapheno-femoral junction. British Medical Journal of surgery 81: 1452-1454.
- 5) Cavezzi A et al, 2006 Duplex ultrasound investigation of the veins in chronic venous disease of the lower limbs – UIP consensus document. Part II. Anatomy. European Journal of Vascular and Endovascular Surgery 31: 288-299.
- 6) Gloviczki P et al, 2011. The care of patients with varicose veins and associated chronic venous disorders: Clinical practice guidelines for the Society of Vascular Surgery and the American Venous Forum. Journal of
- 7) Vascular Surgery 53(5): 2S-48S.
- 8) Kremkau, F W, Sonography, Principles and Industry, 8th Edition. 2011.
- 9) Gibbs V, Cole D, Sassano A, Ultrasound physics and technology, how, why and when. 1st Edition. 2009.
- 10) Zweibel W J, Pellerito J S 2005 Introduction to vascular ultrasonography 5th edition. Eisevier Saunders, Philadelphia.
- 11) Cogo A, Lensing A W, Koopman M M et al. 1998 Compression ultrasonography for diagnostic management of patients with clinically suspected deep vein thrombosis: prospective cohort study. British Medical Journal 316: 17-20.
- 12) Bernstein F. Vascular Diagnosis. 4th Edition, 1993.
- 13) Delis K, Knaggs A. 2004. Prevalence, anatomic patterns, valvular competence of the Giacomini vein. Journal of Vascular Surgery. 40(6): 1174-1183.
- 14) Society for Vascular Ultrasound. (2010) Lower extremity venous insufficiency evaluation.
<http://www.svunet.org/practicemanagementmain/professionalperformanceguidelines>
- 15) Society for Vascular Ultrasound. (2010) Lower extremity venous duplex evaluation.
<http://www.svunet.org/practicemanagementmain/professionalperformanceguidelines>
- 16) Society for Vascular Ultrasound. (2008) Lower extremity vein mapping.
<http://www.svunet.org/practicemanagementmain/professionalperformanceguidelines>
- 17) Levi N, Schroeder T. 1997. Preoperative ultrasound mapping of the saphenous vein: Prognostic value on early post operative results, a prospective study. Department of Vascular Surgery. University of Copenhagen. Denmark. Oskaa City Medical Journal. 43(1): 77-80.

8. Trans-vaginal ultrasound for pelvic vein incompetence (TVDU)

CL1.8

Reason DVT

Outcome DVT positive - chronic, Incompetence - deep

	Right		Left	
	Patency	Competency	Patency	Competency
Deep Veins				
Common Iliac Vein	Not Assessed			
External Iliac Vein	Not Assessed			
Internal Iliac Vein	Not Assessed			
Common Femoral Vein	Widely Patent	Competent	Widely Patent	
Profunda Vein	Widely Patent	Competent	Widely Patent	
Superficial Femoral Vein	Widely Patent	Competent	Occluded	Old Thrombus
Popliteal Vein	Widely Patent	Competent	Areas of Thrombus	Venous scarring
Posterior Tibial Vein	Widely Patent	Competent	Areas of Thrombus	Old Thrombus
Anterior Tibial Vein	Widely Patent	Competent	Widely Patent	Competent
Peroneal Vein	Widely Patent	Competent	Areas of Thrombus	Old Thrombus
Soleal Vein	Not Identified		Not Identified	
Gastrocnemius	Widely Patent	Competent	Widely Patent	Competent
Superficial Veins				
Saphenofemoral Junction	Patent	Competent	Patent	Competent
L Saphenous Vein Above	Patent	Competent	Patent	Competent
L Saphenous Vein Below	Patent	Competent	Patent	Competent
Vein of Giacomini	Patent	Competent	Not Identified	
Saphenopopliteal Junction			Patent	Competent
S Saphenous Vein	Patent	Competent	Patent	Competent
Evidence of D.V.T.				
Above the knee	No		Yes	Old
Popliteal	No		Yes	Old
Below the knee	No		Yes	Old

Notes

BILATERAL LOWER LIMB VENOUS DUPLEX ASSESSMENT

RIGHT

Iliac veins not viewed. Flow in the common femoral vein is phasic with respiration and a normal response on Valsalva manoeuvre, suggesting proximal vein patency. All visualised deep veins appear widely patent and competent with no evidence of previous DVT.

Sapheno-femoral junction (SFJ) is widely patent and competent. Long Saphenous vein (LSV) is widely patent and competent along length.

Sapheno-popliteal junction (SPJ) was not identified. Short Saphenous vein (SSV) is competent and is continuous with a competent vein of Giacomini.

Assessed by Jack Wilson

Printed on 16/11/2021 at 1:01 pm

Checked by

LEFT

Iliac veins not viewed. Flow in the common femoral vein is phasic with respiration and a normal response on Valsalva manoeuvre, suggesting proximal vein patency.

Common femoral and profunda femoral veins are widely patent and competent with good colour filling and are fully compressible.

Non-occlusive old thrombus identified in the proximal superficial femoral vein. Mid vessel appears chronically occluded. Non-occlusive old thrombus identified in the distal vessel.

Venous scarring identified in the popliteal vein.

Non-occlusive old thrombus identified in 1 x mid posterior tibial vein with isolated incompetence noted, other vessel appears patent and competent with reasonable colour filling and is fully compressible.

Non-occlusive, old thrombus identified in the peroneal veins however both vessels appear competent.

Anterior tibial and Gastrocnemius veins appear widely patent with good colour filling and are fully compressible.

Evidence of extensive chronic left leg DVT detected from this scan.

Sapheno-femoral junction (SFJ) is widely patent and competent. Long Saphenous vein (LSV) is widely patent and competent along length.

Sapheno-popliteal junction (SPJ) was not identified. Short Saphenous vein (SSV) is competent and is continuous with a competent vein of Giacomini.

Reason Varicose vein

Outcome DVT negative, Widely patent , Normal, Competent

	Right		Left	
Deep Veins	Patency	Competency	Patency	Competency
Common Iliac Vein	Not Assessed			
External Iliac Vein	Not Assessed			
Internal Iliac Vein	Not Assessed			
Common Femoral Vein	Widely Patent	Competent		
Profunda Vein	Widely Patent	Competent		
Superficial Femoral Vein	Widely Patent	Competent		
Popliteal Vein	Widely Patent	Competent		
Posterior Tibial Vein	Widely Patent	Competent		
Anterior Tibial Vein	Widely Patent	Competent		
Peroneal Vein	Widely Patent	Competent		
Soleal Vein	Widely Patent	Competent		
Gastrocnemius	Widely Patent	Competent		
Superficial Veins				
Saphenofemoral Junction	Patent	Competent		
L Saphenous Vein Above	Patent	Competent		
L Saphenous Vein Below	Patent	Competent		
Vein of Giacomini	Patent	Competent		
Saphenopopiteal Junction	Not Identified			
S Saphenous Vein	Patent	Competent		
Evidence of D.V.T.				
Above the knee	No			
Popliteal	No			
Below the knee	No			

Notes

RIGHT LOWER LIMB VENOUS DUPLEX ASSESSMENT

Iliac veins not viewed. Flow in the common femoral vein is phasic with respiration and a normal response on Valsalva manoeuvre, suggesting proximal vein patency. All visualised deep veins appear widely patent and competent with no evidence of previous DVT.

All measurements are proximal to the medial malleolus unless otherwise stated.

RIGHT

All visualised superficial veins appear patent and competent.

Assessed by Jack Wilson

Printed on 16/11/2021 at 1:03 pm

Checked by

Reason Varicose vein

Outcome Incompetence - deep, Incompetence - superficial

	Right		Left	
	Patency	Competency	Patency	Competency
Deep Veins				
Common Iliac Vein	Not Assessed		Not Assessed	
External Iliac Vein	Not Assessed		Not Assessed	
Internal Iliac Vein	Not Assessed		Not Assessed	
Common Femoral Vein	Widely Patent	Competent	Widely Patent	Competent
Profunda Vein	Widely Patent	Competent	Widely Patent	Competent
Superficial Femoral Vein	Widely Patent	Competent	Widely Patent	Competent
Popliteal Vein	Widely Patent	Isolated Incompetence	Widely Patent	Competent
Posterior Tibial Vein	Widely Patent	Competent	Widely Patent	Competent
Anterior Tibial Vein	Widely Patent	Competent	Widely Patent	Competent
Peroneal Vein	Widely Patent	Competent	Widely Patent	Competent
Soleal Vein	Not Identified		Not Identified	
Gastrocnemius	Widely Patent	Competent	Widely Patent	Competent
Superficial Veins				
Saphenofemoral Junction	Patent	Incompetent	Patent	Incompetent
L Saphenous Vein Above	Patent	Incompetent	Patent	Incompetent
L Saphenous Vein Below	Patent	Incompetent	Patent	Incompetent
Vein of Giacomini	Patent	Competent	Patent	Competent
Saphenopopliteal Junction	Not Identified		Patent	Incompetent
S Saphenous Vein	Patent	Competent	Patent	Isolated Incompetence
Evidence of D.V.T.				
Above the knee	No		No	
Popliteal	No		No	
Below the knee	No		No	

Notes

BILATERAL LOWER LIMB VENOUS DUPLEX ASSESSMENT

Iliac veins not viewed, bilaterally. Flow in the right and left common femoral vein is phasic with respiration and a normal response on Valsalva manoeuvre, suggesting proximal vein patency, bilaterally. All visualised deep veins appear widely patent and competent with no evidence of previous DVT, bilaterally with the exception of the right popliteal vein which is widely patent but slightly incompetent in the distal vessel.

All measurements are proximal to the medial malleolus unless otherwise stated.

RIGHT

Sapheno-femoral junction (SFJ) is widely patent and incompetent. Long Saphenous vein (LSV) is incompetent and linear along length. 2 Incompetent branches identified in the proximal calf forming medial

Assessed by Jack Wilson

Printed on 16/11/2021 at 1:02 pm

Checked by

calf and anterior calf varicosities.

Transverse (AP) dimensions of LSV:

Proximal thigh- 0.44cm

Mid thigh - 0.54cm

Distal thigh - 0.56cm

Proximal calf- 0.55cm

Mid calf - 0.44cm

Distal calf - 0.38cm

Sapheno-popliteal junction (SPJ) was not identified. Short Saphenous vein (SSV) is competent and is continuous with a competent vein of Giacomini.

LEFT

Sapheno-femoral junction (SFJ) is widely patent and incompetent. Long Saphenous vein (LSV) is incompetent and linear along length. Incompetent branch identified in the proximal calf forming medial calf varicosities.

Transverse (AP) dimensions of LSV:

Proximal thigh- 0.82cm

Mid thigh - 0.52cm

Distal thigh - 0.67cm

Proximal calf- 0.61cm

Mid calf - 0.42cm

Distal calf - 0.34cm

Sapheno-popliteal junction (SPJ) is widely patent and incompetent. Competent vein of Giacomini identified. Short Saphenous vein (SSV) is slightly incompetent proximally. Mid vessel appears tortuous with multiple small, tortuous ?Incompetent branches identified forming posterior calf varicosities. Incompetent perforator to a Gastrocnemius vein identified in the mid calf. Distal SSV appears competent.

Transverse (AP) dimensions of SSV:

Proximal calf- 0.32cm

Mid calf - 0.14cm

Distal calf - 0.24cm

Reason Varicose vein
Outcome DVT negative, Widely patent , Competent

	Right		Left	
Deep Veins	Patency	Competency	Patency	Competency
Common Iliac Vein	<input type="text" value="Not Assessed"/>			
External Iliac Vein	<input type="text" value="Not Assessed"/>			
Internal Iliac Vein	<input type="text" value="Not Assessed"/>			
Common Femoral Vein	<input type="text" value="Widely Patent"/>	<input type="text" value="Competent"/>		
Profunda Vein	<input type="text" value="Widely Patent"/>	<input type="text" value="Competent"/>		
Superficial Femoral Vein	<input type="text" value="Widely Patent"/>	<input type="text" value="Competent"/>		
Popliteal Vein	<input type="text" value="Widely Patent"/>	<input type="text" value="Competent"/>		
Posterior Tibial Vein	<input type="text" value="Widely Patent"/>	<input type="text" value="Competent"/>		
Anterior Tibial Vein	<input type="text" value="Widely Patent"/>	<input type="text" value="Competent"/>		
Peroneal Vein	<input type="text" value="Widely Patent"/>	<input type="text" value="Competent"/>		
Soleal Vein	<input type="text" value="Widely Patent"/>	<input type="text" value="Competent"/>		
Gastrocnemius	<input type="text" value="Widely Patent"/>	<input type="text" value="Competent"/>		
Superficial Veins				
Saphenofemoral Junction	<input type="text" value="Patent"/>	<input type="text" value="Competent"/>		
L Saphenous Vein Above	<input type="text" value="Patent"/>	<input type="text" value="Competent"/>		
L Saphenous Vein Below	<input type="text" value="Patent"/>	<input type="text" value="Competent"/>		
Vein of Giacomini	<input type="text" value="Patent"/>	<input type="text" value="Competent"/>		
Saphenopopiteal Junction	<input type="text" value="Patent"/>	<input type="text" value="Competent"/>		
S Saphenous Vein	<input type="text" value="Patent"/>	<input type="text" value="Competent"/>		
Evidence of D.V.T.				
Above the knee	<input type="text" value="No"/>			
Popliteal	<input type="text" value="No"/>			
Below the knee	<input type="text" value="No"/>			

Notes

RIGHT LOWER LIMB VENOUS DUPLEX ASSESSMENT

Iliac veins not viewed. Flow in the common femoral vein is phasic with respiration and a normal response on Valsalva manoeuvre, suggesting proximal vein patency. All visualised deep veins appear widely patent and competent with no evidence of previous DVT.

All measurements are proximal to the medial malleolus unless otherwise stated.

RIGHT

All visualised superficial veins appear patent and competent.

Assessed by Jack Wilson

Printed on 16/11/2021 at 1:04 pm

Checked by

Reason DVT

Outcome DVT negative, Incompetence - superficial

	Right		Left	
Deep Veins	Patency	Competency	Patency	Competency
Common Iliac Vein	Not Assessed			
External Iliac Vein	Not Assessed			
Internal Iliac Vein	Not Assessed			
Common Femoral Vein	Widely Patent	Competent		
Profunda Vein	Widely Patent	Competent		
Superficial Femoral Vein	Widely Patent	Competent		
Popliteal Vein	Widely Patent	Competent		
Posterior Tibial Vein	Widely Patent	Competent		
Anterior Tibial Vein	Widely Patent	Competent		
Peroneal Vein	Widely Patent	Competent		
Soleal Vein	Widely Patent	Competent		
Gastrocnemius	Widely Patent	Competent		
Superficial Veins				
Saphenofemoral Junction	Patent	Incompetent		
L Saphenous Vein Above	Patent	Incompetent		
L Saphenous Vein Below	Patent	Isolated Incompetence		
Vein of Giacomini	Patent	Competent		
Saphenopopiteal Junction	Not Identified			
S Saphenous Vein	Patent	Competent		
Evidence of D.V.T.				
Above the knee	No			
Popliteal	No			
Below the knee	No			

Notes

RIGHT LOWER LIMB VENOUS DUPLEX ASSESSMENT

Iliac veins not viewed. Flow in the common femoral vein is phasic with respiration and a normal response on Valsalva manoeuvre, suggesting proximal vein patency. All visualised deep veins appear widely patent and competent with no evidence of previous DVT.

All measurements are proximal to the medial malleolus unless otherwise stated.

RIGHT

Sapheno-femoral junction (SFJ) is widely patent and incompetent. Long Saphenous vein (LSV) is widely patent, linear and incompetent in the proximal thigh. Vessel becomes tortuous in the mid thigh with 2 incompetent branches identified forming medial thigh medial calf and anterior calf varicosities (53cm and

Assessed by Jack Wilson

Printed on 16/11/2021 at 2:09 pm

Checked by

48cm). LSV is incompetent and linear in the distal thigh. Competent perforator to the posterior tibial veins identified in the proximal calf (28cm). Proximal to mid calf LSV is competent and linear. Varicose veins communicate with the LSV in the distal thigh at the same level as a competent perforator from the posterior tibial veins (13cm). LSV remains competent to the ankle.

Transverse (AP) dimensions of LSV:

Proximal thigh- 0.58cm

Mid thigh - 0.53cm

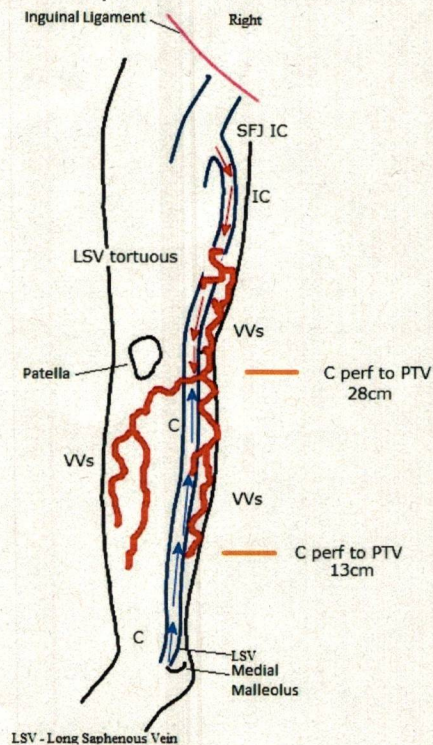
Distal thigh - 0.29cm

Proximal calf- 0.23cm

Mid calf - 0.15cm

Distal calf - 0.38cm

Sapheno-popliteal junction (SPJ) was not identified. Short Saphenous vein (SSV) is competent and is continuous with a competent vein of Giacomini.



Reason Varicose vein

Outcome DVT positive - chronic, Incompetence - deep, Incompetence - superficial

	Right		Left	
Deep Veins	Patency	Competency	Patency	Competency
Common Iliac Vein	Not Assessed		Not Assessed	
External Iliac Vein	Not Assessed		Not Assessed	
Internal Iliac Vein	Not Assessed		Not Assessed	
Common Femoral Vein	Widely Patent	Incompetent	Widely Patent	Competent
Profunda Vein	Widely Patent	Competent	Widely Patent	Competent
Superficial Femoral Vein	Widely Patent	Isolated Incompetence	Widely Patent	Competent
Popliteal Vein	Widely Patent	Competent	Widely Patent	Competent
Posterior Tibial Vein	Widely Patent	Competent	Widely Patent	Competent
Anterior Tibial Vein	Widely Patent	Competent	Widely Patent	Competent
Peroneal Vein	Areas of Thrombus	Old Thrombus	Widely Patent	Competent
Soleal Vein	Not Identified		Not Identified	
Gastrocnemius	Widely Patent		Widely Patent	
Superficial Veins				
Saphenofemoral Junction	Patent	Incompetent	Not Identified	
L Saphenous Vein Above	Patent	Incompetent	Patent	Incompetent
L Saphenous Vein Below	Patent	Isolated Incompetence	Patent	Isolated Incompetence
Vein of Giacomini	Not Identified		Not Identified	
Saphenopopliteal Junction	Patent	Competent	Not Identified	
S Saphenous Vein	Patent	Competent	Patent	Competent
Evidence of D.V.T.				
Above the knee	No		No	
Popliteal	No		No	
Below the knee	Yes	Old	No	

Notes

BILATERAL LOWER LIMB VENOUS DUPLEX ASSESSMENT

RIGHT

Common femoral vein is widely patent but incompetent.

Profunda femoral vein is widely patent and competent with good colour filling and is fully compressible.

Superficial femoral vein is widely patent with good colour filling and is fully compressible but incompetent proximally

Popliteal vein is widely patent and competent with good colour filling and is fully compressible.

Non-occlusive, old thrombus identified in 1 x mid peroneal vein. Other vessel appears widely patent and competent.

All other visualised calf deep veins are widely patent and competent with good colour filling and are fully compressible.

Assessed by Jack Wilson

Printed on 16/11/2021 at 2:42 pm

Checked by

Evidence of chronic right calf DVT detected from this scan.

All measurements are proximal to the medial malleolus unless otherwise stated.

Sapheno-femoral junction (SFJ) is incompetent. Long Saphenous vein (LSV) is incompetent and linear for ~15cm in the proximal thigh. Large incompetent branch identified in the proximal thigh forming extensive medial thigh and calf varicosities. Mid to distal thigh LSV appears competent. Varicosities communicate with the LSV in the distal thigh making the LSV incompetent and highly varicose in the distal thigh and proximal calf. Mid calf LSV appears incompetent. Competent perforator to the posterior tibial veins identified in the distal calf, Very distal LSV appears competent.

Transverse (AP) dimensions of LSV:

Proximal thigh- 0.80cm

Mid thigh - 0.15cm

Mid calf - 0.50cm

Distal calf - 0.26cm

Sapheno-popliteal junction (SPJ) is competent Short Saphenous vein (SSV) is competent along length.

LEFT

Iliac veins not viewed. Flow in the common femoral vein is phasic with respiration and a normal response on Valsalva manoeuvre, suggesting proximal vein patency. All visualised deep veins appear widely patent and competent with no evidence of previous DVT with the exception of the superficial femoral vein which is widely patent but slightly incompetent proximally.

All measurements are proximal to the medial malleolus unless otherwise stated.

Sapheno-femoral junction (SFJ) was not identified ?due to previous treatment. Area of neovascularisation identified in the left groin with small, tortuous ?Incompetent branches identified tracking to the proximal/mid thigh. LSV reforms in the mid thigh via a branch and appears incompetent and linear in the mid to distal thigh. Incompetent branch identified in the very proximal calf forming medial calf varicosities. Proximal calf LSV appears competent. Varicosities communicate with the LSV in the proximal calf making the LSV incompetent for a short section. Competent perforator to the posterior tibial veins identified in the mid calf. LSV then appears competent to the ankle.

Transverse (AP) dimensions of LSV:

Mid thigh - 0.53cm

Distal thigh - 0.53cm

Proximal calf- 0.14cm

Mid calf - 0.34cm

Distal calf - 0.26cm

Sapheno-popliteal junction (SPJ) was not identified. Short Saphenous vein (SSV) is competent and is continuous with a competent posterior thigh vein.

Assessed by Jack Wilson

Printed on 16/11/2021 at 2:42 pm

Checked by

Reason Varicose vein

Outcome Incompetence - superficial

	Right		Left	
	Patency	Competency	Patency	Competency
Deep Veins				
Common Iliac Vein	Not Assessed			
External Iliac Vein	Not Assessed			
Internal Iliac Vein	Not Assessed			
Common Femoral Vein	Widely Patent	Competent		
Profunda Vein	Widely Patent	Competent		
Superficial Femoral Vein	Widely Patent	Competent		
Popliteal Vein	Widely Patent	Competent		
Posterior Tibial Vein	Widely Patent	Competent		
Anterior Tibial Vein	Widely Patent	Competent		
Peroneal Vein	Widely Patent	Competent		
Soleal Vein	Not Identified			
Gastrocnemius	Widely Patent			
Superficial Veins				
Saphenofemoral Junction	Patent	Incompetent		
L Saphenous Vein Above	Patent	Incompetent		
L Saphenous Vein Below	Patent	Isolated Incompetence		
Vein of Giacomini	Not Identified			
Saphenopopiteal Junction	Not Identified			
S Saphenous Vein	Patent	Competent		
Evidence of D.V.T.				
Above the knee	No			
Popliteal	No			
Below the knee	No			

Notes

BILATERAL LOWER LIMB VENOUS DUPLEX ASSESSMENT

RIGHT

Iliac veins not viewed. Flow in the common femoral vein is phasic with respiration and a normal response on Valsalva manoeuvre, suggesting proximal vein patency. All visualised deep veins appear widely patent and competent with no evidence of previous DVT.

All measurements are proximal to the medial malleolus unless otherwise stated.

Sapheno-femoral junction (SFJ) is incompetent. Long Saphenous vein (LSV) is incompetent and linear in the thigh, focal dilatation noted in the mid thigh with LSV diameter increasing to TS-0.81cm. LSV is incompetent and linear in the proximal calf. Incompetent branch identified in the prox/mid calf forming medial

Assessed by Jack Wilson

Printed on 16/11/2021 at 2:43 pm

Checked by

calf varicosities. LSV then appears competent to the ankle.

Transverse (AP) dimensions of LSV:

Proximal thigh- 0.38cm

Mid thigh - 0.44cm

Distal thigh - 0.35cm

Proximal calf- 0.38cm

Mid calf - 0.21cm

Distal calf - 0.21cm

Short saphenous vein (SSV) appears patent and competent along length. Sapheno-popliteal junction and vein of Giacomini not identified due to patient requesting scan to end.

LEFT

Unable to assess left leg veins as patient was unable to tolerate further scanning due to anxiety.

Ultrasound reception informed, appointment team contacted to re-book further appointment for left leg scan.

Assessed by Jack Wilson

Printed on 16/11/2021 at 2:43 pm

Checked by

Reason Varicose vein
Outcome DVT negative, Incompetence - superficial

Right		Left		
Deep Veins	Patency	Competency	Patency	Competency
Common Iliac Vein			Not Assessed	
External Iliac Vein			Not Assessed	
Internal Iliac Vein			Not Assessed	
Common Femoral Vein			Widely Patent	Competent
Profunda Vein			Widely Patent	Competent
Superficial Femoral Vein			Widely Patent	Competent
Popliteal Vein			Widely Patent	Competent
Posterior Tibial Vein			Widely Patent	Competent
Anterior Tibial Vein			Widely Patent	Competent
Peroneal Vein			Widely Patent	Competent
Soleal Vein			Not Identified	
Gastrocnemius			Widely Patent	
Superficial Veins				
Saphenofemoral Junction			Patent	Incompetent
L Saphenous Vein Above			Patent	Incompetent
L Saphenous Vein Below			Patent	Isolated Incompetence
Vein of Giacomini			Patent	Competent
Saphenopopiteal Junction			Patent	Competent
S Saphenous Vein			Patent	Isolated Incompetence
Evidence of D.V.T.				
Above the knee			No	
Popliteal			No	
Below the knee			No	

Notes

LEFT LOWER LIMB VENOUS DUPLEX ASSESSMENT

Iliac veins not viewed. Flow in the common femoral vein is phasic with respiration and a normal response on Valsalva manoeuvre, suggesting proximal vein patency. All visualised deep veins appear widely patent and competent with no evidence of previous DVT.

All measurements are proximal to the medial malleolus unless otherwise stated.

LEFT

Sapheno-femoral junction (SFJ) is incompetent. Long Saphenous vein (LSV) is incompetent and linear in the thigh. 2 x Incompetent branches identified in the proximal thigh (59cm) forming medial and anterior thigh varicosities. Mid to distal thigh LSV remains incompetent and linear. Incompetent branch identified in the

Assessed by Jack Wilson

Printed on 16/11/2021 at 2:44 pm

Checked by

proximal calf (35cm) forming medial calf varicosities. Mid calf LSV is incompetent and linear. Competent perforator to the posterior tibial veins identified in the distal calf (12cm). LSV appears competent at the ankle.

Transverse (AP) dimensions of LSV:

Proximal thigh- 0.60cm

Mid thigh - 0.59cm

Distal thigh - 0.66cm

Proximal calf- 0.56cm

Mid calf - 0.22cm

Distal calf - 0.27cm

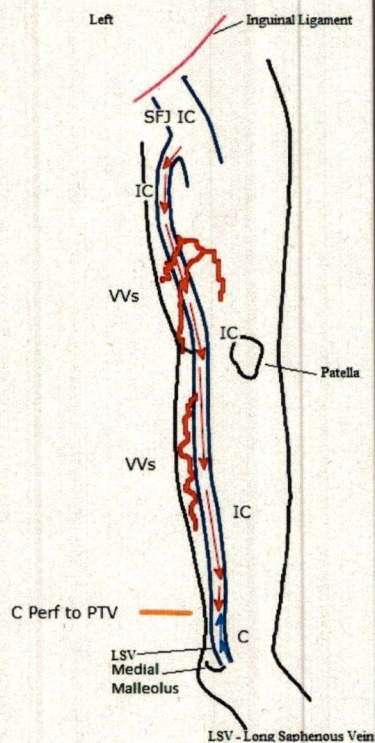
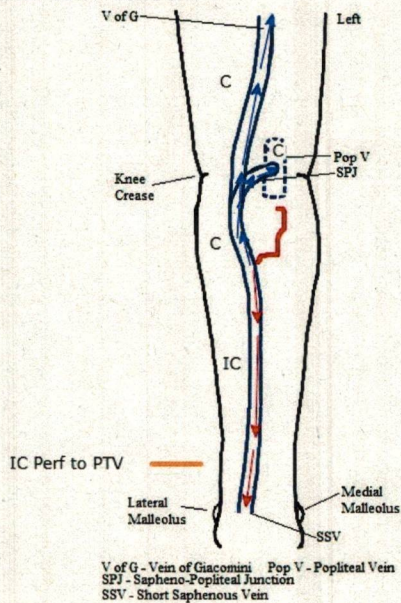
Sapheno-popliteal junction (SPJ) was not identified. Proximal Short Saphenous vein (SSV) is competent and is continuous with a competent vein of Giacomini. Varicosities communicate with the SSV in the proximal calf (37cm). SSV then appears incompetent and linear to the ankle. Incompetent perforator to the posterior tibial veins identified in the distal calf (15cm).

Transverse (AP) dimensions of SSV:

Proximal calf- 0.28cm

Mid calf - 0.24cm

Distal calf - 0.26cm



Reason Varicose vein
Outcome DVT negative, Incompetence - superficial

	Right		Left	
Deep Veins	Patency	Competency	Patency	Competency
Common Iliac Vein	Not Assessed		Not Assessed	
External Iliac Vein	Not Assessed		Not Assessed	
Internal Iliac Vein	Not Assessed		Not Assessed	
Common Femoral Vein	Widely Patent	Competent	Widely Patent	Competent
Profunda Vein	Widely Patent	Competent	Widely Patent	Competent
Superficial Femoral Vein	Widely Patent	Competent	Widely Patent	Competent
Popliteal Vein	Widely Patent	Competent	Widely Patent	Competent
Posterior Tibial Vein	Widely Patent	Competent	Widely Patent	Competent
Anterior Tibial Vein	Widely Patent	Competent	Widely Patent	Competent
Peroneal Vein	Widely Patent	Competent	Widely Patent	Competent
Soleal Vein	Not Identified		Not Identified	
Gastrocnemius	Widely Patent	Competent	Widely Patent	Competent
Superficial Veins				
Saphenofemoral Junction	Patent	Incompetent	Patent	Incompetent
L Saphenous Vein Above	Patent	Incompetent	Patent	Isolated Incompetence
L Saphenous Vein Below	Patent	Isolated Incompetence	Patent	Patent
Vein of Giacomini	Not Identified		Not Identified	
Saphenopopliteal Junction	Not Identified		Not Identified	
S Saphenous Vein	Patent	Competent	Patent	Competent
Evidence of D.V.T.				
Above the knee	No		No	
Popliteal	No		No	
Below the knee	No		No	

Notes

BILATERAL LOWER LIMB VENOUS DUPLEX ASSESSMENT

Iliac veins not viewed, bilaterally. Flow in the right and left common femoral vein is phasic with respiration and a normal response on Valsalva manoeuvre, suggesting proximal vein patency, bilaterally. All visualised deep veins appear widely patent and competent with no evidence of previous DVT., bilaterally.

All measurements are proximal to the medial malleolus unless otherwise stated.

RIGHT

Sapheno-femoral junction (SFJ) is incompetent. Long Saphenous vein (LSV) is incompetent and linear in the thigh. Incompetent branch identified in the distal thigh forming medial calf and medial thigh varicosities. Distal thigh and very proximal calf LSV are competent and linear. Incompetent perforator identified in the

Assessed by Jack Wilson

Printed on 16/11/2021 at 2:46 pm

Checked by

proximal calf (31cm) making the LSV incompetent for a very short section, incompetent branch noted at the same level forming medial calf varicosities. LSV then appears competent and linear to the ankle.

Transverse (AP) dimensions of LSV:

Proximal thigh- 0.93cm

Mid thigh - 1.05cm

Distal thigh - 0.27cm

Proximal calf- 0.43cm

Mid calf - 0.34cm

Distal calf - 0.37cm

Sapheno-popliteal junction (SPJ) was not identified. Short Saphenous vein (SSV) is competent and is continuous with a competent posterior thigh vein.

LEFT

Sapheno-femoral junction (SFJ) is incompetent. Long Saphenous vein (LSV) is incompetent and linear in the very proximal thigh. Incompetent branch identified in the proximal thigh (63cm) forming medial/lateral thigh and medial calf varicosities. LSV remains incompetent for a short section. Further incompetent branch identified in the mid thigh (55cm) forming medial/lateral thigh and medial calf varicosities. LSV appears competent and linear from the mid thigh to the proximal calf. LSV leaves the fascia in the proximal calf and communicates with calf varicosities becoming tortuous and branched in the proximal to mid calf. LSV remains incompetent and returns to the fascia in the distal calf.

Transverse (AP) dimensions of LSV:

Proximal thigh- 0.62cm

Mid thigh - 0.30cm

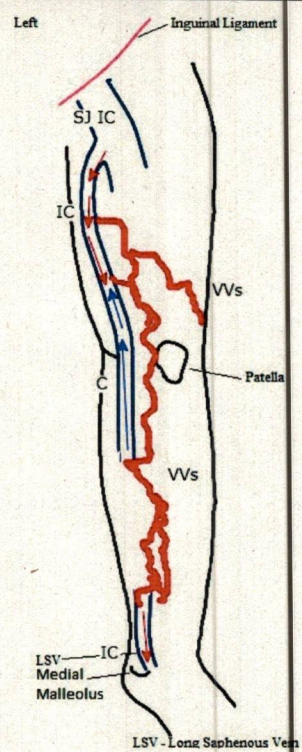
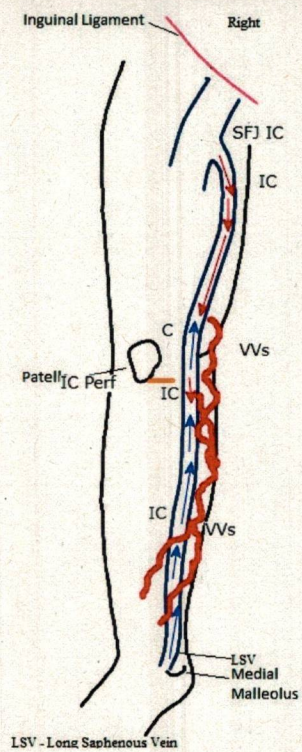
Distal thigh - 0.25cm

Proximal calf-

Mid calf -

Distal calf - 0.37cm

Sapheno-popliteal junction (SPJ) was not identified. Short Saphenous vein (SSV) is competent and is continuous with a competent posterior thigh vein.



Reason Varicose vein
Outcome DVT negative, Incompetence - superficial

	Right		Left	
	Patency	Competency	Patency	Competency
Deep Veins				
Common Iliac Vein	Not Assessed		Not Assessed	
External Iliac Vein	Not Assessed		Not Assessed	
Internal Iliac Vein	Not Assessed		Not Assessed	
Common Femoral Vein	Widely Patent	Competent	Widely Patent	Competent
Profunda Vein	Widely Patent	Competent	Widely Patent	Competent
Superficial Femoral Vein	Widely Patent	Competent	Widely Patent	Competent
Popliteal Vein	Widely Patent	Competent	Widely Patent	Competent
Posterior Tibial Vein	Widely Patent	Competent	Widely Patent	Competent
Anterior Tibial Vein	Widely Patent	Competent	Widely Patent	Competent
Peroneal Vein	Widely Patent	Competent	Widely Patent	Competent
Soleal Vein	Not Identified		Not Identified	
Gastrocnemius	Widely Patent	Competent	Widely Patent	Competent
Superficial Veins				
Saphenofemoral Junction	Patent	?Incompetent	Patent	Competent
L Saphenous Vein Above	Patent	Incompetent	Not Identified	
L Saphenous Vein Below	Patent	Isolated Incompetence	Not Identified	
Vein of Giacomini			Patent	Competent
Saphenopopliteal Junction	Patent		Not Identified	
S Saphenous Vein	Patent		Patent	Competent
Evidence of D.V.T.				
Above the knee	No		No	
Popliteal	No		No	
Below the knee	No		No	

Notes

BILATERAL LOWER LIMB VENOUS DUPLEX ASSESSMENT

Iliac veins not viewed, bilaterally. Flow in the right and left common femoral vein is phasic with respiration and a normal response on Valsalva manoeuvre, suggesting proximal vein patency, bilaterally. All visualised deep veins appear widely patent and competent with no evidence of previous DVT, bilaterally.

All measurements are proximal to the medial malleolus unless otherwise stated.

RIGHT

Sapheno-femoral junction (SFJ) appears competent however, proximal thigh LSV appears incompetent ?Incompetent junction. Long Saphenous vein (LSV) is incompetent and linear in the thigh. Proximal calf LSV is incompetent. Incompetent branch identified in the mid calf (26cm) forming medial calf varicosities. LSV

Assessed by Jack Wilson

Printed on 16/11/2021 at 2:48 pm

Checked by

then appears competent to the ankle.

Sapheno-popliteal junction (SPJ) is competent. Short Saphenous vein (SSV) is competent along length.

Transverse (AP) dimensions of LSV:

Proximal thigh- 0.44cm

Mid thigh - 0.44cm

Distal thigh - 0.39cm

Proximal calf- 0.45cm

Mid calf - 0.26cm

Distal calf - 0.25cm

LEFT

Sapheno-femoral junction (SFJ) is competent. Long Saphenous vein (LSV) is linear, and competent for a very short section. Proximal thigh to distal calf LSV was not identified due to previous harvest.

Sapheno-popliteal junction (SPJ) was not identified. Short Saphenous vein (SSV) is competent and is continuous with a competent vein of Giacomini.

Reason Varicose vein
Outcome Incompetence - superficial

	Right		Left	
Deep Veins	Patency	Competency	Patency	Competency
Common Iliac Vein			<input type="text" value="Not Assessed"/>	
External Iliac Vein			<input type="text" value="Not Assessed"/>	
Internal Iliac Vein			<input type="text" value="Not Assessed"/>	
Common Femoral Vein			<input type="text" value="Widely Patent"/>	<input type="text" value="Competent"/>
Profunda Vein			<input type="text" value="Widely Patent"/>	<input type="text" value="Competent"/>
Superficial Femoral Vein			<input type="text" value="Widely Patent"/>	<input type="text" value="Competent"/>
Popliteal Vein			<input type="text" value="Widely Patent"/>	<input type="text" value="Competent"/>
Posterior Tibial Vein			<input type="text" value="Widely Patent"/>	<input type="text" value="Competent"/>
Anterior Tibial Vein			<input type="text" value="Widely Patent"/>	<input type="text" value="Competent"/>
Peroneal Vein			<input type="text" value="Widely Patent"/>	<input type="text" value="Competent"/>
Soleal Vein			<input type="text" value="Widely Patent"/>	<input type="text" value="Competent"/>
Gastrocnemius			<input type="text" value="Widely Patent"/>	<input type="text" value="Competent"/>
Superficial Veins				
Saphenofemoral Junction			<input type="text" value="Patent"/>	<input type="text" value="Competent"/>
L Saphenous Vein Above			<input type="text" value="Patent"/>	<input type="text" value="Competent"/>
L Saphenous Vein Below			<input type="text" value="Patent"/>	<input type="text" value="Isolated Incompetence"/>
Vein of Giacomini			<input type="text" value="Not Identified"/>	
Saphenopopliteal Junction			<input type="text" value="Patent"/>	<input type="text" value="Competent"/>
S Saphenous Vein			<input type="text" value="Patent"/>	<input type="text" value="Competent"/>
Evidence of D.V.T.				
Above the knee			<input type="text" value="No"/>	
Popliteal			<input type="text" value="No"/>	
Below the knee			<input type="text" value="No"/>	

Notes

LEFT LOWER LIMB VENOUS DUPLEX ASSESSMENT

Iliac veins not viewed. Flow in the common femoral vein is phasic with respiration and a normal response on Valsalva manoeuvre, suggesting proximal vein patency. All visualised deep veins appear widely patent and competent with no evidence of previous DVT.

All measurements are proximal to the medial malleolus unless otherwise stated.

LEFT

Sapheno-femoral junction (SFJ) is competent. Long Saphenous vein (LSV) is competent and linear in the thigh. LSV becomes incompetent in the proximal calf. Incompetent branch identified in the mid/distal calf forming anterior calf varicosities. LSV is then competent to the ankle.

Assessed by Jack Wilson

Printed on 16/11/2021 at 2:50 pm

Checked by

Transverse (AP) dimensions of LSV:

Proximal thigh- 0.50cm

Mid thigh - 0.42cm

Distal thigh - 0.54cm

Proximal calf- 0.39cm

Mid calf - 0.40cm

Distal calf - 0.46cm

Sapheno-popliteal junction (SPJ) is competent, Short Saphenous vein (SSV) is competent along length.

Assessed by Jack Wilson

Printed on 16/11/2021 at 2:50 pm

Checked by

Reason Varicose vein

Outcome DVT equivocal, Incompetence - deep, Incompetence - superficial

	Right		Left	
	Patency	Competency	Patency	Competency
Deep Veins				
Common Iliac Vein	Not Assessed		Not Assessed	
External Iliac Vein	Not Assessed		Not Assessed	
Internal Iliac Vein	Not Assessed		Not Assessed	
Common Femoral Vein	Widely Patent	Slight Incompetence	Widely Patent	Competent
Profunda Vein	Widely Patent	Competent	Widely Patent	Competent
Superficial Femoral Vein	Widely Patent	Slight Incompetence	Widely Patent	Competent
Popliteal Vein	Widely Patent	Competent	Widely Patent	Competent
Posterior Tibial Vein	Patent	Competent		
Anterior Tibial Vein	Patent	Competent		
Peroneal Vein	Patent	Competent		
Soleal Vein	Not Identified			
Gastrocnemius	Patent			
Superficial Veins				
Saphenofemoral Junction	Areas of Thrombus	Old Thrombus	Areas of Thrombus	Old Thrombus
L Saphenous Vein Above	Patent	Competent	Patent	Slight Incompetence
L Saphenous Vein Below	Patent	Competent	Patent	Slight Incompetence
Vein of Giacomini	Not Identified			
Saphenopopliteal Junction	Areas of Thrombus	Old Thrombus		
S Saphenous Vein	Patent	Competent		
Evidence of D.V.T.				
Above the knee	No		No	
Popliteal	No		No	
Below the knee	No		Cannot Exclude	

Notes

BILATERAL LOWER LIMB VENOUS DUPLEX ASSESSMENT

*Challenging scan due to pulsatile flow in veins and patients poor mobility. Some poor images obtained.

?Reliability of competencies.

RIGHT

Iliac veins not viewed. Flow in the common femoral vein is phasic with respiration and a normal response on Valsalva manoeuvre, suggesting proximal vein patency.

Common femoral vein appears widely patent with good colour filling and is fully compressible but slightly incompetent.

Profunda femoral vein appears widely patent and competent with good colour filling and is fully compressible.

Superficial femoral vein appears widely patent with good colour filling and is fully compressible but slightly incompetent.

Assessed by Jack Wilson

Printed on 16/11/2021 at 2:51 pm

Checked by

Popliteal vein appears widely patent and competent with good colour filling and is fully compressible. Calf vessels were difficult to visualise due to oedema and hostile skin however appear patent and competent with reasonable colour filling and are fully compressible.

All measurements are proximal to the medial malleolus unless otherwise stated.

Sapheno-femoral junction (SFJ) is competent with non-occlusive old superficial thrombophlebitis identified. Long Saphenous vein (LSV) is competent along length. Sapheno-popliteal junction (SPJ) is competent with non-occlusive old superficial thrombophlebitis identified. Short Saphenous vein (SSV) is competent and is continuous with a competent posterior thigh vein.

LEFT

Iliac veins not viewed. Flow in the common femoral vein is phasic with respiration and a normal response on Valsalva manoeuvre, suggesting proximal vein patency. All visualised deep veins proximal to and including the popliteal vein appear widely patent and competent with good colour filling and are fully compressible.

Calf vessels were obscured by dressings- unable to exclude calf DVT.

All measurements are proximal to the medial malleolus unless otherwise stated.

Sapheno-femoral junction (SFJ) appears competent with non-occlusive old superficial thrombophlebitis, however proximal Long Saphenous vein (LSV) is incompetent ?Incompetent junction. LSV appears incompetent in the thigh. Incompetent branch identified in the very proximal calf. LSV then appears competent in the proximal calf. Mid to distal calf LSV was obscured by dressings.

Transverse (AP) dimensions of LSV:

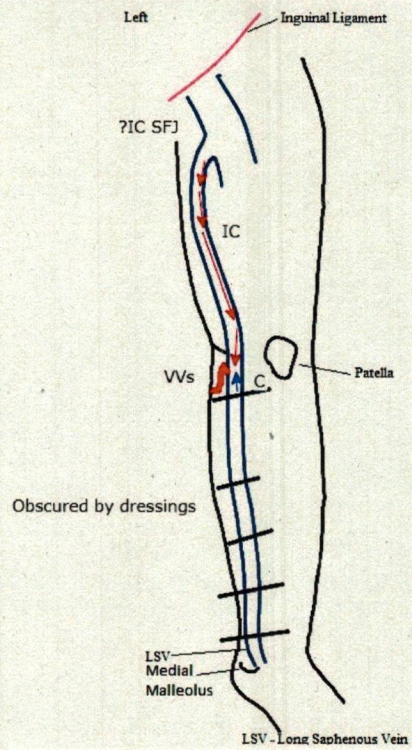
Proximal thigh- 0.69cm

Mid thigh - 0.76cm

Distal thigh - 0.65cm

Proximal calf-0.40cm

Sapheno-popliteal junction (SPJ) appears competent. Proximal Short Saphenous vein (SSV) is competent and is continuous with a competent posterior thigh vein. Mid to distal SSV was obscured by dressings.



Reason Varicose vein

Outcome DVT negative, Superficial thrombophlebitis, Incompetence - superficial

	Right		Left	
	Patency	Competency	Patency	Competency
Deep Veins				
Common Iliac Vein	Not Assessed		Not Assessed	
External Iliac Vein	Not Assessed		Not Assessed	
Internal Iliac Vein	Not Assessed		Not Assessed	
Common Femoral Vein	Widely Patent	Competent	Widely Patent	Competent
Profunda Vein	Widely Patent	Competent	Widely Patent	Competent
Superficial Femoral Vein	Widely Patent	Competent	Widely Patent	Competent
Popliteal Vein	Widely Patent	Competent	Widely Patent	Competent
Posterior Tibial Vein	Widely Patent	Competent	Widely Patent	Competent
Anterior Tibial Vein	Widely Patent	Competent	Widely Patent	Competent
Peroneal Vein	Widely Patent	Competent	Widely Patent	Competent
Soleal Vein	Not Identified		Not Identified	
Gastrocnemius	Widely Patent		Widely Patent	
Superficial Veins				
Saphenofemoral Junction	Patent	Incompetent	Patent	Incompetent
L Saphenous Vein Above	Patent	Incompetent	Patent	Competent
L Saphenous Vein Below	Patent	Competent	Patent	
Vein of Giacomini				
Saphenopopiteal Junction	Patent	Competent	Patent	Incompetent
S Saphenous Vein	Areas of Thrombus	Mixed/Old Thrombus	Areas of Thrombus	Old Thrombus
Evidence of D.V.T.				
Above the knee	No		No	
Popliteal	No		No	
Below the knee	No		No	

Notes

BILATERAL LOWER LIMB VENOUS DUPLEX ASSESSMENT

Iliac veins not viewed, bilaterally. Flow in the right and left common femoral vein is phasic with respiration and a normal response on Valsalva manoeuvre, suggesting proximal vein patency, bilaterally. All visualised deep veins appear widely patent and competent with no evidence of previous DVT, bilaterally.

All measurements are proximal to the medial malleolus unless otherwise stated.

RIGHT

Sapheno-femoral junction (SFJ) is incompetent. Long Saphenous vein (LSV) is incompetent and linear in the thigh. Incompetent branch identified in the distal thigh (50cm) forming medial thigh and medial calf varicosities. LSV then remains competent to the ankle.

Assessed by Jack Wilson

Printed on 16/11/2021 at 2:53 pm

Checked by

Transverse (AP) dimensions of LSV:

Proximal thigh- 0.48cm

Mid thigh - 0.49cm

Distal thigh - 0.20cm

Proximal calf- 0.2cm

Mid calf - 0.14cm

Distal calf - 0.15cm

Sapheno-popliteal junction (SPJ) is competent. Short Saphenous vein (SSV) is competent proximally. Non-occlusive mixed and old superficial thrombophlebitis identified in the mid to distal vessel. Incompetent branch identified in the distal calf (14cm) forming posterior, distal calf varicosities. SSV remains incompetent to the ankle.

Transverse (AP) dimensions of SSV:

Proximal calf- 0.27cm

Mid calf - unable to measure due to superficial thrombophlebitis.

Distal calf - 0.21cm

LEFT

Sapheno-femoral junction (SFJ) is incompetent. Long Saphenous vein (LSV) is incompetent in the thigh with a tortuous section noted in the mid thigh. Incompetent branch identified in the distal thigh (47cm) forming medial thigh, medial calf and posterior calf varicosities. LSV then appears incompetent to the ankle.

Transverse (AP) dimensions of LSV:

Proximal thigh- 0.46cm

Mid thigh - 0.43cm

Distal thigh - 0.36cm

Proximal calf- 0.6cm

Mid calf - 0.21cm

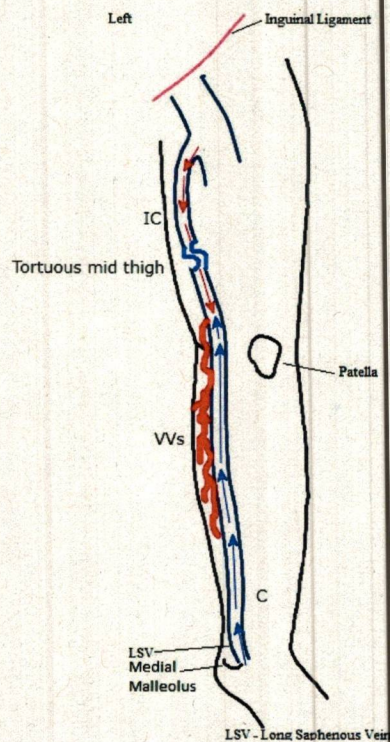
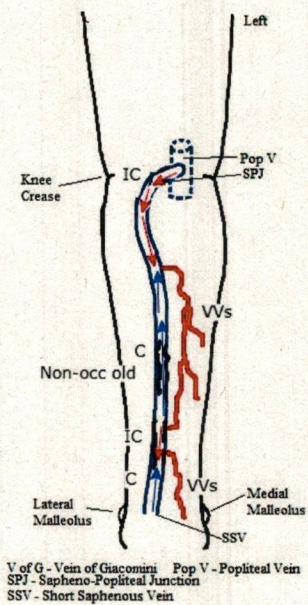
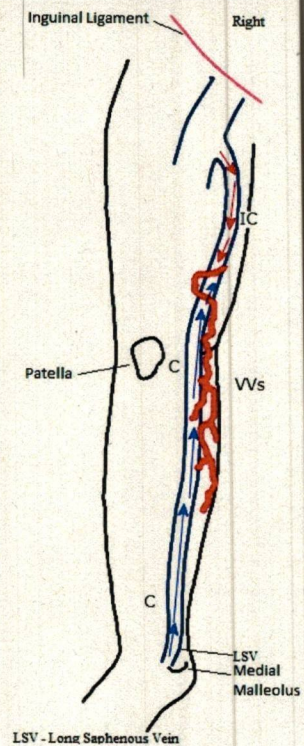
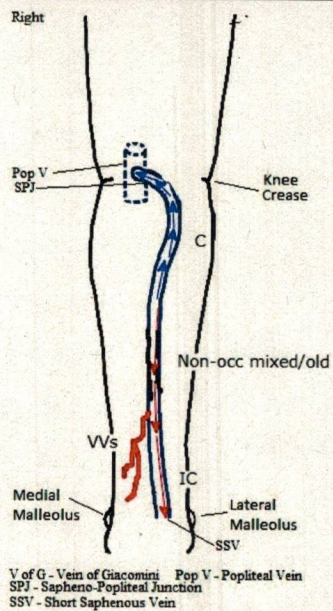
Distal calf - 0.19cm

Sapheno-popliteal junction (SPJ) is incompetent. Short Saphenous vein (SSV) is competent proximally. Incompetent branch identified in the proximal calf (29cm) forming posterior calf varicosities. SSV then appears competent with non-occlusive old superficial thrombophlebitis identified. Varicosities communicate with the SSV in the distal calf (14cm) making the SSV incompetent for a short section. Further incompetent branch identified in the distal calf (12cm) forming posterior calf varicosities. Distal SSV appears competent.

Proximal calf- 0.30cm

Mid calf - 0.17cm

Distal calf - 0.22cm



Reason Varicose vein

Outcome DVT negative, Incompetence - superficial

	Right		Left	
	Patency	Competency	Patency	Competency
Deep Veins				
Common Iliac Vein	Not Assessed		Not Assessed	
External Iliac Vein	Not Assessed		Not Assessed	
Internal Iliac Vein	Not Assessed		Not Assessed	
Common Femoral Vein	Widely Patent	Competent	Widely Patent	Competent
Profunda Vein	Widely Patent	Competent	Widely Patent	Competent
Superficial Femoral Vein	Widely Patent	Competent	Widely Patent	Competent
Popliteal Vein	Widely Patent	Competent	Widely Patent	Competent
Posterior Tibial Vein	Widely Patent	Competent	Widely Patent	Competent
Anterior Tibial Vein	Widely Patent	Competent	Widely Patent	Competent
Peroneal Vein	Widely Patent	Competent	Widely Patent	Competent
Soleal Vein	Widely Patent	Competent	Widely Patent	Competent
Gastrocnemius	Widely Patent	Competent	Widely Patent	Competent
Superficial Veins				
Saphenofemoral Junction	Patent	Incompetent	Patent	Incompetent
L Saphenous Vein Above	Patent	Isolated Incompetence	Patent	Incompetent
L Saphenous Vein Below	Patent	Competent	Patent	Isolated Incompetence
Vein of Giacomini	Not Identified		Patent	Incompetent
Saphenopopliteal Junction	Not Identified		Patent	
S Saphenous Vein	Patent	Competent	Patent	
Evidence of D.V.T.				
Above the knee	No		No	
Popliteal	No		No	
Below the knee	No		No	

Notes

BILATERAL LOWER LIMB VENOUS DUPLEX ASSESSMENT

Iliac veins not viewed, bilaterally. Flow in the right and left common femoral vein is phasic with respiration and a normal response on Valsalva manoeuvre, suggesting proximal vein patency, bilaterally. All visualised deep veins appear widely patent and competent with no evidence of previous DVT, bilaterally.

All measurements are proximal to the medial malleolus unless otherwise stated.

RIGHT

Large, tortuous branch communicating with the Sapheno-femoral junction (SFJ), tracking proximally? Pelvic incompetence. SFJ is incompetent. Long Saphenous vein (LSV) is incompetent in the proximal thigh. Incompetent branch identified in the proximal thigh (69cm) forming medial thigh, anterior calf and posterior

Assessed by Jack Wilson

Printed on 16/11/2021 at 2:55 pm

Checked by

calf varicosities. LSV appears competent and linear in the distal thigh. Vessel then becomes incompetent in the proximal calf and remains incompetent and linear to the ankle.

Transverse (AP) dimensions of LSV:

Proximal thigh- 0.84cm

Mid thigh - 0.46cm

Distal thigh - 0.33cm

Proximal calf- 0.41cm

Mid calf - 0.38cm

Distal calf - 0.35cm

Sapheno-popliteal junction (SPJ) and vein of Giacomini were not identified due to very small calibre proximal Short Saphenous vein (SSV) ?Origin of SSV. SSV is competent along length.

LEFT

Large, tortuous branch communicating with the Sapheno-femoral junction (SFJ), tracking proximally ?Pelvic incompetence. SFJ is incompetent. Long Saphenous vein (LSV) is incompetent but linear from the proximal thigh to the proximal calf. Vein of Giacomini communicates with the LSV in the mid thigh (59cm). Incompetent branch identified in the proximal calf (32cm) forming posterior/medial calf varicosities. LSV then appears competent to the ankle.

Transverse (AP) dimensions of LSV:

Proximal thigh- 0.45cm

Mid thigh - 0.63cm

Distal thigh - 0.59cm

Proximal calf- 0.62cm

Mid calf - 0.31cm

Distal calf - 0.32cm

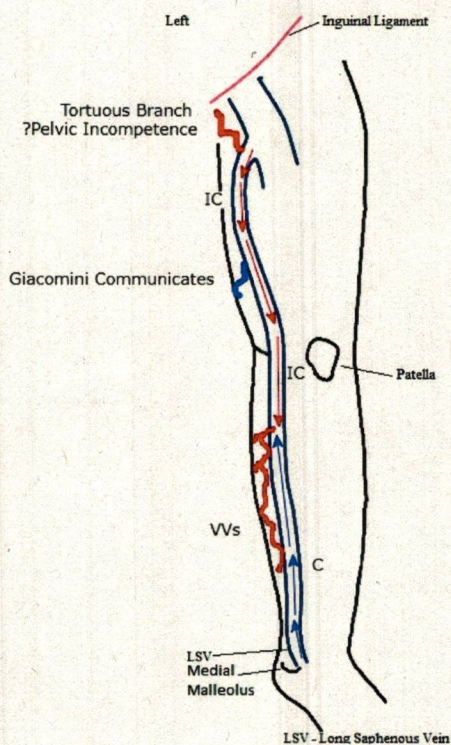
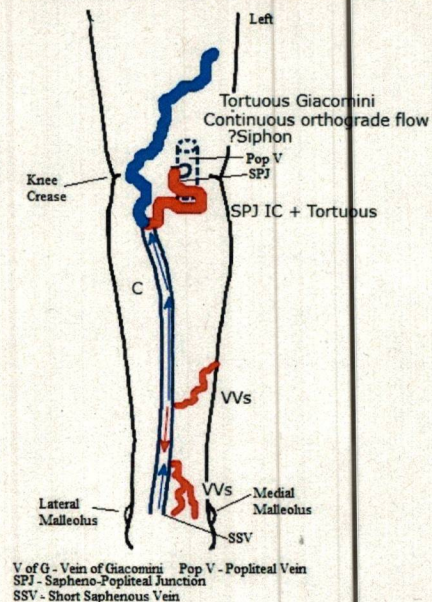
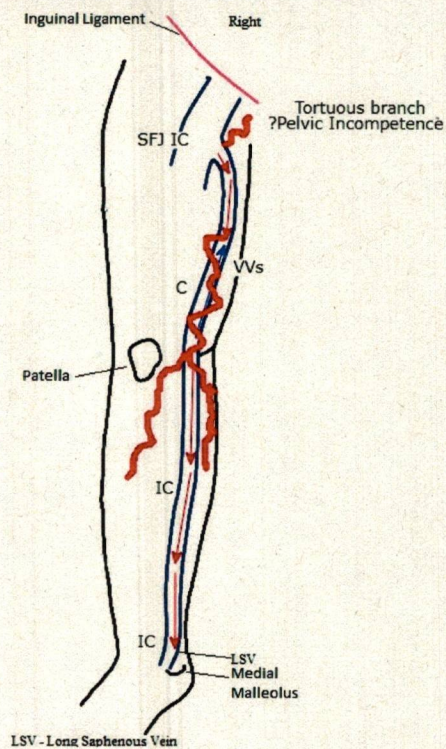
Sapheno-popliteal junction (SPJ) is incompetent and very tortuous. Vein of Giacomini appears tortuous with continuous orthograde flow identified after augmentation of the calf ?Siphon. Short Saphenous Vein (SSV) is patent and competent from the proximal to distal calf. Varicose veins communicate with the SSV in the distal calf (20cm) making the SSV incompetent for a short section. Incompetent branch identified in the distal calf (15cm) forming posterior calf varicosities.

Transverse (AP) dimensions of SSV:

Proximal calf- 0.39cm

Mid calf - 0.23cm

Distal calf - 0.29cm



Right		Left	
Deep Veins	Patency	Patency	Competency
Common Iliac Vein		Not Assessed	
External Iliac Vein		Not Assessed	
Internal Iliac Vein		Not Assessed	
Common Femoral Vein		Widely Patent	Competent
Profunda Vein		Widely Patent	Competent
Superficial Femoral Vein		Widely Patent	Competent
Popliteal Vein		Widely Patent	Competent
Posterior Tibial Vein		Widely Patent	Competent
Anterior Tibial Vein		Widely Patent	Competent
Peroneal Vein		Widely Patent	Competent
Soleal Vein		Not Identified	
Gastrocnemius		Widely Patent	Competent
Superficial Veins			
Saphenofemoral Junction		Not Identified	
L Saphenous Vein Above		Patent	Incompetent
L Saphenous Vein Below		Patent	Incompetent
Vein of Giacomini		Not Identified	
Saphenopopiteal Junction		Patent	
S Saphenous Vein		Patent	
Evidence of D.V.T.			
Above the knee		No	
Popliteal		No	
Below the knee		No	

Notes

LEFT LOWER LIMB VENOUS DUPLEX ASSESSMENT

Iliac veins not viewed. Flow in the common femoral vein is phasic with respiration and a normal response on Valsalva manoeuvre, suggesting proximal vein patency. All visualised deep veins appear widely patent and competent with no evidence of previous DVT.

All measurements are proximal to the medial malleolus unless otherwise stated.

LEFT

Sapheno-femoral junction (SFJ) was not identified due to previous treatment. Multiple small, tortuous incompetent branches noted in the left groin ?Neovascularisation. Long Saphenous vein reforms in the groin via a branch(LSV) and appears incompetent and linear in the thigh. Incompetent perforator to the SFV

Assessed by Jack Wilson

Printed on 16/11/2021 at 2:56 pm

Checked by

identified in the mid thigh (50cm). Incompetent branch identified at the level of the knee crease forming medial calf varicosities. LSV leaves the fascia in the very proximal calf and becomes tortuous, forming medial/anterior calf varicosities. LSV reforms in the proximal calf (28cm) via an incompetent perforator and appears incompetent in the proximal to mid calf. LSV becomes highly tortuous and branched in the distal calf (11cm) forming medial calf varicosities.

Transverse (AP) dimensions of LSV:

Proximal thigh- 0.65cm

Mid thigh - 0.62cm

Distal thigh - 0.77cm

Proximal calf- 0.43cm

Mid calf - 0.51cm

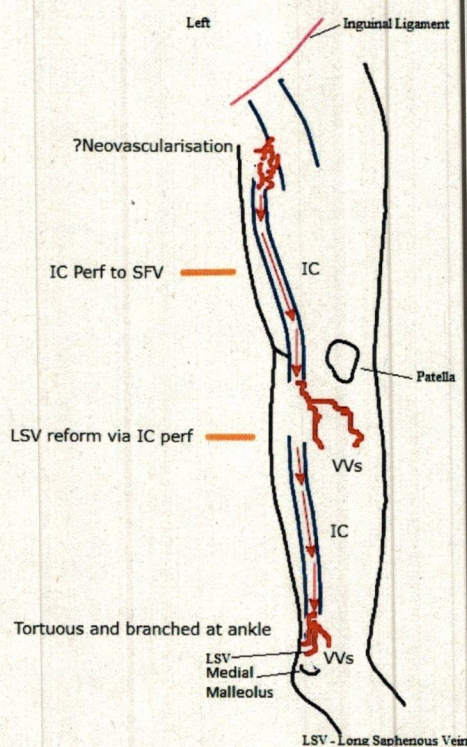
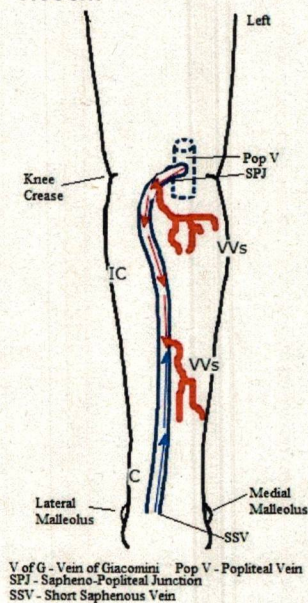
Sapheno-popliteal junction (SPJ) is incompetent. The proximal to mid Short Saphenous vein (SSV) is incompetent with incompetent branches at the proximal calf (37cm) and mid calf (24cm) forming medial calf varicosities. Distal SSV appears competent.

Transverse (AP) dimensions of SSV:

Proximal calf- 0.69cm

Mid calf - .35cm

Distal calf -0.39cm



Reason Varicose vein

Outcome DVT negative, Incompetence - superficial

	Right		Left	
	Patency	Competency	Patency	Competency
Deep Veins				
Common Iliac Vein	Not Assessed		Not Assessed	
External Iliac Vein	Not Assessed		Not Assessed	
Internal Iliac Vein	Not Assessed		Not Assessed	
Common Femoral Vein	Widely Patent	Competent	Widely Patent	Competent
Profunda Vein	Widely Patent	Competent	Widely Patent	Competent
Superficial Femoral Vein	Widely Patent	Competent	Widely Patent	Competent
Popliteal Vein	Widely Patent	Competent	Widely Patent	Competent
Posterior Tibial Vein	Widely Patent	Competent	Widely Patent	Competent
Anterior Tibial Vein	Widely Patent	Competent	Widely Patent	Competent
Peroneal Vein	Widely Patent	Competent	Widely Patent	Competent
Soleal Vein	Not Identified		Not Identified	
Gastrocnemius	Widely Patent	Competent	Widely Patent	Competent
Superficial Veins				
Saphenofemoral Junction	Patent	Competent	Patent	?Incompetent
L Saphenous Vein Above	Patent	Competent	Patent	Incompetent
L Saphenous Vein Below	Patent	Competent	Patent	Incompetent
Vein of Giacomini	Patent	Competent	Patent	Competent
Saphenopopliteal Junction	Not Identified		Not Identified	
S Saphenous Vein	Patent	Competent	Patent	Competent
Evidence of D.V.T.				
Above the knee	No		No	
Popliteal	No		No	
Below the knee	No		No	

Notes

BILATERAL LOWER LIMB VENOUS DUPLEX ASSESSMENT

Iliac veins not viewed, bilaterally. Flow in the right and left common femoral vein is phasic with respiration and a normal response on Valsalva manoeuvre, suggesting proximal vein patency, bilaterally. All visualised deep veins appear widely patent and competent with no evidence of previous DVT, bilaterally.

All measurements are proximal to the medial malleolus unless otherwise stated.

RIGHT

Sapheno-femoral junction (SFJ) is competent. Long Saphenous vein (LSV) is competent along length. Sapheno-popliteal junction (SPJ) was not identified. Short Saphenous vein (SSV) is competent along length and is continuous with a competent vein of Giacomini.

Assessed by Jack Wilson

Printed on 16/11/2021 at 2:58 pm

Checked by

LEFT

Sapheno-femoral junction (SFJ) appears competent, however, proximal Long Saphenous vein (LSV) is incompetent ?Incompetent SFJ. LSV appears incompetent along length. Incompetent branch noted at the level of the knee crease forming small medial calf varicosities.

Transverse (AP) dimensions of LSV:

Proximal thigh- 0.41cm

Mid thigh - 0.31cm

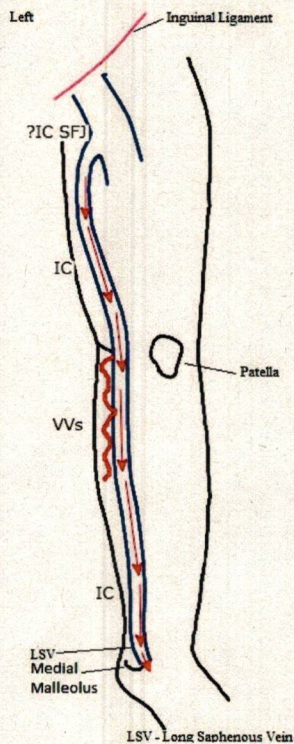
Distal thigh - 0.31cm

Proximal calf- 0.27cm

Mid calf - 0.22cm

Distal calf - 0.28cm

Sapheno-popliteal junction (SPJ) was not identified. Short Saphenous vein (SSV) is competent and is continuous with a competent vein of Giacomini.



Reason

DVT

Outcome

DVT negative, Incompetence - superficial

	Right		Left	
Deep Veins	Patency	Competency	Patency	Competency
Common Iliac Vein	Not Assessed		Not Assessed	
External Iliac Vein	Not Assessed		Not Assessed	
Internal Iliac Vein	Not Assessed		Not Assessed	
Common Femoral Vein	Widely Patent	Competent	Widely Patent	Competent
Profunda Vein	Widely Patent	Competent	Widely Patent	Competent
Superficial Femoral Vein	Widely Patent	Competent	Widely Patent	Competent
Popliteal Vein	Widely Patent	Competent	Widely Patent	Competent
Posterior Tibial Vein	Widely Patent	Competent	Widely Patent	Competent
Anterior Tibial Vein	Widely Patent	Competent	Widely Patent	Competent
Peroneal Vein	Widely Patent	Competent	Widely Patent	Competent
Soleal Vein	Widely Patent	Competent	Widely Patent	Competent
Gastrocnemius	Widely Patent	Competent	Widely Patent	Competent
Superficial Veins				
Saphenofemoral Junction	Patent	Competent	Patent	Incompetent
L Saphenous Vein Above	Patent	Competent	Patent	Isolated Incompetence
L Saphenous Vein Below	Patent	Competent	Patent	Competent
Vein of Giacomini	Patent	Competent	Patent	Competent
Saphenopopliteal Junction	Not Identified		Patent	Competent
S Saphenous Vein	Patent	Competent	Patent	Competent
Evidence of D.V.T.				
Above the knee	No		No	
Popliteal	No		No	
Below the knee	No		No	

Notes**BILATERAL LOWER LIMB VENOUS DUPLEX ASSESSMENT**

Iliac veins not viewed, bilaterally. Flow in the right and left common femoral vein is phasic with respiration and a normal response on Valsalva manoeuvre, suggesting proximal vein patency, bilaterally. All visualised deep veins appear widely patent and competent with no evidence of previous DVT, bilaterally.

All measurements are proximal to the medial malleolus unless otherwise stated.

RIGHT

Sapheno-femoral junction (SFJ) is competent. Long Saphenous vein (LSV) is competent along length.

Sapheno-popliteal junction (SPJ) was not identified. Short Saphenous vein (SSV) is competent and is

Assessed by Jack Wilson

Printed on 16/11/2021 at 3:00 pm

Checked by

continuous with a competent vein of Giacomini. Incompetent branch identified at the distal ankle forming lateral ankle/foot varicosities.

Transverse (AP) dimensions of SSV:

Proximal calf- 0.32cm

Mid calf - 0.21cm

Distal calf - 0.21cm

LEFT

Sapheno-femoral junction (SFJ) is incompetent. Proximal Long Saphenous vein (LSV) is incompetent and linear. Incompetent branch identified in the proximal/mid thigh (60cm) forming medial/anterior thigh and medial calf varicosities. LSV then remains competent to the ankle.

Transverse (AP) dimensions of LSV:

Proximal thigh- 0.47cm

Mid thigh - 0.32cm

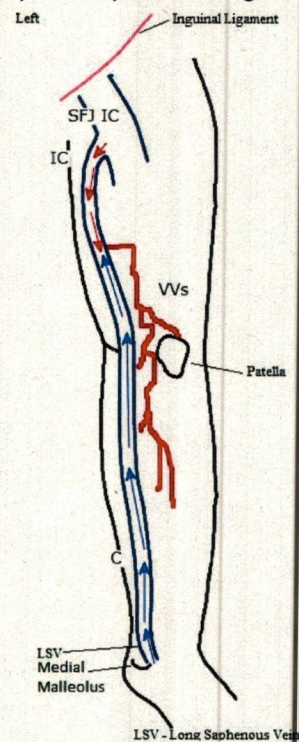
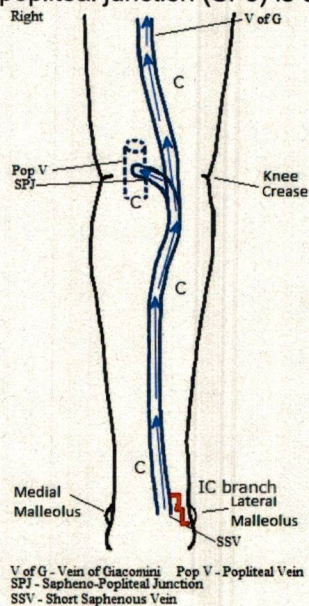
Distal thigh - 0.19cm

Proximal calf- 0.18cm

Mid calf - 0.24cm

Distal calf - 0.28cm

Sapheno-popliteal junction (SPJ) is competent. Short Saphenous vein (SSV) is competent along length.



Assessed by Jack Wilson

Printed on 16/11/2021 at 3:41 pm

Checked by

Reason Varicose vein
Outcome Normal

	Right		Left	
	Patency	Competency	Patency	Competency
Deep Veins				
Common Iliac Vein	Not Assessed			
External Iliac Vein	Not Assessed			
Internal Iliac Vein	Not Assessed			
Common Femoral Vein	Widely Patent	Competent		
Profunda Vein	Widely Patent	Competent		
Superficial Femoral Vein	Widely Patent	Competent		
Popliteal Vein	Widely Patent	Competent		
Posterior Tibial Vein	Widely Patent	Competent		
Anterior Tibial Vein	Widely Patent	Competent		
Peroneal Vein	Widely Patent	Competent		
Soleal Vein	Widely Patent	Competent		
Gastrocnemius	Widely Patent	Competent		
Superficial Veins				
Saphenofemoral Junction	Patent			
L Saphenous Vein Above	Patent			
L Saphenous Vein Below	Patent			
Vein of Giacomini	Patent			
Saphenopopiteal Junction	Not Identified			
S Saphenous Vein	Patent			
Evidence of D.V.T.				
Above the knee	No			
Popliteal	No			
Below the knee	No			

Notes

RIGHT LOWER LIMB VENOUS DUPLEX ASSESSMENT

Iliac veins not viewed. Flow in the common femoral vein is phasic with respiration and a normal response on Valsalva manoeuvre, suggesting proximal vein patency. All visualised deep veins appear widely patent and competent with no evidence of previous DVT.

All measurements are proximal to the medial malleolus unless otherwise stated.

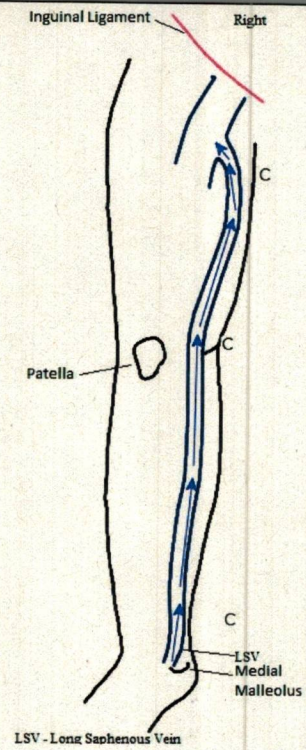
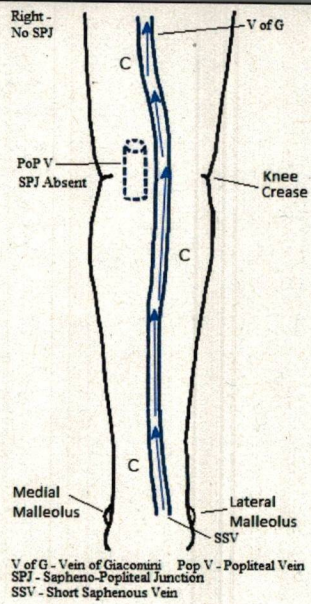
RIGHT

Sapheno-femoral junction (SFJ) is competent. Long Saphenous vein (LSV) is competent along length. Sapheno-popliteal junction (SPJ) was not identified. Short Saphenous vein (SSV) is competent along length and is continuous with a competent vein of Giacomini.

Assessed by Jack Wilson

Printed on 16/11/2021 at 3:02 pm

Checked by



	Right		Left	
Deep Veins	Patency	Competency	Patency	Competency
Common Iliac Vein	Not Assessed		Not Assessed	
External Iliac Vein	Not Assessed		Not Assessed	
Internal Iliac Vein	Not Assessed		Not Assessed	
Common Femoral Vein	Widely Patent	Competent	Widely Patent	Competent
Profunda Vein	Widely Patent	Competent	Widely Patent	Competent
Superficial Femoral Vein	Widely Patent	Competent	Widely Patent	Competent
Popliteal Vein	Widely Patent	Competent	Widely Patent	Competent
Posterior Tibial Vein	Widely Patent	Competent	Widely Patent	Competent
Anterior Tibial Vein	Widely Patent	Competent	Widely Patent	Competent
Peroneal Vein	Widely Patent	Competent	Widely Patent	Competent
Soleal Vein	Widely Patent	Competent	Widely Patent	Competent
Gastrocnemius	Widely Patent	Competent	Widely Patent	Competent
Superficial Veins				
Saphenofemoral Junction	Not Identified		Patent	Incompetent
L Saphenous Vein Above	Patent	Isolated Incompetence	Patent	Competent
L Saphenous Vein Below	Patent	Incompetent	Patent	Competent
Vein of Giacomini	Patent	Competent	Patent	Competent
Saphenopopliteal Junction	Patent	Incompetent	Patent	Competent
S Saphenous Vein	Patent	Competent	Patent	Isolated Incompetence
Evidence of D.V.T.				
Above the knee	No		No	
Popliteal	No		No	
Below the knee	No		No	

Notes

BILATERAL LOWER LIMB VENOUS DUPLEX ASSESSMENT

Iliac veins not viewed, bilaterally. Flow in the right and left common femoral vein is phasic with respiration and a normal response on Valsalva manoeuvre, suggesting proximal vein patency, bilaterally. All visualised deep veins appear widely patent and competent with no evidence of previous DVT, bilaterally.

All measurements are proximal to the medial malleolus unless otherwise stated.

RIGHT

Sapheno-femoral junction (SFJ) was not identified due to previous treatment. Area of small tortuous branches identified in the groin ?Neovascularisation. Long Saphenous vein (LSV) reforms in the proximal thigh via a branch and appears competent until the vein of Giacomini communicates with the LSV in the

Assessed by Jack Wilson

Printed on 23/11/2021 at 10:43 am

Checked by

proximal/mid thigh (55cm prox to MM). LSV then appears incompetent and linear to the proximal calf. Incompetent branch identified in the proximal calf forming medial calf varicosities. LSV then appears competent to the ankle.

Transverse (AP) dimensions of LSV:

Proximal thigh- 0.27cm

Mid thigh - 0.50cm

Distal thigh - 0.38cm

Proximal calf- 0.41cm

Mid calf - 0.21cm

Distal calf - 0.19cm

Sapheno-popliteal junction (SPJ) appears tortuous and incompetent. Short Saphenous vein (SSV) is competent along length and is continuous with a competent vein of Giacomini (TS-0.53cm). Continuous, orthograde flow identified in the vein of Giacomini after calf augmentation ?Siphon.

Transverse (AP) dimensions of SSV:

Proximal calf- 0.15cm

Mid calf - 0.21cm

Distal calf - 0.25cm

LEFT

Sapheno-femoral junction (SFJ) is incompetent. Incompetent, tortuous anterior thigh vein identified arising from the junction. Anterior thigh vein appears dilated proximally (TS-1.81cm) and forms anterior/medial thigh varicosities. Long Saphenous vein (LSV) is competent along length. Varicosities communicate with the LSV in the distal thigh (48cm) however, LSV remains competent to the ankle.

Transverse (AP) dimensions of LSV:

Proximal thigh- 0.32cm

Mid thigh - 0.35cm

Distal thigh - 0.43cm

Proximal calf- 0.28cm

Mid calf - 0.22cm

Distal calf - 0.21cm

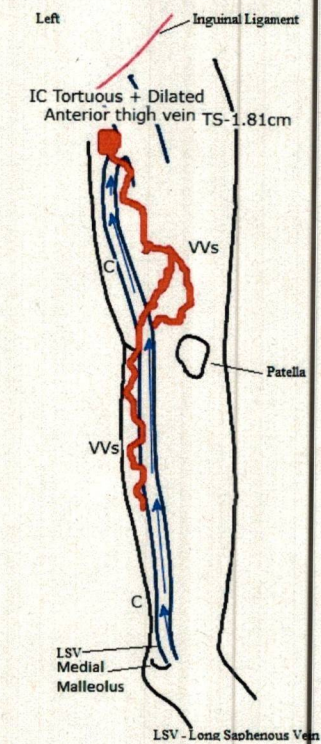
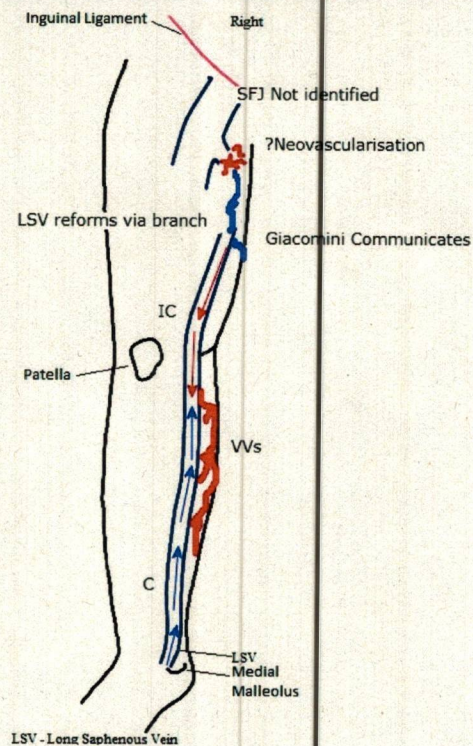
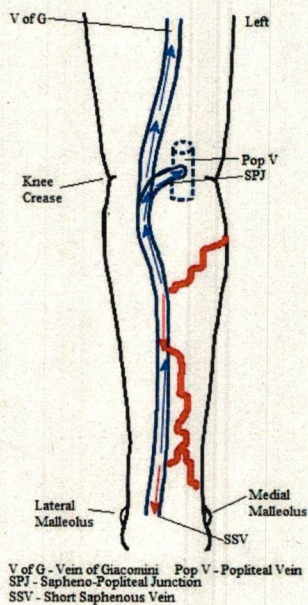
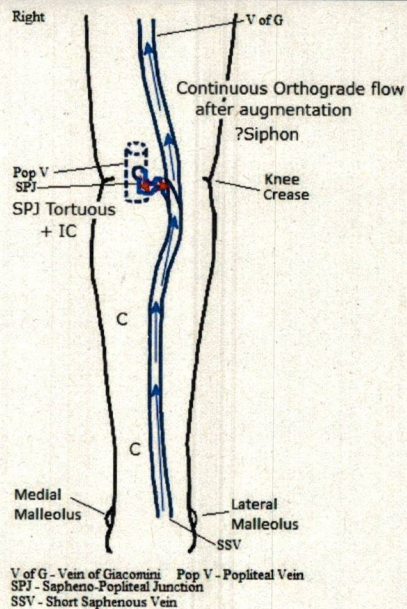
Sapheno-popliteal junction (SPJ) is competent. Proximal Short Saphenous vein (SSV) is competent and is continuous with a competent vein of Giacomini. Varicosities communicate with the SSV in the proximal/mid calf (21cm). Incompetent branch noted in the mid calf (18cm) forming medial/posterior calf varicosities. Varicosities communicate with the SSV again in the distal calf (13cm). SSV remains incompetent to the ankle.

Transverse (AP) dimensions of SSV:

Proximal calf- 0.29cm

Mid calf - 0.35cm

Distal calf - 0.27cm



Reason	Varicose vein
Outcome	Superficial thrombophlebitis, Incompetence - deep, Incompetence - superficial

Right			Left	
Deep Veins	Patency	Competency	Patency	Competency
Common Iliac Vein			Not Assessed	
External Iliac Vein			Not Assessed	
Internal Iliac Vein			Not Assessed	
Common Femoral Vein			Widely Patent	Competent
Profunda Vein			Widely Patent	Competent
Superficial Femoral Vein			Widely Patent	Incompetent
Popliteal Vein			Widely Patent	Competent
Posterior Tibial Vein			Widely Patent	Competent
Anterior Tibial Vein			Widely Patent	Competent
Peroneal Vein			Widely Patent	Competent
Soleal Vein			Widely Patent	Competent
Gastrocnemius			Widely Patent	Competent
Superficial Veins				
Saphenofemoral Junction			Patent	Competent
L Saphenous Vein Above			Patent	Isolated Incompetence
L Saphenous Vein Below			Patent	Incompetent
Vein of Giacomini			Patent	Competent
Saphenopopliteal Junction			Patent	Incompetent
S Saphenous Vein			Occluded	Fresh Thrombus
Evidence of D.V.T.				
Above the knee			No	
Popliteal			No	
Below the knee			No	

Notes

LEFT LOWER LIMB VENOUS DUPLEX ASSESSMENT

Iliac veins not viewed. Flow in the common femoral vein is phasic with respiration and a normal response on Valsalva manoeuvre, suggesting proximal vein patency. All visualised deep veins appear widely patent and competent with no evidence of previous DVT. With the exception of the the superficial femoral vein which is widely patent but incompetent along its length.

All measurements are proximal to the medial malleolus unless otherwise stated.

LEFT

Sapheno-femoral junction (SFJ) is competent. Long Saphenous vein (LSV) is competent in the thigh. Incompetent perforator to the superficial femoral vein identified in the distal thigh (41cm). LSV then appears

Assessed by Jack Wilson

Printed on 23/11/2021 at 10:51 am

Checked by

incompetent to the ankle with multiple small incompetent branches noted forming anterior and posterior calf varicosities.

Transverse (AP) dimensions of LSV:

Proximal thigh- 0.42cm

Mid thigh - 0.27cm

Distal thigh - 0.29cm

Proximal calf- 0.35cm

Mid calf - 0.30cm

Distal calf - 0.16cm

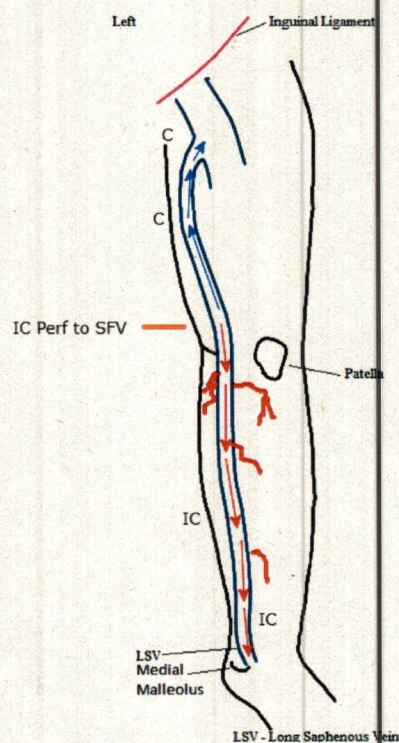
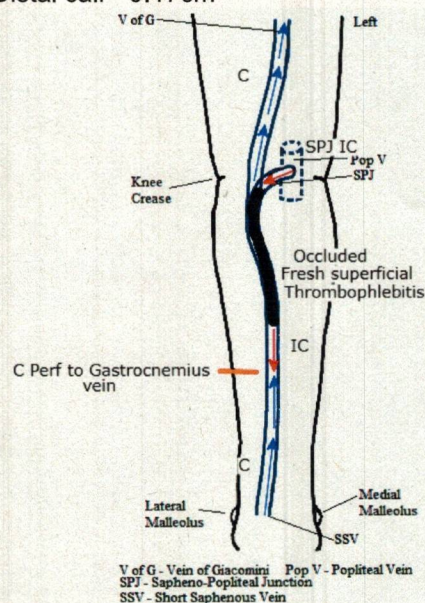
Sapheno-popliteal junction (SPJ) is incompetent. Competent vein of Giacomini identified. Proximal Short Saphenous vein (SSV) is occluded with fresh superficial thrombophlebitis. Mid SSV appears incompetent. Competent perforator to a Gastrocnemius vein identified in the mid calf (17cm). SSV then appears competent to the ankle.

Transverse (AP) dimensions of SSV:

Proximal calf- 0.13cm

Mid calf - 0.18cm

Distal calf - 0.17cm



Assessed by Jack Wilson

Printed on 23/11/2021 at 10:51 am

Checked by

Reason Varicose vein

Outcome Incompetence - deep, Chronic Superficial thrombophlebitis, Incompetence - superficial

Right		Left		
Deep Veins	Patency	Competency	Patency	Competency
Common Iliac Vein			Not Assessed	
External Iliac Vein			Not Assessed	
Internal Iliac Vein			Not Assessed	
Common Femoral Vein			Widely Patent	Competent
Profunda Vein			Widely Patent	Competent
Superficial Femoral Vein			Widely Patent	Isolated Incompetence
Popliteal Vein			Widely Patent	Competent
Posterior Tibial Vein			Widely Patent	Competent
Anterior Tibial Vein			Widely Patent	Competent
Peroneal Vein			Widely Patent	Competent
Soleal Vein			Widely Patent	Competent
Gastrocnemius			Widely Patent	Competent
Superficial Veins				
Saphenofemoral Junction			Patent	Competent
L Saphenous Vein Above			Patent	Competent
L Saphenous Vein Below			Patent	Competent
Vein of Giacomini			Not Identified	
Saphenopopiteal Junction			Patent	Competent
S Saphenous Vein			Patent	Competent
Evidence of D.V.T.				
Above the knee			No	
Popliteal			No	
Below the knee			No	

Notes

LEFT LOWER LIMB VENOUS DUPLEX ASSESSMENT

Iliac veins not viewed. Flow in the common femoral vein is phasic with respiration and a normal response on Valsalva manoeuvre, suggesting proximal vein patency. All visualised deep veins appear widely patent and competent with no evidence of previous DVT. With the exception of the superficial femoral vein which is widely patent but incompetent proximally and slightly incompetent in the mid vessel.

All measurements are proximal to the medial malleolus unless otherwise stated.

LEFT

Sapheno-femoral junction (SFJ) is competent. Long Saphenous vein (LSV) is competent and linear along length.

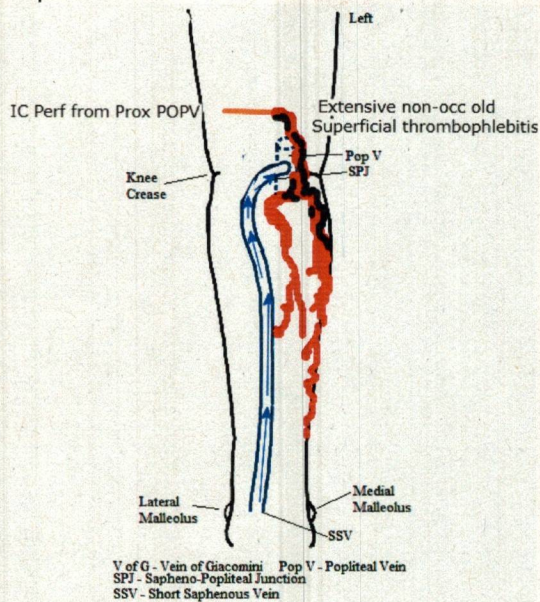
Assessed by Jack Wilson

Printed on 23/11/2021 at 10:53 am

Checked by

Sapheno-popliteal junction (SPJ) is competent. Short Saphenous vein (SSV) is competent along length.

Incompetent, tortuous perforator (LS-1.04cm) identified arising from the very proximal popliteal vein with extensive non-occlusive old superficial thrombophlebitis forming posterior thigh and posterior/medial calf varicosities. Varicosities communicate with the SSV in the mid calf (23cm) however SSV remains competent.



Reason	Varicose vein
Outcome	DVT negative, Poor images, patient habitus, Chronic Superficial thrombophlebitis, Incompetence - superficial

	Right		Left	
Deep Veins	Patency	Competency	Patency	Competency
Common Iliac Vein	Not Assessed		Not Assessed	
External Iliac Vein	Not Assessed		Not Assessed	
Internal Iliac Vein	Not Assessed		Not Assessed	
Common Femoral Vein	Patent	Competent	Patent	Competent
Profunda Vein	Patent	Competent	Patent	Competent
Superficial Femoral Vein	Patent	Competent	Patent	Competent
Popliteal Vein	Patent	Competent	Patent	Competent
Posterior Tibial Vein	Patent	Competent	Patent	Competent
Anterior Tibial Vein	Patent	Competent	Patent	Competent
Peroneal Vein	Patent	Competent	Patent	Competent
Soleal Vein	Not Identified		Not Identified	
Gastrocnemius	Patent		Patent	
Superficial Veins				
Saphenofemoral Junction	Patent	Incompetent	Patent	Incompetent
L Saphenous Vein Above	Areas of Thrombus	Old Thrombus	Patent	Competent
L Saphenous Vein Below	Patent	Competent	Patent	Competent
Vein of Giacomini	Not Identified		Not Identified	
Saphenopopliteal Junction	Not Identified		Not Identified	
S Saphenous Vein	Patent	Competent	Patent	Competent
Evidence of D.V.T.				
Above the knee	No		No	
Popliteal	No		No	
Below the knee	No		No	

Notes

BILATERAL LOWER LIMB VENOUS DUPLEX ASSESSMENT

*Challenging scan due to patient bodily habitus. Some poor images obtained.

Iliac veins not viewed. Flow in the common femoral vein is phasic with respiration and a normal response on Valsalva manoeuvre, suggesting proximal vein patency. All visualised deep veins appear patent and competent with no evidence of previous DVT.

All measurements are proximal to the medial malleolus unless otherwise stated.

RIGHT

Sapheno-femoral junction (SFJ) is incompetent. Long Saphenous vein (LSV) is incompetent in the thigh

Assessed by Jack Wilson

Printed on 23/11/2021 at 10:55 am

Checked by

with non-occlusive, old superficial thrombophlebitis identified from 2.24cm distal to the junction to the mid thigh. Branch identified in the mid thigh (54cm) forming medial thigh and calf varicosities, non-occlusive old superficial thrombophlebitis identified in the varicosities in the thigh. LSV appears competent and linear in the distal thigh and proximal calf. Varicosities communicate with the LSV in the proximal/mid calf (20cm), competent perforator to the posterior tibial veins identified at the same level. LSV then appears competent to the ankle.

Transverse (AP) dimensions of LSV:

Proximal thigh- 0.89cm

Mid thigh - 0.48cm

Distal thigh - 0.20cm

Proximal calf- 0.25cm

Mid calf - 0.18cm

Distal calf - 0.15cm

Sapheno-popliteal junction (SPJ) was not identified. Short Saphenous vein (SSV) is competent and is continuous with a competent posterior thigh vein.

LEFT

Sapheno-femoral junction (SFJ) is incompetent. Incompetent anterior thigh vein identified (TS-0.47cm) arising ~0.43cm distal to the junction. Anterior thigh vein appears linear for a short section in the very proximal thigh before becoming tortuous and branched forming anterior thigh varicosities. Non-occlusive, old superficial thrombophlebitis identified in the anterior thigh varicosities. Long Saphenous vein (LSV) is competent along length.

Transverse (AP) dimensions of LSV:

Proximal thigh- 0.32cm

Mid thigh - 0.16cm

Distal thigh - 0.14cm

Proximal calf- 0.25cm

Mid calf - 0.23cm

Distal calf - 0.13cm

Sapheno-popliteal junction (SPJ) was not identified. Short Saphenous vein (SSV) is competent and is continuous with a competent posterior thigh vein.

Reason Varicose vein

Outcome DVT negative, Chronic Superficial thrombophlebitis, Incompetence - superficial

	Right		Left	
	Patency	Competency	Patency	Competency
Deep Veins				
Common Iliac Vein	Not Assessed		Not Assessed	
External Iliac Vein	Not Assessed		Not Assessed	
Internal Iliac Vein	Not Assessed		Not Assessed	
Common Femoral Vein	Widely Patent	Competent	Widely Patent	Competent
Profunda Vein	Widely Patent	Competent	Widely Patent	Competent
Superficial Femoral Vein	Widely Patent	Competent	Widely Patent	Competent
Popliteal Vein	Widely Patent	Competent	Widely Patent	Competent
Posterior Tibial Vein	Widely Patent	Competent	Widely Patent	Competent
Anterior Tibial Vein	Widely Patent	Competent	Widely Patent	Competent
Peroneal Vein	Widely Patent	Competent	Widely Patent	Competent
Soleal Vein	Not Identified		Not Identified	
Gastrocnemius	Widely Patent		Widely Patent	
Superficial Veins				
Saphenofemoral Junction	Patent	Incompetent	Patent	Incompetent
L Saphenous Vein Above	Patent	Incompetent	Patent	Competent
L Saphenous Vein Below	Patent	Incompetent	Patent	Incompetent
Vein of Giacomini	Not Identified		Patent	Competent
Saphenopopliteal Junction	Patent	Incompetent	Patent	Competent
S Saphenous Vein	Areas of Thrombus	Old Thrombus	Areas of Thrombus	Old Thrombus
Evidence of D.V.T.				
Above the knee	No		No	
Popliteal	No		No	
Below the knee	No		No	

Notes

BILATERAL LOWER LIMB VENOUS DUPLEX ASSESSMENT

Iliac veins not viewed, bilaterally. Flow in the right and left common femoral vein is phasic with respiration and a normal response on Valsalva manoeuvre, suggesting proximal vein patency, bilaterally. All visualised deep veins appear widely patent and competent with no evidence of previous DVT, bilaterally.

All measurements are proximal to the medial malleolus unless otherwise stated.

RIGHT

Sapheno-femoral junction (SFJ) is incompetent and tortuous with multiple incompetent tortuous branches identified forming anterior thigh varicosities. Long Saphenous vein (LSV) is incompetent in the thigh with an incompetent branch identified in the distal thigh (48cm) forming medial thigh and anterior calf varicosities.

Assessed by Jack Wilson

Printed on 23/11/2021 at 11:07 am

Checked by

LSV remains incompetent to the ankle with another incompetent branch identified in the mid calf (22cm) forming medial calf varicosities.

Transverse (AP) dimensions of LSV:

Proximal thigh- 0.89cm

Mid thigh - 0.81cm

Distal thigh - 0.45cm

Proximal calf- 0.67cm

Mid calf - 0.56cm

Distal calf - 0.46cm

Sapheno-popliteal junction (SPJ) is incompetent. Short Saphenous vein (SSV) is incompetent and is continuous with a competent posterior thigh vein with non-occlusive old superficial thrombophlebitis in the proximal to mid vessel. Mid SSV appears tortuous and highly branched forming posterior and medial calf varicosities. Incompetent perforator to a Gastrocnemius vein identified in the mid calf (18cm). Distal SSV appears competent and linear.

Transverse (AP) dimensions of SSV:

Proximal calf- 0.70cm

Distal calf - 0.37cm

LEFT

Sapheno-femoral junction (SFJ) is incompetent. Incompetent anterior thigh vein identified (TS-0.92cm), arising ~0.69cm distal to the junction, forming anterior, medial and lateral thigh/knee varicosities.

Non-occlusive, old superficial thrombophlebitis identified in the proximal anterior thigh vein. LSV appears competent and linear in the thigh. Varicosities communicate with the LSV in the proximal calf (29cm).

Proximal to mid calf LSV is incompetent and linear. Incompetent branch identified in the mid/distal calf (15cm) forming medial calf varicosities. Distal LSV appears competent.

Transverse (AP) dimensions of LSV:

Proximal thigh- 0.39cm

Mid thigh - 0.37cm

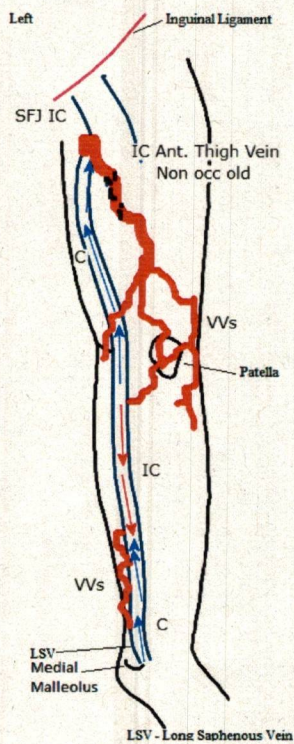
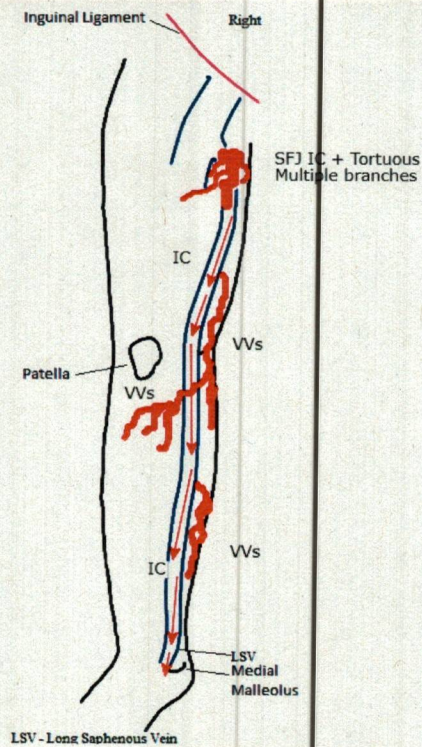
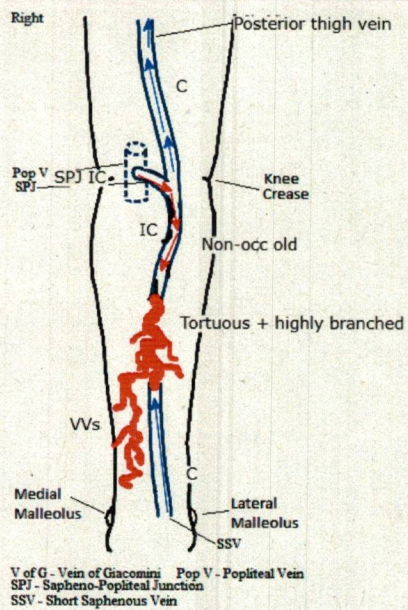
Distal thigh - 0.36cm

Proximal calf- 0.62cm

Mid calf - 0.61cm

Distal calf - 0.39cm

Sapheno-popliteal junction (SPJ) is competent. Short Saphenous vein (SSV) is incompetent and is continuous with a competent posterior thigh vein with non-occlusive old superficial thrombophlebitis in the proximal to mid vessel.



Reason Varicose vein
Outcome Incompetence - superficial

Right		Left	
Deep Veins	Patency	Patency	Competency
Common Iliac Vein		Not Assessed	
External Iliac Vein		Not Assessed	
Internal Iliac Vein		Not Assessed	
Common Femoral Vein		Widely Patent	Competent
Profunda Vein		Widely Patent	Competent
Superficial Femoral Vein		Widely Patent	Competent
Popliteal Vein		Widely Patent	Competent
Posterior Tibial Vein		Widely Patent	Competent
Anterior Tibial Vein		Widely Patent	Competent
Peroneal Vein		Widely Patent	Competent
Soleal Vein		Widely Patent	Competent
Gastrocnemius		Widely Patent	Competent
Superficial Veins			
Saphenofemoral Junction		Not Identified	
L Saphenous Vein Above		Not Identified	
L Saphenous Vein Below		Patent	Incompetent
Vein of Giacomini		Not Identified	
Saphenopopiteal Junction		Patent	Competent
S Saphenous Vein		Patent	Competent
Evidence of D.V.T.			
Above the knee		No	
Popliteal		No	
Below the knee		No	

Notes

LEFT LOWER LIMB VENOUS DUPLEX ASSESSMENT

Iliac veins not viewed. Flow in the common femoral vein is phasic with respiration and a normal response on Valsalva manoeuvre, suggesting proximal vein patency. All visualised deep veins appear widely patent and competent with no evidence of previous DVT.

All measurements are proximal to the medial malleolus unless otherwise stated.

LEFT

Sapheno-femoral junction (SFJ) was not identified due to previous treatment, multiple small ?incompetent tortuous branches identified in the groin ?Neovascularisation. Tortuous branches track along the medial thigh and reforms the LSV in the very distal thigh. Incompetent branch identified in the proximal calf (27cm)

Assessed by Jack Wilson

Printed on 23/11/2021 at 11:04 am

Checked by

forming medial calf varicosities. Mid calf LSV remains incompetent. Further incompetent branch identified in the distal calf (15cm) forming medial calf varicosities. LSV appears competent distally with an incompetent perforator to the posterior tibial veins identified in the distal calf (11cm).

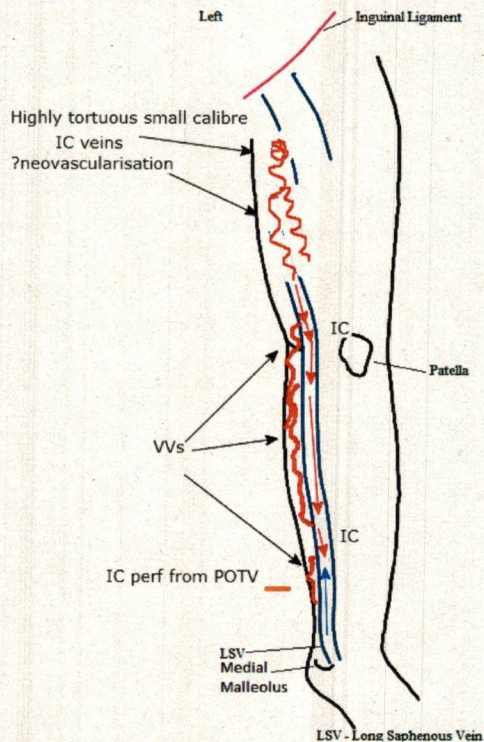
Transverse (AP) dimensions of LSV:

Proximal calf- 0.28cm

Mid calf - 0.24cm

Distal calf - 0.28cm

Sapheno-popliteal junction (SPJ) is widely patent and competent. Short Saphenous vein (SSV) is widely patent and competent.



Reason Varicose vein
Outcome Incompetence - superficial

	Right		Left	
	Patency	Competency	Patency	Competency
Deep Veins				
Common Iliac Vein	Not Assessed		Not Assessed	
External Iliac Vein	Not Assessed		Not Assessed	
Internal Iliac Vein	Not Assessed		Not Assessed	
Common Femoral Vein	Widely Patent	Competent	Widely Patent	Competent
Profunda Vein	Widely Patent	Competent	Widely Patent	Competent
Superficial Femoral Vein	Widely Patent	Competent	Widely Patent	Competent
Popliteal Vein	Widely Patent	Competent	Widely Patent	Competent
Posterior Tibial Vein	Widely Patent	Competent	Widely Patent	Competent
Anterior Tibial Vein	Widely Patent	Competent	Widely Patent	Competent
Peroneal Vein	Widely Patent	Competent	Widely Patent	Competent
Soleal Vein	Not Identified		Not Identified	
Gastrocnemius	Widely Patent	Competent	Widely Patent	Competent
Superficial Veins				
Saphenofemoral Junction	Patent ?Reformed	Incompetent	Patent	Competent
L Saphenous Vein Above	Patent	Isolated Incompetence	Patent	Competent
L Saphenous Vein Below	Patent	Competent	Patent	Competent
Vein of Giacomini	Not Identified			
Saphenopopliteal Junction			Patent	Competent
S Saphenous Vein	Patent	Competent	Patent	Competent
Evidence of D.V.T.				
Above the knee	No		No	
Popliteal	No		No	
Below the knee	No		No	

Notes

BILATERAL LOWER LIMB VENOUS DUPLEX ASSESSMENT

Iliac veins not viewed. Flow in the common femoral vein is phasic with respiration and a normal response on Valsalva manoeuvre, suggesting proximal vein patency. All visualised deep veins appear widely patent and competent with no evidence of previous DVT.

All measurements are proximal to the medial malleolus unless otherwise stated.

RIGHT

Sapheno-femoral junction (SFJ) and very proximal LSV is patent, tortuous and incompetent ?Reformed after previous treatment. Incompetent, tortuous anterior thigh vein identified forming medial/lateral thigh and posterior calf varicosities. Long Saphenous vein (LSV) is patent, linear and incompetent in the proximal

Assessed by Jack Wilson

Printed on 23/11/2021 at 10:58 am

Checked by

thigh. Incompetent branch identified in the mid thigh (59cm) forming medial thigh and calf varicosities. Competent perforator to the SFV noted in the mid thigh (58cm). LSV then appears competent and linear to the ankle.

Transverse (AP) dimensions of LSV:

Proximal thigh- 0.30cm

Mid thigh - 0.38cm

Distal thigh - 0.38cm

Proximal calf- 0.33cm

Mid calf - 0.16cm

Distal calf - 0.24cm

Sapheno-popliteal junction (SPJ) was not identified. Short Saphenous vein (SSV) is competent and is continuous with a competent posterior thigh vein

LEFT

Sapheno-femoral junction (SFJ) is widely patent and competent. Long Saphenous vein (LSV) is widely patent and competent along length.

Sapheno-popliteal junction (SPJ) is widely patent and competent. Short Saphenous vein (SSV) is widely patent and competent along length.

