



CL1.6

6. Lower limb arterial duplex/graft surveillance/angioplasty(stent) surveillance –

a) Thigh arteries

Probe types – 12-3 MHz linear array^{2,4,6}.

Measurements – velocities in centimetres per second, diameter (anterior-posterior AP, medial-lateral ML) in centimetres, length of disease in centimetres^{1,2}.

Patient lies supine^{1,7}. Due to the intimate nature of the scan, a chaperone should be offered²⁵.

The common femoral artery is visualised in the groin and followed proximal to the inguinal ligament^{1,2}.

The common femoral artery is then traced distally to the bifurcation and the profunda femoris and superficial femoral arteries are identified. The superficial femoral is traced along its length and through the adductor canal, visualisation is improved by flexing the leg at the knee to a 45 degree angle and turning the knee outwards^{1,2,7}.

Peak velocity readings and waveform shape and quality are recorded in the common femoral, at the profunda origin and at the superficial femoral origin, and at the proximal, mid and distal SFA^{2,8}.

If an area of stenosis is identified a peak velocity reading is taken immediately proximal, within and immediately distal to the diseased section. The colourflow and Doppler assessments are used to decide whether the disease is a stenosis or complete occlusion. The disease length and the distance from the medial malleolus is recorded. Any collateral vessels are noted. It should be stated whether the disease appears acute or chronic. It should be made clear in the report whether the distal superficial femoral reforms a disease free segment above the knee^{7,8}.

If there is a significant stenosis present, measure the maximum PSV through the stenosis (V2) and the PSV just proximal to the stenosis as a "normal" reference velocity (V1), to enable calculation of the velocity ratio V2/V1. Note that at the SFA and PFA origins it may not be possible to obtain a V1 measurement; the absolute PSV will then be used to grade the % stenosis. If within the SFA, mark the position and length of any significant stenosis with a single-use surgical marker pen and measure the distance to the medial malleolus^{3,5}.

Also remember to scan contralateral CFA when performing lower limb arterial assessments. In addition to our standard protocol if a patient has an iliac occlusion/severe disease (CIA, EIA or both) please scan contralateral iliac system. This may save the patient coming to VSU twice and speeds up the whole patient management process⁹.



For assessment of the popliteal artery, the patient sits with legs dependent or lies flat with the leg slightly flexed at the knee and externally rotated^{1,2}. Alternatively, having the patient lie on their side can allow a good view of the popliteal artery.

The popliteal artery is identified behind the knee and traced proximally ensuring that the full length of artery through the adductor canal is visualised and assessed^{2,5}.

The first arterial branch of the trifurcation is the anterior tibial (may not be viewed). The tibio-peroneal trunk is traced into the upper calf until it bifurcates into the posterior tibial and peroneal arteries. Waveforms are recorded and the velocities are measured in the popliteal and at each of the run-off artery origins and in any area where a stenosis is identified^{2,11,12}. The number of run-off vessels viewed should be documented (0-3).

Velocity ratios:

Comparing Peak Systolic Velocity (PSV) in reference segment proximal to lesion (V1) with maximum stenotic jet PSV (V2) gives a V2:V1 ratio (namely $V2/V1$) which can be used as follows^{1,2,10,27,28,29}:

Classification (diameter reduction)	Velocity Ratio	Disease level
0-49%	<2.0	Mild
50-74%	≥2.0	Moderate
75-99%	≥4.0	Severe

Absolute velocities:

For use when it is not possible to obtain a suitable reference V1:²⁴

artery	mean PSV (cm/s)	SD (cm/s)
Aorta	76	17
CIA	111	17
EIA	112	49
CFA	90	41
SFA prox	89	23
SFA mid	83	25
SFA distal	74	21
Popliteal	59	12

- ! The above table shows peak systolic velocities for normal legs.
- ! For a normal distribution, 99% of observations will fall within the range of the mean +/- 2 standard deviations.

For example, if the iliac arteries are largely obscured by bowel gas, but an isolated section of flow is seen in the EIA with a velocity of 300cm/s we can suggest that significant disease is likely. Using the mean velocity in the table above as V1, we can use the same ratio criteria to stratify the severity of disease, e.g. ≥ 4 would indicate severe disease.

Ankle brachial pressure indices are performed. (See Peripheral waveform assessment)



b) Calf arteries – Calf vessels should be scanned along their length²⁶.

Probe types – 12-3 MHz linear array/ if needed – 5-1 MHz curved array^{2,4}

Measurements – velocities in centimetres per second, length of disease in centimetres^{1,5}.

Patient lies supine or sits on the edge of the bed with their legs dependent (aids visualisation with severe disease, and allows venous filling which can be used to map the course of the arteries)².

The posterior tibial artery is identified posterior to the medial malleolus and is traced proximally. The peroneal artery is visualised deep to the posterior tibial artery (both arteries can be assessed throughout the length of the calf). If unable to visualise the peroneal artery with 12-3MHz – then you must try the 2-5 curved array, or attempt to view from an anterior approach^{2,12,13}.

The anterior tibial artery is identified on the antero-lateral aspect of the ankle (do not apply too much pressure as the artery may be occluded by the transducer) and should be traced to the upper calf^{12,13}.

Velocities and waveforms are recorded from all the calf arteries at the ankle and proximal calf and also at any site of stenosis.

In the presence of proximal disease, calf velocities can be unreliable and disease should be graded mild, moderate, severe or occluded^{1,8}.

c) Prosthetic grafts (usually above knee femoro-popliteal, aorto-bifemoral grafts (ABG), fem-fem crossover).

Probe types – 5-1 MHz curved array, 12- 3 MHz linear array^{2,14}.

Measurements – velocities in centimetres per second, diameter (anterior-posterior AP, medial-lateral ML) in centimetres, length of disease in centimetres^{1,2}.

Similar scanning protocols as above, except only the segments just proximal, mid and distal to the grafts are assessed. Particular attention is paid to the proximal and distal anastomosis where waveform shapes and velocities are recorded. ABPI are taken to assess any disease progression in non-treated segments (patient has usually had a full assessment prior to surgery)^{16,17}.

With fem-fem crossover grafts it is important to record the direction of flow through the graft^{1,2,18}.

With ABG and fem-fem crossover grafts, the common femoral waveforms are recorded^{1,2,18}.



Waveforms, peak velocities, ABPIs and any areas of re-stenosis/new disease are recorded¹⁷.

d) Vein grafts (usually below knee)

Probe types – 12-3MHz linear array².

Measurements – velocities in centimetres per second, diameter (anterior-posterior AP, medial-lateral ML) in centimetres, length of disease in centimetres^{1,2}.

Similar scanning protocols to above, except only the segments just proximal, mid and distal to the grafts are assessed. Care is taken to scan the length of the graft and velocities and waveforms are recorded at areas of stenosis (usually valve cusps). Waveforms, peak velocities, ABPI and any areas of re-stenosis/new disease are recorded. Avoid taking ABPI on fem-distal grafts as inflating the cuff leads to danger of occluding the graft^{2,19,20}.

If peak velocity is less than 45cm/s - graft is probably at risk of failure and this must be noted in the report².

e) Stent/angioplasty assessment

Probe types – 12-3 MHz linear array^{4,6}.

Measurements – velocities in centimetres per second, diameter (anterior-posterior AP, medial-lateral ML) in centimetres, length of disease in centimetres^{1,2}.

Similar scanning protocol to above. Care is taken particularly at the just proximal to, mid and just distal to the stent/angioplasty site. Waveforms, peak velocities, ABPIs and any areas of re-stenosis/new disease are recorded^{2,20}.

f) Pseudo-aneurysm diagnosis and compression.

Probe types – 12-3 MHz linear array^{4,6}.

Measure site of the feeder jet from the femoral bifurcation – if jet lies at or within 1cm of the bifurcation the pseudo-aneurysm will be usually be suitable for compression. The size of the sac must be measured in LS and TS, this is particularly important if the management results in thrombin injection as the radiologist will judge how much to use based on the size of the sac.

Suitability for compression depends on the position and width of the jet: the wider the jet the less likely it is going to successfully compressed. If the pseudo-aneurysm lies directly above the jet it will make it difficult to compress, the deeper the aneurysm i.e. if it originates off the posterior wall again it will be difficult to compress^{1,2,21,22}.

The dimensions of the pseudo-aneurysm must be recorded – length, AP and ML²¹.



If no colourflow is seen filling a pseudo-aneurysm but there is evidence of fresh haematoma the report should state “no evidence of patent pseudo-aneurysm but areas of fresh haematoma noted, cannot exclude a thrombosed pseudo-aneurysm or slow bleed”.

If the pseudo-aneurysm is deemed to be suitable for compression then it is necessary to arrange for the patient to come down on their bed. The patient may require analgesics as the compression can cause significant discomfort – the SHO/HO needs to supply and if necessary administer the pain relief.

Using the L7-5 probe, the vascular scientist needs to apply pressure over the jet of the pseudo-aneurysm and should attempt to occlude it. The first compression should last 10 minutes and the circulation should be checked with a hand held Doppler at the ankle to ensure patency. After 10 minutes the pseudo-aneurysm needs to be checked to see if it is thrombosed or partially thrombosed. If still patent further compressions of 10 minutes need to be performed, up to a maximum of three sessions. If after the third session the pseudo-aneurysm is still patent then the patient should be referred to interventional radiologist for thrombin injection.

If the pseudo-aneurysm has thrombosed then we need to rescan the patient the next day to ensure it remains occluded^{2,22,23}.

REFERENCES:

1. Thrush and Hartshorne. (2010). Vascular Ultrasound, How, Why and When. 3rd Edition.
2. Institute of Physics and Engineering in Medicine in association with The Society For Vascular Technology of GB & Ireland. (2001). Vascular Laboratory Practice Part VI, IPEM 1st Edition.
3. Zwiebel WJ, Pellerito JS. (2005) Introduction to vascular ultrasonography 5th edition. Elsevier Saunders, Philadelphia.
4. Philips. (2005). iu22 Ultrasound System. Getting Started handbook.
5. Hammets D. (2004). Vascular Technology. The Burwin Institute. USA.
6. Leiner T, Kessels A, Nelemans P, Vasbinder B, Haan M, Kitslaar P, Yiu K, Tordoir J, Engelshoven J. (2005) Peripheral Arterial Disease Comparison of Colour Duplex US and Contrast-enhanced MR Angiography for Diagnosis. Radiology; 235:699-708.
7. Eiberg J, Gronvall Rasmussen J, Hansen M, Schroder T. (2010). Duplex Ultrasound Scanning of Peripheral Arterial Disease of the Lower Limb. European Journal of Vascular Surgery. 40:507-512.
8. Geehard-Herman M, Gardin J, Jaff M, Mohler E, Roman M, Naqvi T. (2001). Guidelines for Non-invasive Vascular Laboratory Testing: A Report from the American Society of Echocardiography and the Society for Vascular Medicine and Biology. Vascular Medicine; 11:183-200.
9. Marks, N, Ascher E, Hingorani A. (2007). Treatment of Failing Lower Extremity Arterial Bypasses Under Ultrasound Guidance. Perspectives in Vascular Surgery and Endovascular Therapy;19;34-39.



10. Gerhard-Herman M. et al. (2006). Guidelines for noninvasive vascular laboratory testing: a report from the American Society of Echocardiography and the Society for Vascular Medicine and Biology.
11. Polak J. (1992). Peripheral Vascular Sonography. A Practical Guide.
12. William and Wilkins, Baltimore. Rossi F et al. (2006). Colour-flow Duplex Hemodynamic Assessment of Runoff in Ischaemic Lower Limb Revascularisation. The International Society for Vascular Surgery. Vascular; 14:149-155.
13. Szpinda M. (2005). Compensating Crural Anastomoses in Chronic Critical Limb Ischaemia. Via Medica; 64(1):17-21.
14. Schlager O. et al. (2007). Duplex Sonography Versus Angiography for Assessment of Femoropopliteal Arterial Disease in a 'Real-World' Setting. [J Endovasc Ther](#). Aug;14(4):452-9.
15. Polak J. (2016). Institute for Advanced Medical Education. Evaluation of Lower Extremity Bypass Grafts. Published online at <https://iame.com/online-courses/ultrasound-vascular/evaluation-of-lower-extremity-bypass-grafts>
16. Moore J, Salles-Cunah S, Scissons R, Beebe H, Toledo. (2001). Diameter Comparison of Saphenous Vein Bypasses for Popliteal Aneurysm Versus Peripheral Arterial Occlusive Disease in Matched Subjects. Vascular Surgery;35(6):449-455.
17. Baril D, Marone L. (2012). Duplex Evaluation Following Femoropopliteal Angioplasty and Stenting: Criteria and Utility of Surveillance. [Vasc Endovascular Surg](#). Jul;46(5):353-7.
18. Scissons R, (2002). Lower Extremity Duplex Graft Surveillance. Journal of Vascular Technology 200126(1)55-60.
19. Cassar N, Dunjic B, Cassar K. (2010). Implementation of a Graft Surveillance Programme for Infrainuginal Vascular Bypass Surgery. Malta Medical Journal; 22(3): 24-26.
20. Bandyk D, Chauvapun J. (2007). Duplex Ultrasound Surveillance Can Be Worthwhile After Arterial Intervention. Perspectives in Vascular Surgery and Endovascular Therapy; 19(4):354-359.
21. Luedde M, Krumdorf U, Zehelein J, Ivandic B, Dengler T, Katus H, Tiefenbacher C. (2007). Treatment of Iatrogenic Femoral Pseudoaneurysm by Ultrasound-Guided Compression Therapy and Thrombin Injection. Angiology;58:435-439.
22. Yetkin U, Gurbuz A. (2003). Post-Traumatic Pseudoaneurysm of the Brachial Artery and Its Surgical Treatment. Texas Heart Institute Journal;30:293-297.
23. Latic A, Delibegovic, Pudic I, Samardzic, Radmilovic. (2011). Non-Invasive Ultrasound Guided Compression Repair of Post Puncture Femoral Pseudoaneurysm. Med Arth: 65(2):113-114.
24. Wright I, Buckenham T. (2003). Lower Limb Arterial Duplex Ultrasound Exam Protocol. Christchurch Public Hospital.
25. Society for Vascular Technology. (2012). Professional Standards Committee Chaperone Guidelines www.svtgbi.org.uk
26. Society for Vascular Technology. (2015). Vascular Technology Professional Performance Guidelines. Lower Limb Arterial Duplex Ultrasound Examination. www.svtgbi.org.uk/media/resources/LowerLimbArterialPSCFinalJuly2015edit.pdf

27. Cossmann D.V, Ellison, J.E, Wagner, W.H et al. (1989). Comparison of contrast arteriography to arterial mapping with colour-flow duplex imaging in the lower extremities. *Journal of Vascular Surgery* 20. 978-986.
28. Sensier Y, Hartshorne, T, Thrush, A et al. (1996). A prospective comparison of lower limb color-coded duplex scanning with arteriography. *European Journal of Vascular and Endovascular Surgery* 11: 170-175.
29. Hennerici M, Neuerburg-Heusler D. 1998. *Vascular diagnosis with ultrasound*. Thieme, Stuttgart, pp 179-180.

g) Popliteal artery entrapment syndrome (PAES)

PAES is a rare developmental defect in which the gastrocnemius muscle, popliteus muscle or tendons neighbouring the popliteal fossa are abnormally formed and can cause extrinsic compression of the popliteal artery when the lower limb is maintained in certain positions^{1,2}. Currently five anatomical variants of popliteal entrapment have been identified and are summarised in the table below³. However, over-development of the gastrocnemius muscle can produce similar entrapment of the popliteal artery, this sixth form is known as functional popliteal entrapment syndrome and is often observed in professional athletes or in those whose profession require physical activity^{3,4,5}.

Variant of PAES	Anatomical Abnormality
Type 1	Popliteal artery follows an abnormal course
Type 2	Medial head of gastrocnemius muscle lies in a lateral location impinging on popliteal artery that runs a normal course
Type 3	An accessory slip of gastrocnemius muscle impinges the popliteal artery that runs a normal course
Type 4	Popliteus muscle or fibrous band impinges the popliteal artery that runs a normal course
Type 5	Types 1- 4 and the popliteal vein is also entrapped

Anatomical variants of PAES³.

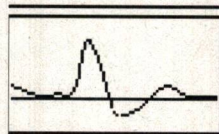
Patients with PAES commonly present with intermittent calf claudication and parasthesia symptoms which exacerbate upon exercise. Since the patient demographic of those suffering from PAES is typically young athletic individuals, the symptoms are often likely to be attributable to musculoskeletal disorders rather than vascular disease⁶. However, differential diagnoses can include a number of lower limb disorders such as peripheral vascular disease, cystic adventitial disease, arterio-venous fistulae, compartment syndrome, muscle rupture, neuropathy and venous thrombosis^{4,6}. If left undiagnosed, prolonged exposure to PAES can result in micro-trauma to popliteal artery, and can ultimately lead to localised stenoses, aneurysms or complete occlusion³.

Reason
Outcome

Routine
Calcified, Poor images, Stenosis Moderate

Right

172 1.00



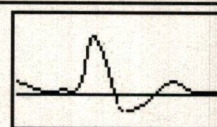
Good

Brachial

Common Femoral

Good

Left

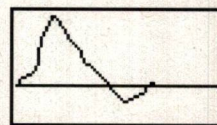


High Thigh

Low Thigh

Popliteal

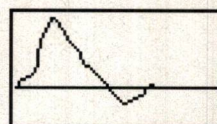
Good



High Calf

Peroneal

Good



Anterior Tibial

Good

Posterior Tibial

Good

Dorsalis Pedis

Toe Pressure

Foot Flex

164 0.95

Post Exercise

Foot Flex

164 0.95

Notes

BILATERAL LOWER LIMB ARTERIAL DUPLEX SCAN

AORTA: Normal uniform calibre TS-1.8cm, LS-1.7cm. Mild disease with good triphasic waveforms, PSV 83cm/s.

RIGHT

CIA: Obscured by bowel gas.

EIA: Mild disease with good biphasic waveforms, PSV 200-294cm/s.

Assessed by Jack Wilson

Printed on 25/11/2021 at 1:10 pm

Checked by

CFA: Mild calcified disease with good triphasic waveforms, PSV 246cm/s.

PFA: Origin was poorly visualised due to calcification where seen, turbulent, high velocity flow noted PSV 472cm/s ?Moderate stenosis. Turbulent biphasic waveforms identified distal to obscured region, PSV 88cm/s.

SFA: Mild calcified disease along length with good bi/triphasic waveforms, PSV 111-244cm/s.

POPA: Mild disease with good biphasic waveforms, PSV 246cm/s. TPT is patent with 3 vessel run off identified.

ATA: Mild disease along length with good triphasic waveforms at ankle, PSV 137cm/s.

PTA: Mild disease along length with good biphasic waveforms at ankle, PSV 128cm/s.

PerA: Mild disease along length with good biphasic waveforms at ankle, PSV 53cm/s.

LEFT

CIA: Obscured by bowel gas.

EIA: Mild disease with good biphasic waveforms, PSV 194-216cm/s.

CFA: Mild calcified disease with good triphasic waveforms, PSV 181cm/s.

PFA: Origin was poorly visualised due to calcification where seen, turbulent, high velocity flow noted PSV 367cm/s ?Moderate stenosis. Turbulent biphasic waveforms identified distal to obscured region, PSV 75cm/s.

SFA: Mild/moderate calcified disease along length with good biphasic waveforms, PSV 157-188cm/s.

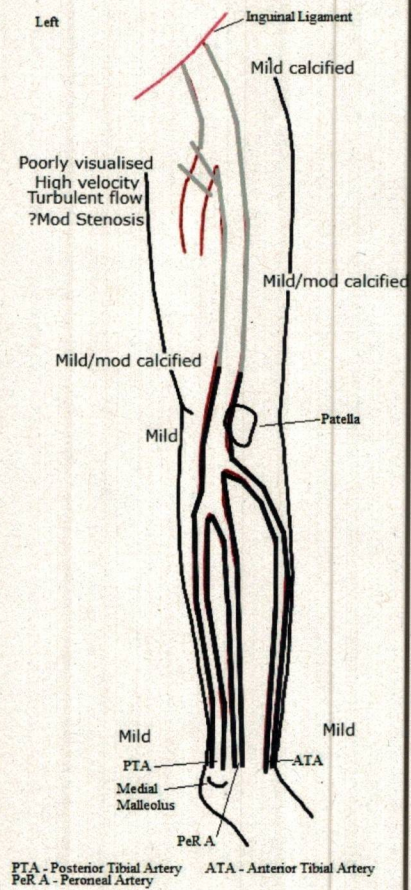
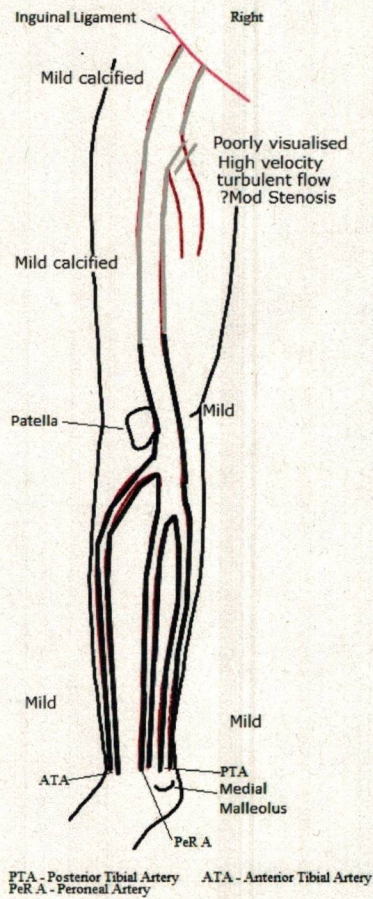
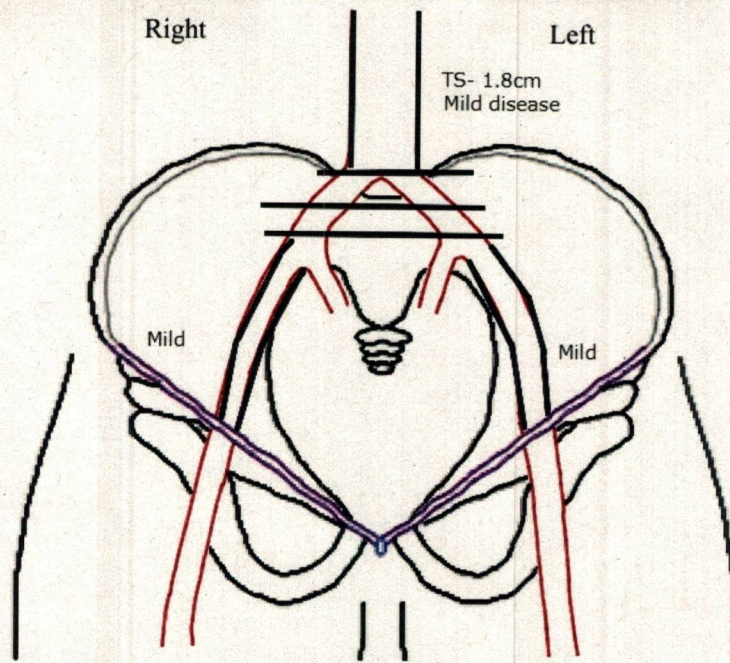
POPA: Mild/moderate calcified disease in the proximal vessel and mild disease in the distal vessel with good biphasic waveforms along length, PSV 97-131cm/s. TPT is patent with 3 vessel run off identified.

ATA: Mild disease along length with good biphasic waveforms at ankle, PSV 114cm/s.

PTA: Mild disease along length with good biphasic waveforms at ankle, PSV 98cm/s.

PerA: Mild disease along length with good biphasic waveforms at ankle, PSV 57cm/s.

ABPI: The right and left resting ABPIs are within normal limits and remain so after a 1 minute foot flex exercise test.

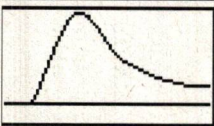
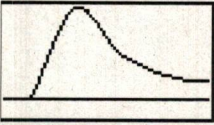

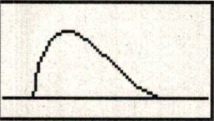
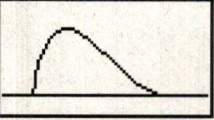


Assessed by Jack Wilson

Printed on 25/11/2021 at 1:10 pm

Checked by

Reason	Routine
Outcome	Bowel gas, Poor images, Stenosis Moderate, Significant disease indicated

Right			Left
		Brachial	
	Slightly Reduced	Common Femoral	
		High Thigh	
		Low Thigh	
	Slightly Reduced	Popliteal	
		High Calf	
	Reduced	Peroneal	
	Slightly Reduced	Anterior Tibial	
	Slightly Reduced	Posterior Tibial	
		Dorsalis Pedis	
		Toe Pressure	
		Post Exercise	

Notes

RIGHT LOWER LIMB ARTERIAL DUPLEX SCAN

*Small calibre arteries identified throughout.

AORTA: Normal, uniform calibre, TS-1.33cm, LS-1.28cm. Mild disease with slightly reduced mono/triphasic waveforms, PSV 63cm/s.

RIGHT

CIA: Poorly visualised due to bowel gas and small calibre vessels. Stent not identified. Where seen, high

Assessed by Jack Wilson

Printed on 16/11/2021 at 10:36 am

Checked by

velocity turbulent flow identified indicative of a moderate/severe stenosis, PSV 297cm/s.

EIA: Moderate stenosis identified in the proximal vessel with velocities increasing from 115-247cm/s.

Mild/moderate calcified disease in the mid to distal vessel with good monophasic waveforms, PSV 111cm/s.

CFA: Mild/moderate disease with slightly reduced monophasic waveforms, PSV 148cm/s.

PFA: Mild/moderate disease with slightly reduced monophasic waveforms, PSV 135cm/s.

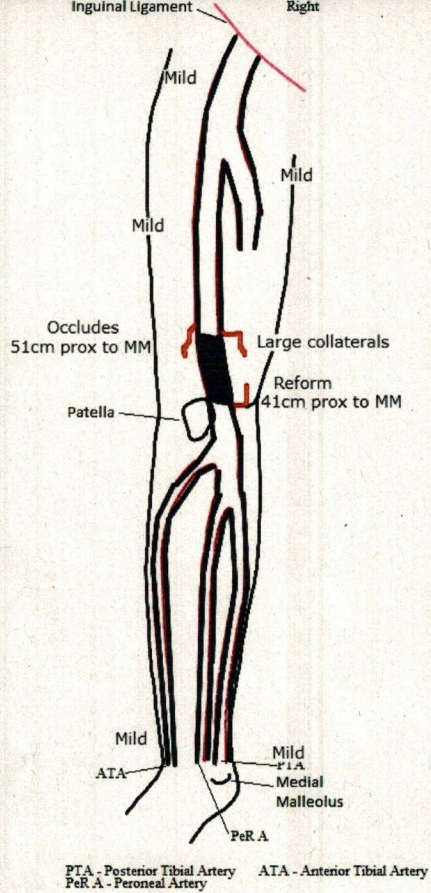
SFA: Mild disease with slightly reduced monophasic waveforms, PSV 44-91cm/s.

POPA: Mild disease with slightly reduced monophasic waveforms, PSV 31-52cm/s. TPT appears patent with 3 vessel run off identified.

ATA: Mild disease with slightly reduced monophasic waveforms at ankle, PSV 24cm/s.

PTA: Mild disease with slightly reduced monophasic waveforms at ankle, PSV 17cm/s.

PerA: Mild disease along length, very small calibre at ankle with reduced monophasic waveforms, PSV 7cm/s.



Assessed by Jack Wilson

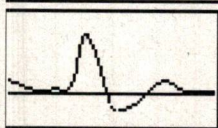
Printed on 16/11/2021 at 10:35 am

Checked by

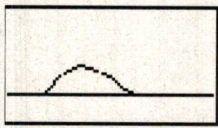
Reason Routine
Outcome disease mild, Occlusion

Right

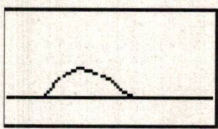
130 1.00




Good




Reduced



Reduced



Reduced



Reduced

88

0.68

Brachial

Common Femoral

High Thigh

Low Thigh

Popliteal

High Calf

Peroneal

Anterior Tibial

Posterior Tibial

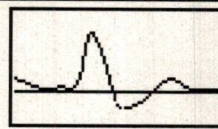
Dorsalis Pedis

Toe Pressure

Post Exercise

Left

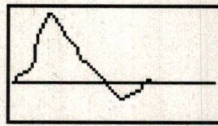
Good



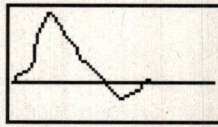
Good

142

1.09



Good



Notes

RIGHT LOWER LIMB ARTERIAL DUPLEX SCAN

AORTA: Normal, uniform calibre TS-1.5cm, LS- 1.6cm. Mild disease with good triphasic waveforms, PSV 91cm/s.

RIGHT

CIA: Obscured by bowel gas.

EIA: Proximal vessel obscured by bowel gas. Mild disease in the mid to distal vessel with good triphasic

Assessed by Jack Wilson

Printed on 16/11/2021 at 10:37 am

Checked by

waveforms, PSV 135cm/s.

CFA: Mild disease with good triphasic waveforms, PSV 164cm/s.

PFA: Mild disease with good triphasic waveforms, PSV 90cm/s.

SFA: Mild disease in the proximal to mid/distal vessel with good triphasic waveforms, PSV 58-90cm/s.

Vessel occludes in the distal thigh (51cm prox to MM), multiple large collateral vessels noted. Vessel appears occluded through adductor canal.

POPA: Proximal vessel appears occluded. Flow reforms in the mid vessel (41cm prox to MM) via a collateral with good monophasic waveforms, PSV 78cm/s. Mild disease in the distal vessel with reduced monophasic waveforms, PSV 37cm/s. TPT appears patent with 3 vessel run off identified.

ATA: Mild disease with reduced monophasic waveforms at the ankle, PSV 20cm/s.

PTA: Mild disease with reduced monophasic waveforms at the ankle, PSV 28cm/s.

PerA: Mild disease with reduced monophasic waveforms at the ankle, PSV 11cm/s.

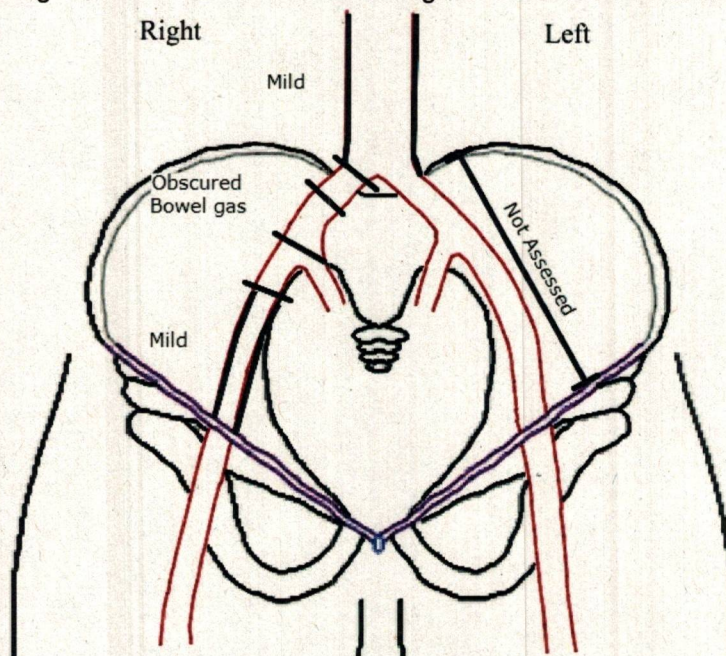
LEFT

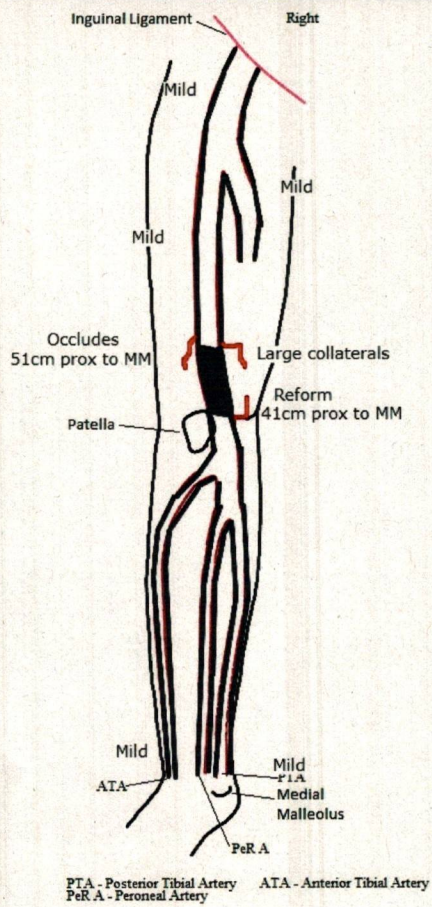
CFA: Good triphasic waveforms, PSV 171cm/s.

ATA: Good biphasic waveforms at ankle, PSV 65cm/s.

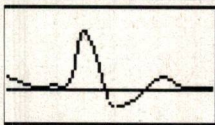
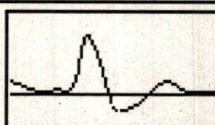

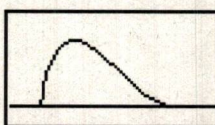

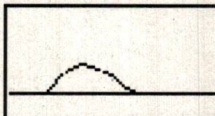




PTA: Good biphasic waveforms at ankle, PSV 63cm/s.

ABPI: The right resting ABPI is reduced. The left resting ABPI is within normal limits.





Reason	Claudication, Graft synthetic fem-pop
Outcome	Occlusion, Calcified, Stenosis Moderate, Significant disease indicated

Right			Left	
	166 1.00	Brachial		
	Good	Common Femoral	Good	
		High Thigh		
		Low Thigh		
	Reduced	Popliteal	Slightly Reduced	
		High Calf		
	Reduced	Peroneal	Reduced	
	Absent	Anterior Tibial	Absent	
	Absent	Posterior Tibial	Absent	
		Dorsalis Pedis		
		Toe Pressure		
		Post Exercise		

Notes

BILATERAL LOWER LIMB ARTERIAL DUPLEX SCAN

AORTA: Normal, uniform calibre TS-2.1cm, LS-2.0cm. Mild/moderate calcified disease with good biphasic waveforms, PSV 72cm/s.

RIGHT

CIA: Appears ectatic measuring TS- 1.54cm, LS-1.568cm. Mild/moderate calcified disease with good triphasic waveforms, PSV 107cm/s.

EIA: Mild/moderate calcified disease with good triphasic waveforms, PSV 152-163cm/s.

Assessed by Jack Wilson

Printed on 16/11/2021 at 10:42 am

Checked by

CFA: Mild/moderate calcified disease with good triphasic waveforms, PSV 144cm/s.
PFA: Moderate calcified disease with good triphasic waveforms, PSV 90cm/s.

RT FEM-DISTAL SFA BYPASS GRAFT

PROX ANAST: Occluded.

GRAFT BODY: Occluded and collapsed along length.

Distal ANAST: Occluded.

SFA: Proximal to mid/distal vessel appears chronically occluded. Flow reforms in the distal vessel (just distal to graft anastomosis, 46cm prox to MM) via a collateral with slightly reduced monophasic waveforms, PSV 76cm/s. Moderate calcified disease in the distal vessel with reduced monophasic waveforms, PSV 36cm/s.

POPA: Moderate calcified disease in the proximal vessel and mild disease in the distal vessel, reduced monophasic waveforms along length, PSV 31-35cm/s. TPT appears patent with 3 vessel run off identified.

ATA: Origin appears patent with slightly reduced monophasic waveforms, PSV 85cm/s. Vessel then appears chronically occluded to ankle.

PTA: Mild disease in the proximal vessel with reduced monophasic waveforms. Vessel then appears chronically occluded to ankle.

PerA: Mild disease along length with reduced monophasic waveforms at ankle, PSV 28cm/s.

LEFT

CIA: Appears ectatic measuring TS-1.24cm, LS-1.30cm. Mild/moderate calcified disease

EIA: Mild/moderate calcified disease with good biphasic waveforms, PSV 139-156cm/s.

CFA: Moderate calcified disease with good triphasic waveforms, PSV 110cm/s.

PFA: Moderate stenosis identified in the proximal vessel with velocities increasing to 342cm/s. Stenosis length ~0.33cm.

SFA: Moderate calcified disease in the proximal vessel with good biphasic waveforms, PSV 76cm/s. Vessel appears to occlude in the proximal thigh (71cm prox to MM). Flow reforms in the distal vessel (52cm prox to MM) via a collateral with slightly reduced monophasic waveforms, PSV 69cm/s. Moderate calcified disease in the distal vessel with reduced monophasic waveforms, PSV 36cm/s.

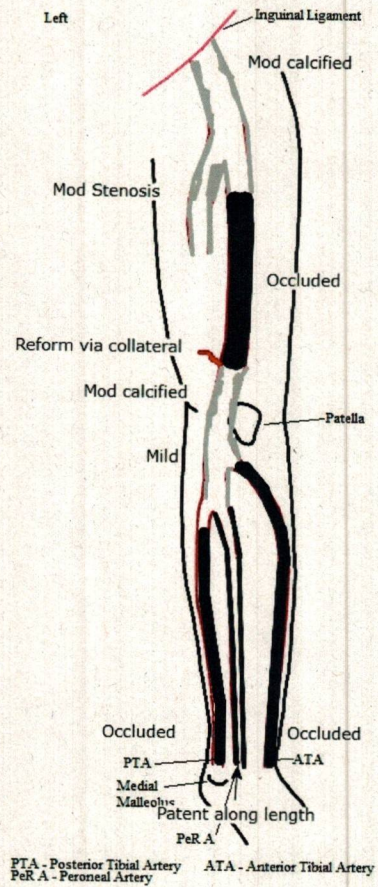
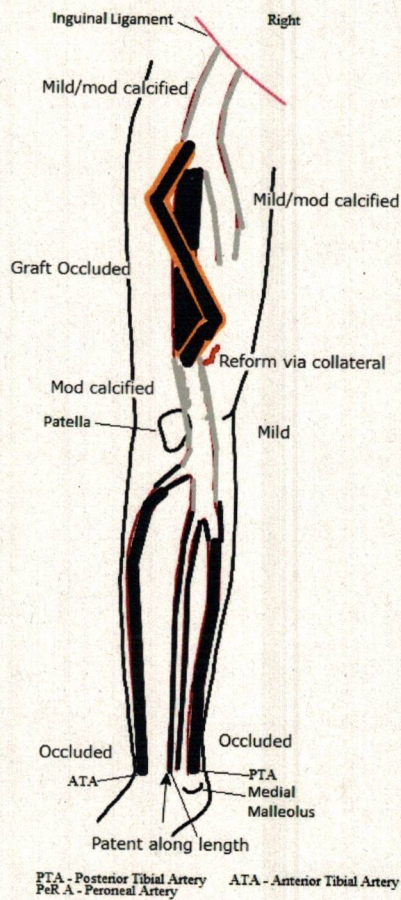
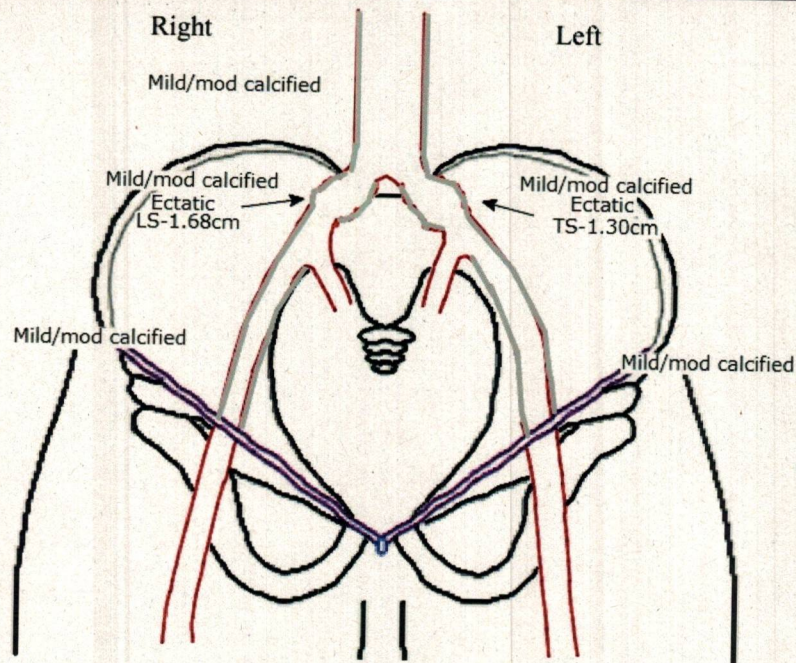
POPA: Moderate calcified disease in the proximal vessel and mild disease in the distal vessel, slightly reduced monophasic waveforms along length, PSV 50-53cm/s. TPT appears patent with 2 vessel run off identified.

ATA: Occluded along length.

PTA: Mild disease in the proximal vessel with slightly reduced monophasic waveforms, PSV 49cm/s.

PerA: Mild/moderate disease along length with reduced monophasic waveforms at the ankle, PSV 33cm/s.

ABPI: Unable to obtain resting ABPIs due to poor signals at ankle.



Reason	Graft synthetic Aorta-Bi-fem
Outcome	Calcified, Stenosis Moderate, Stenosis Severe, Significant disease indicated

Right		Left
<div> <div>170</div> <div>1.00</div> </div>	Brachial	
<div> </div> <div>Good</div>	Common Femoral	<div> </div> <div>Good</div>
	High Thigh	
	Low Thigh	
<div> </div> <div>Slightly Reduced</div>	Popliteal	
	High Calf	
<div> </div> <div>Reduced</div>	Peroneal	
<div> </div> <div>Slightly Reduced</div> <div>116</div> <div>0.68</div>	Anterior Tibial	<div> </div> <div>Good</div>
<div> </div> <div>Reduced</div>	Posterior Tibial	<div> </div> <div>Good</div>
	Dorsalis Pedis	
	Toe Pressure	
	Post Exercise	

Notes

RIGHT LOWER LIMB ARTERIAL DUPLEX SCAN
 *Previous aorta bi-femoral graft.

AORTA: Proximal aorta appears of normal, uniform calibre TS-2.1cm, LS-2.2cm. Mild disease with good bouncy monophasic waveforms, PSV 94cm/s.

AORTA BI-FEMORAL GRAFT

RIGHT LIMB

PROX ANAST: Widely patent with good triphasic waveforms, PSV 104cm/s.

GRAFT BODY: Widely patent with good bi/triphasic waveforms, PSV 63-88cm/s.

DIST ANAST (CFA): Mild/moderate calcified disease with good triphasic waveforms, PSV 72cm/s.

LEFT LIMB

PROX ANAST: Widely patent with good triphasic waveforms, PSV 214cm/s.

GRAFT BODY: Widely patent with good triphasic waveforms, PSV 80-194cm/s.

DIST ANAST: Widely patent with good triphasic waveforms, PSV 108cm/s.

RIGHT

PFA: Severe stenosis identified at vessel origin with velocities increasing from 96- 448cm/s. Stenosis length ~0.68cm. Turbulent biphasic waveforms distal to stenosis, PSV 174cm/s.

SFA: Mild/moderate calcified disease in the proximal vessel with slightly reduced biphasic waveforms, PSV 56cm/s. Moderate calcified disease with a focal Moderate stenosis identified in the mid vessel (59cm prox to MM) with velocities increasing from 65-174cm/s. Stenosis length ~0.87cm. Intermittent flow in the distal vessel due to heavily calcified disease with reduced monophasic waveforms, PSV 61cm/s. Multiple large collaterals noted.

POPA: Mild/moderate calcified disease along length with reduced monophasic waveforms proximally, PSV 61cm/s. and slightly reduced monophasic waveforms distally, PSV 75cm/s. TPT appears patent with 3 vessel run off identified.

ATA: Mild calcified disease with slightly reduced monophasic waveforms at ankle, PSV 66cm/s.

PTA: Mild/moderate calcified disease along length with reduced monophasic waveforms at the ankle, PSV 42cm/s.

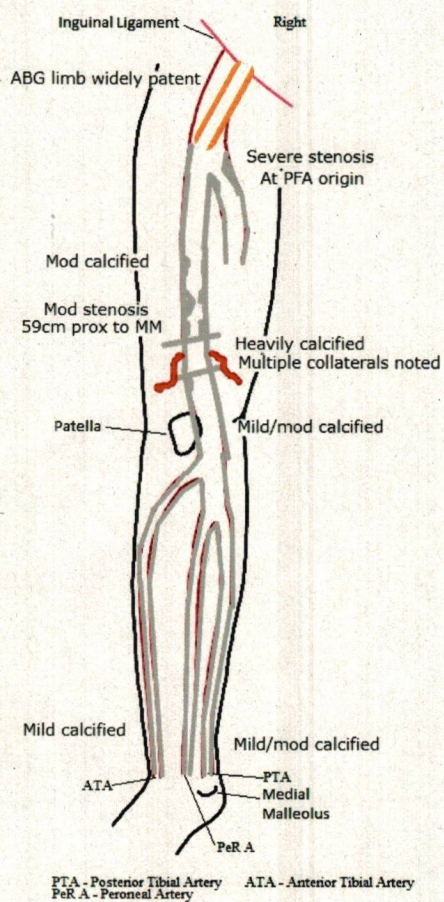
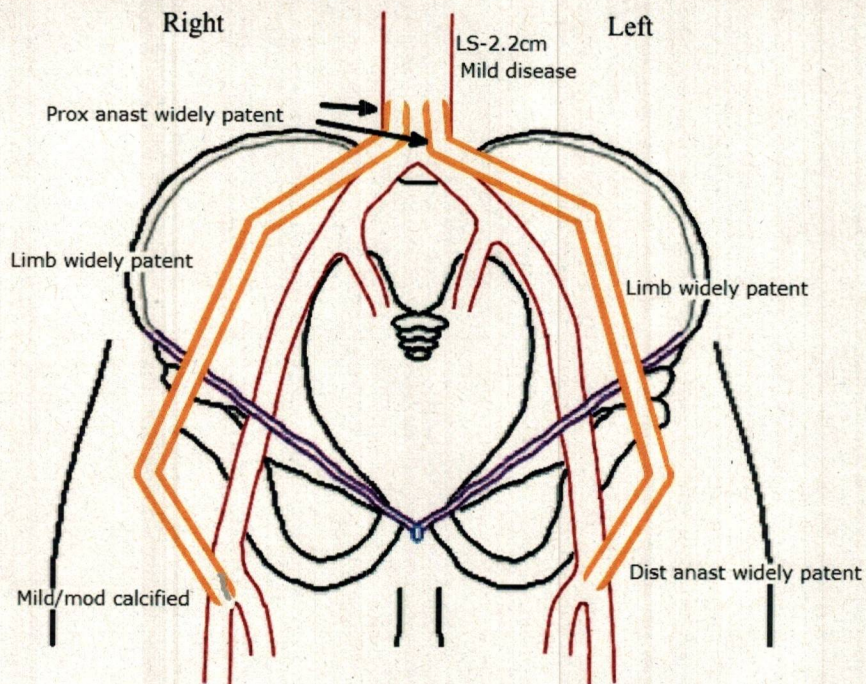
PerA: Mild/moderate calcified disease along length with reduced monophasic waveforms at the ankle, PSV 33cm/s.

LEFT

ATA: Good biphasic waveforms at ankle, PSV 181cm/s.

PTA: Good biphasic waveforms at ankle, PSV 137cm/s.

ABPI: The right resting ABPI is reduced. Unable to obtain left resting ABPI as patient could not tolerate inflation of pressure cuff.



Assessed by Jack Wilson

Printed on 16/11/2021 at 10:44 am

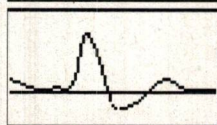
Checked by

Reason Claudication
Outcome Occlusion, Calcified, Significant disease indicated

Right

132

1.00



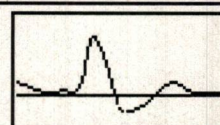
Good

Brachial

Common Femoral

Good

Left



High Thigh

Low Thigh

Popliteal

Good

High Calf

Peroneal

Good

Anterior Tibial

Good

Posterior Tibial

Good

Dorsalis Pedis

Toe Pressure

Post Exercise

Foot Flex

132

1.00

Notes

BILATERAL LOWER LIMB ARTERIAL DUPLEX SCAN

AORTA: Normal, uniform calibre TS-1.45cm, LS-1.45cm. Mild disease with good triphasic waveforms.

RIGHT

CIA: Poorly visualised due to bowel gas. Where seen appears patent with good triphasic waveforms, PSV 77cm/s.

EIA: Mild disease along length with good triphasic waveforms, PSV 107-126cm/s.

Assessed by Jack Wilson

Printed on 16/11/2021 at 10:47 am

Checked by

CFA: Mild disease with good triphasic waveforms, PSV 154cm/s.

PFA: Mild disease with good triphasic waveforms, PSV 103cm/s.

SFA: Mild, calcified disease along length with good triphasic waveforms, PSV 74-110cm/s.

POPA: Mild disease in the proximal to mid vessel with good mono/triphasic waveforms, PSV 67cm/s. Mid to distal vessel appears chronically occluded (41cm prox to MM). Multiple collateral vessels noted. Flow appears to reform in the proximal TPT (34cm prox to MM) via a collateral with reduced monophasic waveforms, PSV 30cm/s. 2 Vessel run off identified

ATA: Vessel origin poorly visualised, no flow identified where seen ?Occluded. Mild disease along length with reduced monophasic waveforms in the proximal vessel, PSV 33cm/s. Slightly reduced mono/triphasic waveforms at ankle, PSV 42cm/s.

PTA: Mild disease along length with slightly reduced monophasic waveforms at ankle, PSV 52cm/s.

PerA: Mild disease along length with slightly reduced monophasic waveforms at ankle, PSV 52cm/s.

LEFT

CIA: Poorly visualised due to bowel gas. Where seen appears patent with good triphasic waveforms, PSV 77cm/s.

EIA: Mild disease along length with good triphasic waveforms, PSV 107-126cm/s.

CFA: Mild disease with good triphasic waveforms, PSV 120cm/s.

PFA: Mild disease with good triphasic waveforms, PSV 74cm/s.

SFA: Mild, calcified disease along length with good triphasic waveforms, PSV 109-134cm/s.

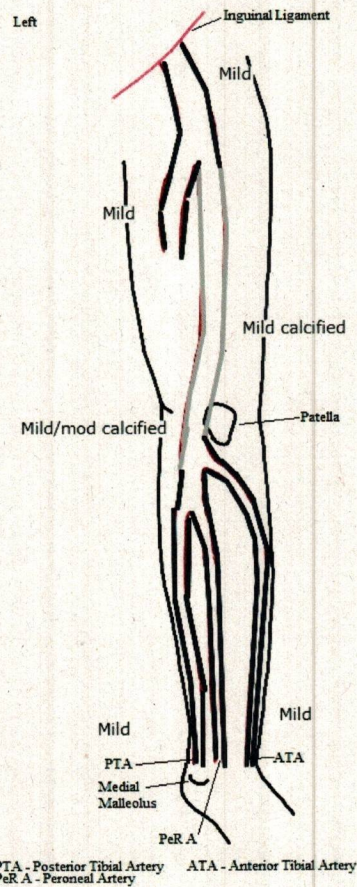
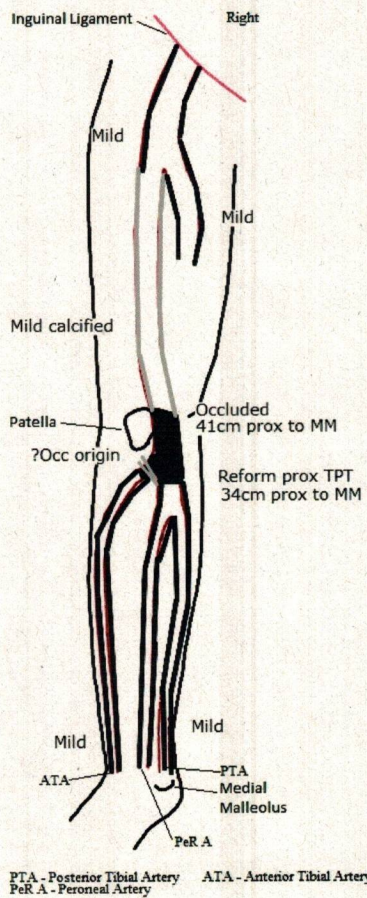
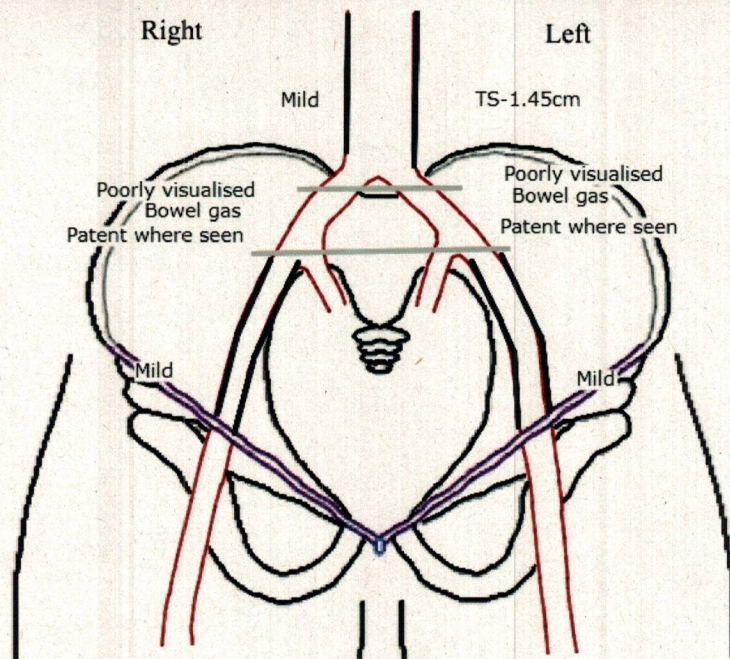
POPA: Mild/moderate, calcified disease along length with good triphasic waveforms, PSV 93-147cm/s. TPT appears patent with 3 vessel run off identified

ATA: Mild disease with good biphasic waveforms at ankle, PSV 120cm/s.

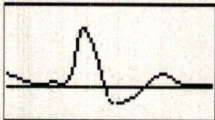
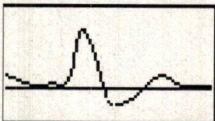
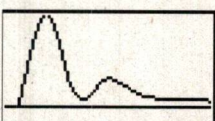


PTA: Mild disease with good hyperaemic waveforms at ankle, PSV 143cm/s.

PerA: Mild disease with good biphasic waveforms at ankle, PSV 58cm/s.

ABPI: The right resting ABPI is reduced. The left resting ABPI is within normal limits and remains so after a 1 minute foot flex exercise test.



Reason Ulceration
Outcome disease mild, Calcified, Poor images, Oedema

Right			Left
	Good	Brachial	
		Common Femoral	Good
	Good	High Thigh	
		Low Thigh	
		Popliteal	
	Good	High Calf	
		Peroneal	Reduced
	Slightly Reduced	Anterior Tibial	Slightly Reduced
	Slightly Reduced	Posterior Tibial	Absent
		Dorsalis Pedis	
		Toe Pressure	
		Post Exercise	

Notes

RIGHT LOWER LIMB ARTERIAL DUPLEX SCAN

AORTA: Proximal vessel appears slightly ectatic measuring TS-1.85cm, LS-1.94cm. Mild, calcified disease with good triphasic waveforms, PSV 132cm/s.

RIGHT

CIA: Mild, calcified disease with good triphasic waveforms, PSV 126cm/s.

EIA: Mild, calcified disease with good triphasic waveforms, PSV 123-125cm/s.

Assessed by Jack Wilson

Printed on 16/11/2021 at 10:49 am

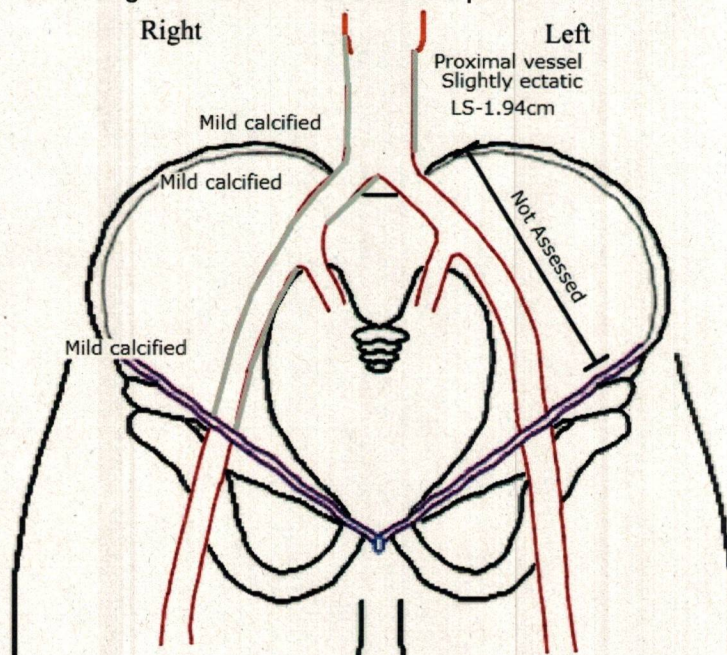
Checked by

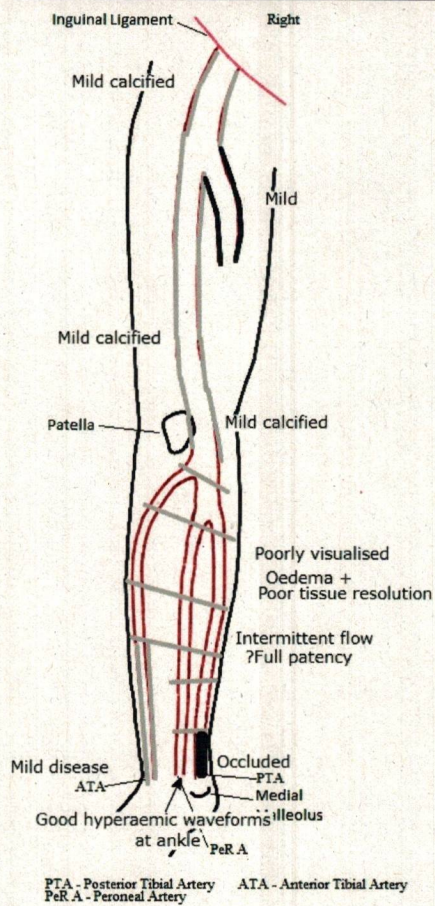
CFA: Mild, calcified disease with good triphasic waveforms, PSV 83cm/s.
PFA: Mild disease with good triphasic waveforms, PSV 49cm/s.
SFA: Mild, calcified disease with good bi/triphasic waveforms, PSV 49-69cm/s.
POPA: Mild, calcified disease with good bi/triphasic waveforms, PSV 37-64cm/s. TPT was challenging to visualise due to superficial oedema, unable to assess vessel run off.
ATA: Intermittent flow along length due to superficial oedema and poor tissue resolution. Patent at ankle with mild disease, slightly reduced mono/triphasic waveforms, PSV 34cm/s.
PTA: Intermittent flow in the proximal to distal vessel due to superficial oedema and calcification, slightly reduced monophasic waveforms where seen, PSV 34cm/s. Very distal vessel appears occluded.
PerA: Proximal to mid vessel not identified due to superficial oedema. Distal vessel appears patent with good hyperaemic waveforms at ankle, PSV 113cm/s.

LEFT

CFA: Good biphasic waveforms, PSV 83cm/s.
ATA: Slightly reduced monophasic waveforms at ankle, PSV 45cm/s.
PTA: Appears occluded at ankle.
PerA: Reduced monophasic waveforms at ankle, PSV 10cm/s.

ABPI: Unable to obtain resting ABPI due to ulceration and pain.

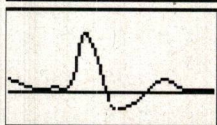




Graft synthetic fem-pop, Graft synthetic cross over

disease moderate, Occlusion, Calcified, Poor Images, Graft widely patent, Stenosis severe, Stenosis moderate

146	1.00
-----	------



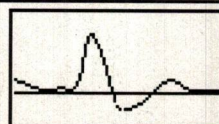
Good (Turbulent)

Brachial

Common Femoral

Good (Turbulent)

Left




High Thigh

Low Thigh

Popiteal


Reduced



High Calf

Peroneal

Reduced




Anterior Tibial

Reduced


96

0.66



Posterior Tibial

Absent



Dorsalis Pedis

Toe Pressure

Post Exercise

BILATERAL LOWER LIMB ARTERIAL DUPLEX ASSESSMENT

*Previous LT-RT FEM-FEM XOVER and RT FEM-POP BYPASS

*Irregular heart rate noted.

AORTA: Mild/moderate heavily calcified disease with reduced biphasic waveforms, PSV 38cm/s.

CIA: Moderate calcified disease with good triphasic waveforms, PSV 126cm/s.

Assessed by Jack Wilson

Printed on 16/11/2021 at 10:50 am

Checked by

EIA: Proximal to mid vessel was obscured by bowel gas and heavy calcification. Moderate calcified disease in the distal vessel with good triphasic waveforms, PSV 236cm/s.

LT-RT FEM-FEM XOVER GRAFT

PROX ANAST: Mild calcified disease with turbulent, high velocity waveforms, PSV 416cm/s. ?Due to calibre change ?Moderate stenosis.

GRAFT BODY: Widely patent along length with turbulent triphasic waveforms, PSV 117-158cm/s.

DIST ANAST: Widely patent with turbulent biphasic waveforms, PSV 166cm/s.

CFA: Mild calcified disease with turbulent triphasic waveforms, PSV 150cm/s.

PFA: Proximal vessel was poorly visualised due to heavy calcification, where seen high velocity, turbulent flow identified, PSV 220cm/s. ?Moderate stenosis.

SFA: Vessel appears chronically occluded from its origin. Flow reforms in the distal vessel via a collateral with slightly reduced monophasic waveforms, PSV 78cm/s. Very distal vessel was poorly visualised due to heavily calcified disease, where seen, ?Severe stenosis identified with velocities increasing from 27-261cm/s.

POPA: Moderate calcified disease in the proximal vessel and mild, calcified disease in the distal vessel, reduced monophasic waveforms, PSV 27-41cm/s.

ATA: Mild/moderate calcified disease with reduced monophasic waveforms at ankle, PSV 22cm/s.

PTA: Appears occluded along length.

PERA: Intermittent flow along length due to heavy calcification ?Full patency. Reduced monophasic waveforms at ankle, PSV 15cm/s.

RIGHT

CIA: Appears occluded.

EIA: Poorly visualised along length due to extensive bowel gas. Appears occluded where seen.

CFA: Mild/moderate calcified disease with turbulent triphasic waveforms, PSV 107cm/s. Vessel appears slightly aneurysmal TS-1.62cm, LS- 1.63cm.

PFA: Mild/moderate calcified disease with good triphasic waveforms, PSV 155cm/s.

SFA: Appears stented and occluded.

FEM-POP BYPASS GRAFT

PROX ANAST (CFA): Mild disease with good turbulent triphasic waveforms, PSV 96cm/s.

GRAFT BODY: Widely patent along length with slightly reduced biphasic waveforms, PSV 48-61cm/s.

DIST ANAST (DIST SFA/ PROX POPA): Mild calcified disease with turbulent, high velocity waveforms, PSV 211cm/s. ?Due to calibre change ?Moderate stenosis.

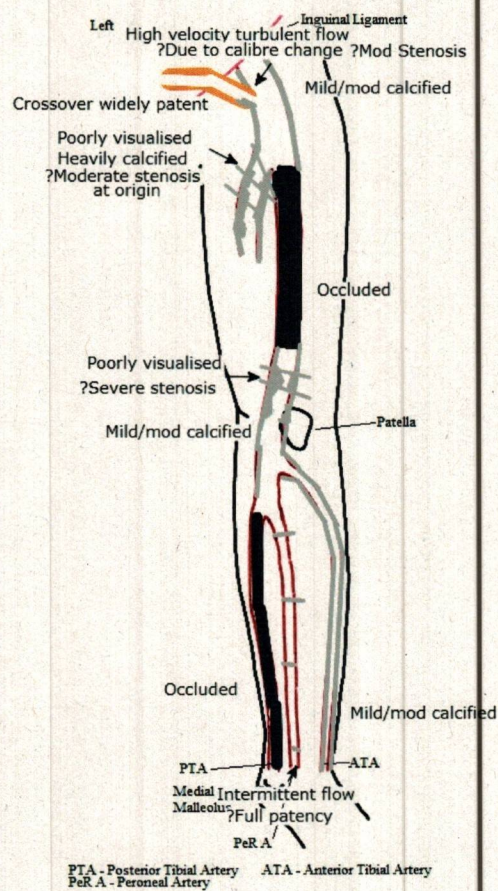
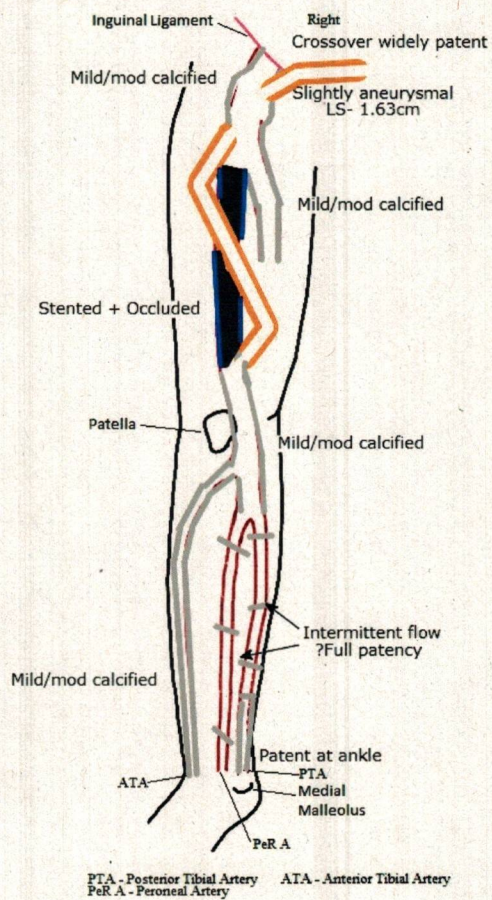
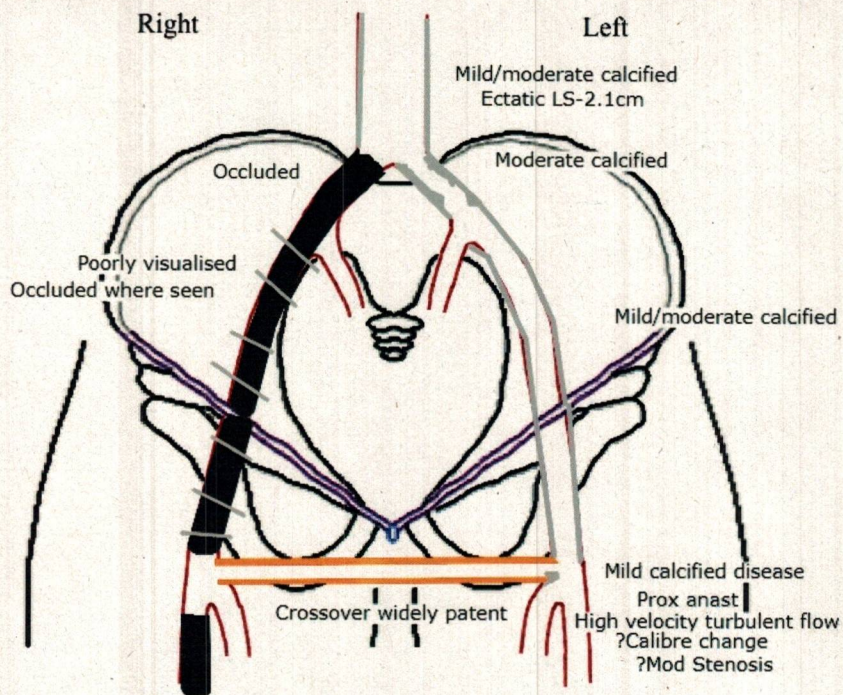
POPA: Mild/moderate calcified disease with good biphasic waveforms in the proximal vessel, PSV 124cm/s and good mono/triphasic waveforms in the distal vessel, PSV 94cm/s.

ATA: Mild/moderate calcified disease with good biphasic waveforms at ankle, PSV 64cm/s.

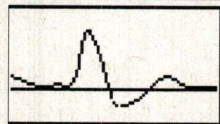
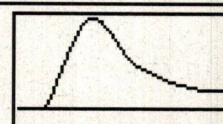

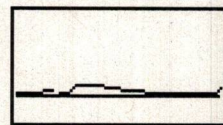



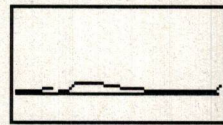
PTA: Intermittent flow in the proximal to mid vessel ?Full patency with slightly reduced monophasic waveforms, PSV 60cm/s. Large collateral noted at the distal vessel. Patent at ankle with slightly reduced monophasic waveforms, PSV 40cm/s.

PERA: Intermittent flow along length due to heavy calcification ?Full patency, slightly reduced biphasic waveforms at ankle, PSV 51cm/s.

ABPI: The right resting ABPI is within normal limits. The left resting ABPI is reduced.



Reason	Claudication
Outcome	disease moderate, Occlusion, Calcified, Stenosis Moderate, Significant disease indicated

Right		Left
<div><div>134</div><div>1.00</div></div> <div></div> <div>Good</div>	Brachial	<div></div>
	Common Femoral	<div>Good</div>
	High Thigh	
	Low Thigh	
	Popliteal	<div>Reduced</div> <div></div>
	High Calf	
	Peroneal	<div>Weak</div> <div></div>
<div></div> <div>Reduced</div>	Anterior Tibial	<div>Weak</div> <div></div>
<div></div> <div>Reduced</div> <div>51</div> <div>0.38</div>	Posterior Tibial	<div>Weak</div> <div>45</div> <div>0.34</div> <div></div>
	Dorsalis Pedis	
	Toe Pressure	
	Post Exercise	

Notes

LEFT LOWER LIMB ARTERIAL DUPLEX SCAN

AORTA: Normal, uniform calibre TS-1.7cm, LS-1.7cm. Mild/moderate calcified disease with slightly reduced triphasic waveforms, PSV 56cm/s.

LEFT

CIA: Moderate calcified disease with good triphasic waveforms, PSV 73cm/s.

EIA: Mild/Moderate calcified disease along length with good triphasic waveforms, PSV 120-127cm/s.

Assessed by Jack Wilson

Printed on 16/11/2021 at 10:51 am

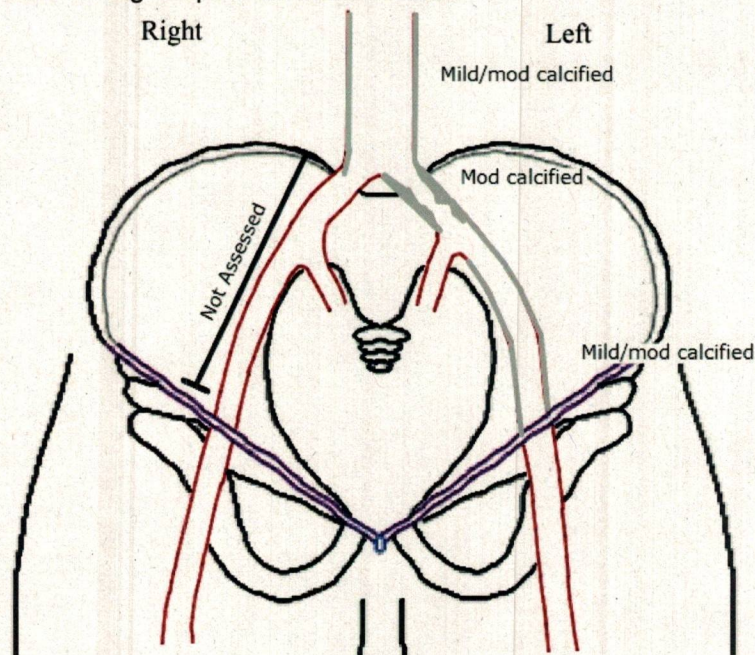
Checked by

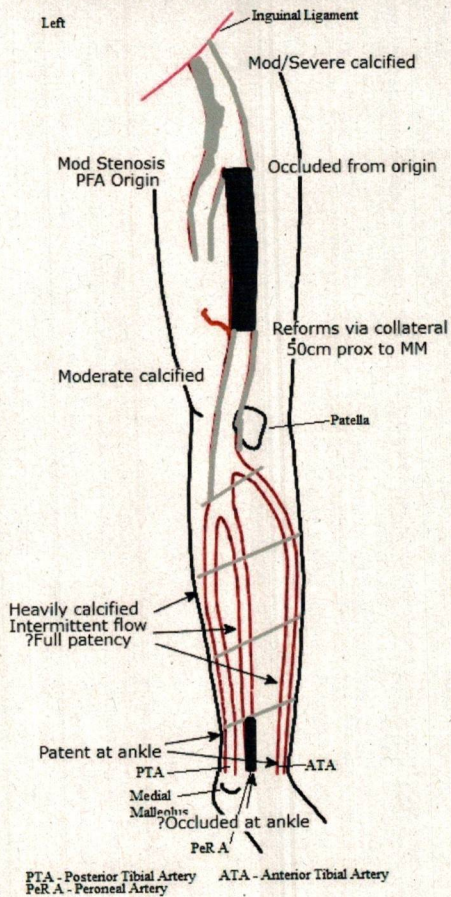
CFA: Moderate/severe calcified disease with good monophasic waveforms, PSV 140cm/s.
PFA: Moderate stenosis identified at vessel origin with velocities increasing to 328cm/s. Stenosis length ~0.86cm. Mild disease with good triphasic waveforms identified distal to stenosis, PSV 75cm/s.
SFA: Vessel appears chronically occluded from its origin. Flow reforms in the mid/distal vessel via a collateral (50cm prox to MM) with reduced monophasic waveforms, PSV 16cm/s. Moderate calcified disease in the distal vessel with reduced monophasic waveforms, PSV 19cm/s.
POPA: Mild/Moderate calcified disease with reduced monophasic waveforms, PSV 14-24cm/s. Intermittent flow through TPT due to heavy calcification unable to assess vessel run off.
ATA: Intermittent flow along length due to heavy calcification, weak monophasic waveforms at ankle, PSV 16cm/s.
PTA: Intermittent flow along length due to heavy calcification, weak monophasic waveforms at ankle, PSV 23cm/s.
PerA: Intermittent flow in the proximal to mid vessel due to heavy calcification, weak monophasic waveforms, PSV 23cm/s. No flow identified at ankle ?Occluded.

RIGHT

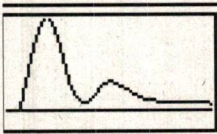
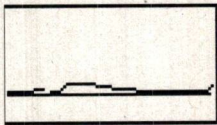
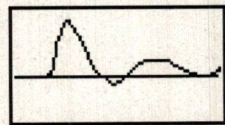
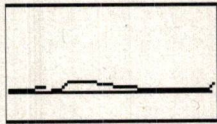
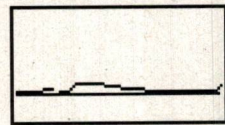
CFA: Good triphasic waveforms, PSV 75cm/s.
ATA: Reduced monophasic waveforms at ankle, PSV 24cm/s.
PTA: Reduced monophasic waveforms at ankle, PSV 30cm/s.

ABPI: Unable to obtain resting ABPIs due to incompressible calf vessels.
TBPI: The right and left resting toe pressures are reduced.





Reason	Stent
Outcome	disease mild, disease moderate, Occlusion, Calcified, Stenosis Moderate, Significant disease indicated

Right			Left	
		Brachial	156	1.00
	Good	Common Femoral	Good	
		High Thigh		
		Low Thigh		
	Reduced	Popliteal	Good	
		High Calf		
	Reduced	Peroneal	Weak	
	Slightly Reduced	Anterior Tibial	Good	
	Slightly Reduced	Posterior Tibial	Slightly Reduced	
		Dorsalis Pedis		
	Reduced	Toe Pressure	Slightly Reduced	
	72		101	0.65
	0.46	Post Exercise		

Notes

BILATERAL LOWER LIMB ARTERIAL DUPLEX SCAN

AORTA: Normal uniform calibre (TS-1.2cm, LS-1.2cm). Mild/moderate calcified disease with good triphasic waveforms, PSV 71cm/s.

RIGHT

CIA: Appears stented. Stent appears patent with good triphasic waveforms, PSV 129cm/s.

Assessed by Jack Wilson

Printed on 16/11/2021 at 10:53 am

Checked by

EIA: Mild/moderate calcified disease along length with good triphasic waveforms, PSV 134-187cm/s.

CFA: Appears reconstructed. Mild/moderate calcified disease with good mono/triphasic waveforms, PSV 140cm/s.

PFA: Mild calcified disease with good triphasic waveforms, PSV 81cms.

SFA: Moderate calcified disease in the proximal vessel and mild/moderate calcified disease in the mid vessel with good triphasic waveforms, PSV 57-62cm/s. Moderate diffuse calcified disease in the mid to distal vessel with reduced monophasic waveforms, PSV 13cm/s. Very distal vessel appears chronically occluded (41cm prox to MM).

POPA: Proximal vessel is chronically occluded. Flow reforms in the mid vessel at the level of the knee crease via a collateral with reduced monophasic waveforms, PSV 13cm/s. Mild/moderate calcified disease in the distal vessel with reduced monophasic waveforms, PSV 10cm/s. TPT appears patent with 2 vessel run off identified.

ATA: Proximal vessel is heavily calcified with no colour flow identified ?Occluded. Flow appears to reform in the very proximal vessel via a collateral. Mild/moderate calcified disease along length with slightly reduced monophasic waveforms at ankle, PSV 30cm/s.

PTA: Mild/moderate calcified disease along length with slightly reduced monophasic waveforms at ankle, PSV 30cm/s.

PerA: Intermittent flow along length. Weak monophasic waveforms at ankle, PSV 8cm/s.

LEFT

CIA: Appears stented. Stent appears patent with good triphasic waveforms, PSV 1152cm/s.

EIA: Mild/moderate calcified disease along length with good triphasic waveforms, PSV 83-194cm/s.

CFA: Appears reconstructed. Mild/moderate calcified disease with good mono/triphasic waveforms, PSV 146cm/s.

PFA: Mild/moderate calcified disease with good triphasic waveforms, PSV 81cms.

SFA: Moderate calcified disease in the proximal vessel with good triphasic waveforms, PSV 68cm/s. Area of moderate, diffuse, heavily calcified disease identified in the mid vessel with a moderate focal stenosis (49cm prox to MM) with velocities increasing from 61-130cm/s. Intermittent flow in the distal vessel due to heavy calcification. Where seen, distal vessel appears patent with good triphasic waveforms, PSV 113cm/s.

POPA: Moderate calcified disease in the proximal vessel and mild/moderate calcified disease in the distal vessel with good triphasic waveforms, PSV 42-87cm/s. TPT appears patent with 3 vessel run off identified.

ATA: Mild/moderate calcified disease along length with good biphasic waveforms at ankle, PSV 41cm/s.

PTA: Mild/moderate calcified disease along length with slightly reduced triphasic waveforms at ankle, PSV 27cm/s.

PerA: Intermittent flow along length. Weak monophasic waveforms at ankle, PSV 10cm/s.

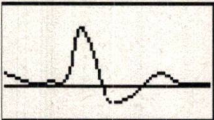

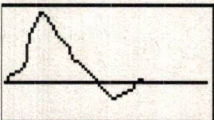
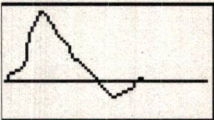
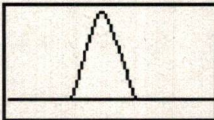
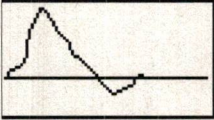

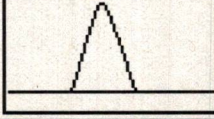
TBPI: The right resting TBPI is reduced. The left resting TBPI is within normal limits.

LEFT BRACHIAL: 156mmHg

RIGHT TOE: 72mmHg

LEFT TOE: 101mmHg

Reason Routine
Outcome disease mild, disease moderate, Calcified, Stenosis Moderate

Right		Left
<div>154</div> <div>1.00</div>  <div>Good</div>	Brachial	
	Common Femoral	<div>Good</div> 
	High Thigh	
	Low Thigh	
 <div>Good</div>	Popliteal	
	High Calf	
 <div>Good</div>	Peroneal	<div>Good</div> 
 <div>Good</div> <div>176</div> <div>1.14</div>	Anterior Tibial	
 <div>Reduced</div>	Posterior Tibial	<div>Good</div> <div>128</div> <div>0.83</div> 
	Dorsalis Pedis	
	Toe Pressure	
	Post Exercise	

Notes

RIGHT LOWER LIMB ARTERIAL DUPLEX SCAN

AORTA: Normal, uniform calibre with maximum dimensions (TS-2.0cm, LS-2.1cm). Mild/moderate calcified disease with with good biphasic waveforms, PSV 75cm/s.

RIGHT

CIA: Mild/moderate calcified disease with good triphasic waveforms, PSV 156cm/s.

EIA: Proximal vessel was obscured by bowel gas. Mild calcified disease in the mid to distal vessel with good

Assessed by Jack Wilson

Printed on 16/11/2021 at 12:40 pm

Checked by

triphasic waveforms, PSV 102cm/s.

CFA: Mild/moderate calcified disease with good triphasic waveforms, PSV 158cm/s.

PFA: Mild/moderate stenosis at origin with velocities increasing to 229cm/s. Stenosis length ~0.46cm. Mild disease distal to stenosis with turbulent biphasic waveforms, PSV 90cm/s.

SFA: Mild calcified disease along length with good biphasic waveforms, PSV 87-114cm/s.

POPA: Mild calcified disease along length with good biphasic waveforms, PSV 87-114cm/s. TPT appears patent with 3 vessel run off identified.

ATA: Mild/moderate calcified disease along length with good biphasic waveforms at ankle, PSV 106cm/s.

PTA: Moderate calcified disease in the proximal to mid vessel with good triphasic waveforms, PSV 111cm/s. Mid to distal vessel appears occluded. Flow reforms in the distal vessel with reduced biphasic waveforms at the ankle, PSV 26cm/s.

PerA: Mild/moderate calcified disease along length with good biphasic waveforms at ankle, PSV 83cm/s.

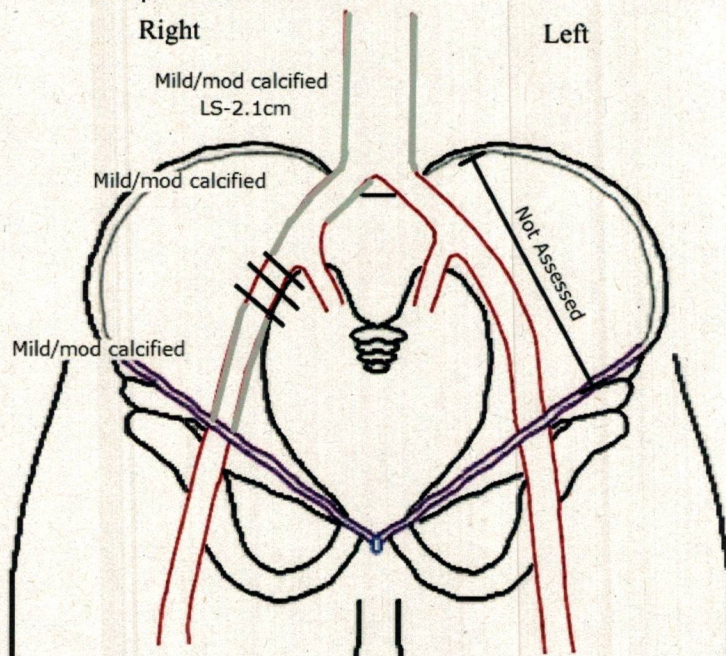
LEFT

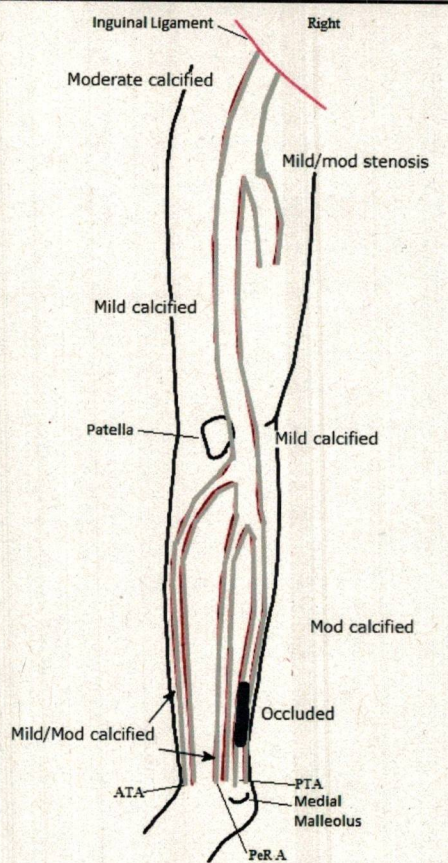
CFA: Moderate calcified disease with good triphasic waveforms, PSV 72cm/s.

PTA: Good monophasic waveforms at ankle, PSV 66cm/s.

PerA: Good monophasic waveforms at ankle, PSV 50cm/s.

ABPI: The right and left resting ABPIs are within normal limits. Left pressure is significantly lower than right. Patient unable to perform adequate exercise test.





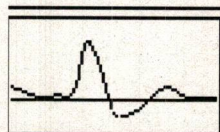
PTA - Posterior Tibial Artery ATA - Anterior Tibial Artery
PeR.A - Peroneal Artery

Reason	Routine
Outcome	No significant disease indicated

Right

Left

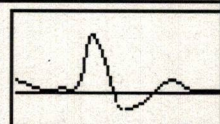
Brachial



Good

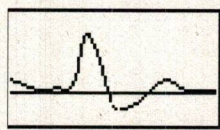
Common Femoral

Good



High Thigh

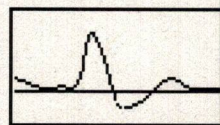
Low Thigh



Good

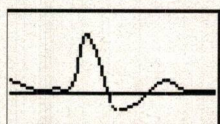
Popliteal

Good



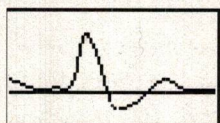
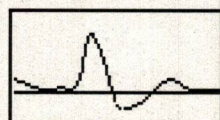
High Calf

Peroneal



Good

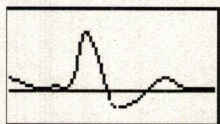
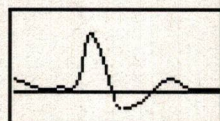
Good



Good

Anterior Tibial

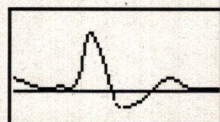
Good



Good

Posterior Tibial

Good



Dorsalis Pedis

Toe Pressure

Post Exercise

Notes

BILATERAL LOWER LIMB ARTERIAL DUPLEX SCAN

RIGHT

CFA: Mild disease with good triphasic waveforms, PSV 97cm/s.

PFA: Mild disease with good triphasic waveforms, PSV 53cm/s.

SFA: Mild, calcified disease with good triphasic waveforms, PSV 52-103cm/s.

POPA: Mild disease with good triphasic waveforms, PSV 88-108cm/s.

ATA: Patent at ankle with good triphasic waveforms, PSV 90cm/s.

Assessed by Jack Wilson

Printed on 16/11/2021 at 12:42 pm

Checked by

PTA: Patent at ankle with good triphasic waveforms, PSV 106cm/s.
PerA: Patent at ankle with good triphasic waveforms, PSV 42cm/s.

LEFT

CFA: Mild disease with good triphasic waveforms, PSV 97cm/s.
PFA: Mild disease with good triphasic waveforms, PSV 53cm/s.
SFA: Mild, calcified disease with good triphasic waveforms, PSV 73-121cm/s.
POPA: Mild disease with good triphasic waveforms, PSV 75cm/s.
ATA: Patent at ankle with good triphasic waveforms, PSV 53cm/s.
PTA: Patent at ankle with good triphasic waveforms, PSV 122cm/s.
PerA: Patent at ankle with good triphasic waveforms, PSV 31cm/s.

Conclusion: No evidence of significant right or left lower limb arterial disease detected from this scan

Reason	Ulceration
Outcome	disease mild, disease moderate, Calcified

Right

Left

Brachial

Common Femoral

Good

High Thigh

Low Thigh

Popliteal

Good

High Calf

Peroneal

Good

Anterior Tibial

Good

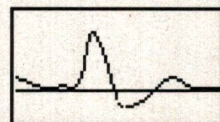
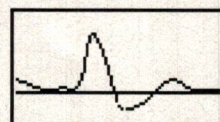
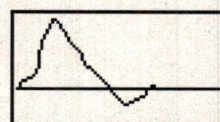
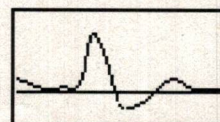
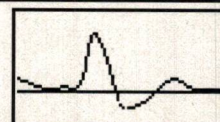
Posterior Tibial

Good

Dorsalis Pedis

Toe Pressure

Post Exercise



Notes

LEFT LOWER LIMB ARTERIAL DUPLEX SCAN

*Patient scanned in chair due to poor mobility. Some poor images obtained.

AORTA: Obscured by bowel gas.

LEFT

CIA: Obscured by bowel gas.

EIA: Proximal vessel obscured by bowel gas. Mild/moderate calcified disease in the mid to distal vessel with good triphasic waveforms, PSV 60cm/s.

Assessed by Jack Wilson

Printed on 16/11/2021 at 12:44 pm

Checked by

CFA: Mild/moderate calcified disease with good triphasic waveforms, PSV 89cm/s.

PFA: Mild calcified disease with good triphasic waveforms, PSV 73cm/s.

SFA: Mild disease in the proximal vessel with good triphasic waveforms, PSV 60cm/s. Stent identified in the mid vessel. Stent appears widely patent with good triphasic waveforms, PSV 45cm/s. Moderate disease in the distal vessel with good triphasic waveforms, PSV 64cm/s.

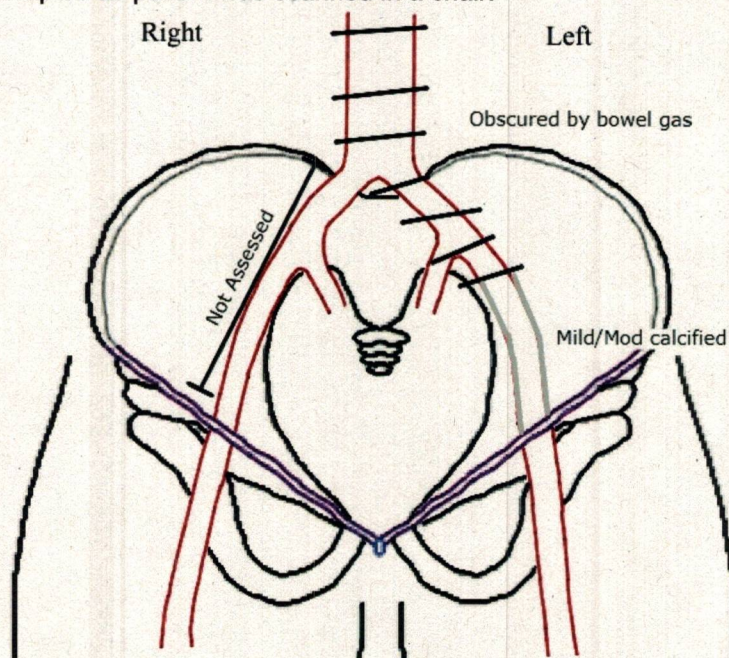
POPA: Stent identified in the proximal vessel. Stent appears widely patent with good triphasic waveforms, PSV 53cm/s. Mild disease in the distal vessel with good triphasic waveforms, PSV 127cm/s. TPT was poorly visualised due to poor tissue resolution and hostile skin. Unable to assess vessel run off.

ATA: Mild/moderate disease along length with good triphasic waveforms at ankle, PSV 127cm/s.

PTA: Mild/moderate disease along length with good triphasic waveforms at ankle, PSV 47cm/s.

PerA: Poorly visualised along length due to poor tissue resolution and hostile skin. Patent at ankle with good biphasic waveforms, PSV 30cm/s.

ABPI: ABPI not attempted as patient was scanned in a chair.



Reason Claudication
 Outcome disease mild, disease moderate, Stenosis Moderate

Right		Left
<div>122 1.00</div> <div></div> <div>Good</div>	Brachial	
	Common Femoral	
	High Thigh	
	Low Thigh	
<div>Good</div> <div></div>	Popliteal	
	High Calf	
<div>Good</div> <div></div>	Peroneal	
<div>Good</div> <div>138 1.13</div> <div></div>	Anterior Tibial	
<div>Slightly Reduced</div> <div></div>	Posterior Tibial	
	Dorsalis Pedis	
	Toe Pressure	
<div>Foot Flex</div> <div>130 1.07</div>	Post Exercise	

Notes

RIGHT LOWER LIMB ARTERIAL DUPLEX SCAN

RIGHT

CFA: Mild disease with good triphasic waveforms, PSV 148cm/s.

PFA: Mild disease with good triphasic waveforms, PSV 152cm/s.

SFA: Mild/Moderate calcified disease in the proximal to mid vessel with good triphasic waveforms, PSV 135cm/s. Mild/Moderate stenosis identified in the mid vessel with velocities increasing from 124-227cm/s. Stenosis length ~0.53cm. Moderate calcified disease in the distal vessel with good biphasic waveforms,

Assessed by Jack Wilson

Printed on 16/11/2021 at 12:45 pm

Checked by

PSV 110cm/s.

POPA: Mild/moderate calcified disease with good bi/triphasic waveforms, PSV 77-107cm/s. TPT appears patent with 3 vessel run off identified.

ATA: Mild/moderate calcified disease with good mono/triphasic waveforms at ankle, PSV 151cm/s.

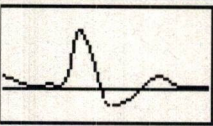
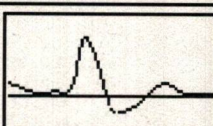
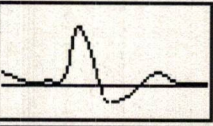
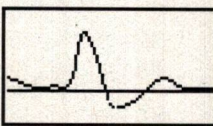
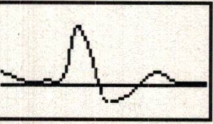
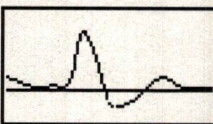
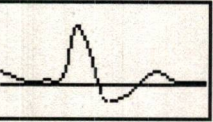
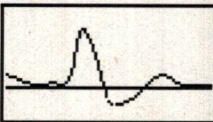
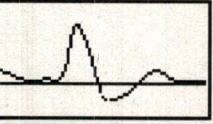
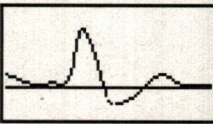
PTA: Mild/moderate calcified disease in the proximal to mid vessel with good biphasic waveforms, PSV 92cm/s. Vessel becomes very small calibre distally with good monophasic waveforms at ankle, PSV 37cm/s.

PerA: Mild/moderate calcified disease with good mono/triphasic waveforms at ankle, PSV 66cm/s.

ABPI: The right resting ABPI is within normal limits and remains so after a 1 minute foot flex exercise test.

Conclusion: Evidence of right SFA mild/moderate stenosis identified from this scan.

Reason Routine
Outcome disease mild, No significant disease indicated

Right				Left	
	120 1.00	Brachial			
	Good	Common Femoral	Good		
		High Thigh			
	Good	Low Thigh			
		Popliteal	Good		
	Good	High Calf			
	Good	Peroneal	Good		
	130 1.08	Anterior Tibial	Good		
	Good	Posterior Tibial	Good		
		Dorsalis Pedis			
		Toe Pressure			
	Calf Raises	Post Exercise	Calf Raises		
	134 1.12		138 1.15		

Notes

BILATERAL LOWER LIMB ARTERIAL DUPLEX SCAN

RIGHT

CFA: Mild disease with good triphasic waveforms, PSV 115cm/s.

PFA: Mild disease with good triphasic waveforms, PSV 71cm/s.

SFA: Mild disease with good triphasic waveforms, PSV 52-91cm/s.

POPA: Mild disease with good triphasic waveforms, PSV 58-63cm/s. TPT appears patent with 3 vessel run off identified.

Assessed by Jack Wilson

Printed on 16/11/2021 at 12:46 pm

Checked by

ATA: Mild disease with good triphasic waveforms at ankle, PSV 50cm/s.
PTA: Mild disease with good triphasic waveforms at ankle, PSV 57cm/s.
PerA: Mild disease with good triphasic waveforms at ankle, PSV 42cm/s.

LEFT

CFA: Mild disease with good triphasic waveforms, PSV 119cm/s.
PFA: Mild disease with good triphasic waveforms, PSV 93cm/s.
SFA: Mild disease with good triphasic waveforms, PSV 64-101cm/s.
POPA: Mild disease with good triphasic waveforms, PSV 53-62cm/s. TPT appears patent with 3 vessel run off identified.
ATA: Mild disease with good triphasic waveforms at ankle, PSV 64cm/s.
PTA: Mild disease with good triphasic waveforms at ankle, PSV 30cm/s.
PerA: Mild disease with good triphasic waveforms at ankle, PSV 42cm/s.

ABPI:

The right and left resting ABPIs are within normal limits and remain so after a 2 minute calf raise exercise test.

RIGHT BRACHIAL: 120mmHg
RIGHT ATA: 130mmHg (1.08)
RIGHT ATA POST EXERCISE: 134mmHg (1.12)

LEFT ATA: 130mmHg (1.08)
LEFT ATA POST EXERCISE: 138mmHg (1.15)

POPLITEAL ARTERY ENTRAPMENT

All scans performed in the prone position with resistance against movement.

RIGHT

AT REST

Prox POPA: Good triphasic waveforms, PSV 52cm/s (LS-0.85cm)
Dist POPA: Good triphasic waveforms, PSV 68cm/s (LS-0.70cm)

DORSIFLEXION

Prox POPA: Good triphasic waveforms, PSV 48cm/s (LS-0.87cm)
Dist POPA: Good triphasic waveforms, PSV 81cm/s (LS-0.64cm)

PLANTARFLEXION

Prox POPA: Good triphasic waveforms, PSV 55cm/s (LS-0.87cm)
Dist POPA: Good triphasic waveforms, PSV 79cm/s (LS-0.65cm)

LEFT

AT REST

Prox POPA: Good triphasic waveforms, PSV 115cm/s (LS-0.70cm)
Dist POPA: Good triphasic waveforms, PSV 91cm/s (LS-0.50cm)

DORSIFLEXION

Prox POPA: Good triphasic waveforms, PSV 86cm/s (LS-0.68cm)
Dist POPA: Good triphasic waveforms, PSV 96cm/s (LS-0.51cm)

PLANTARFLEXION

Prox POPA: Good triphasic waveforms, PSV 66cm/s (LS-0.71cm)

Dist POPA: Good triphasic waveforms, PSV 101cm/s (LS-0.59cm)

CONCLUSION: No evidence of right or left popliteal artery entrapment detected from this scan.

Assessed by Jack Wilson

Printed on 16/11/2021 at 12:46 pm

Checked by

Reason Ulceration
Outcome Occlusion, Calcified, Bowel gas, Poor images, Significant disease indicated

Right		Left
<div>130 1.00</div> <div></div> <div>Good</div>	Brachial	
	Common Femoral	
	High Thigh	
	Low Thigh	
<div></div> <div>Weak</div>	Popliteal	
	High Calf	
<div></div> <div>Absent</div>	Peroneal	
<div></div> <div>Weak</div>	Anterior Tibial	
<div></div> <div>Absent</div>	Posterior Tibial	
	Dorsalis Pedis	
<div>Weak</div> <div>44 0.34</div>	Toe Pressure	
	Post Exercise	

Notes

RIGHT LOWER LIMB ARTERIAL DUPLEX SCAN

AORTA: Obscured by bowel gas.

RIGHT

CIA: Poorly visualised due to bowel gas. Appears patent where seen with good triphasic waveforms, PSV 111cm/s.

EIA: Moderate calcified disease along length with good monophasic waveforms, PSV 66-111cm/s.

Assessed by Jack Wilson

Printed on 16/11/2021 at 12:47 pm

Checked by

CFA: Moderate calcified disease in the proximal with good monophasic waveforms, PSV 111cm/s. Distal vessel appears chronically occluded.

PFA: Poorly visualised due to heavy calcification. Multiple large collateral vessels noted. Patent where seen with reduced monophasic waveforms, PSV 65cm/s. ?Full patency.

SFA: Chronically occluded from its origin. Flow reforms in the distal thigh with weak monophasic waveforms, PSV 37cm/s. Moderate calcified disease in the distal vessel with weak monophasic waveforms, PSV 63cm/s.

POPA: Moderate calcified disease along length with weak monophasic waveforms, PSV 34-47cm/s. TPT was poorly visualised due to heavy calcification ?Full patency.

ATA: Intermittent flow along length due to heavy calcification, weak monophasic waveforms at ankle, PSV 16cm/s.

PTA: Intermittent flow in the proximal to mid vessel with weak monophasic waveforms, PSV 45cm/s. Distal vessel appears occluded.

PerA: Intermittent flow in the proximal vessel with weak monophasic waveforms, PSV 26cm/s. Mid to distal vessel appears occluded.

TBPI: The right resting toe pressure is reduced.

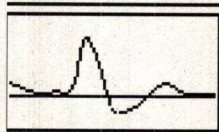
RIGHT BRACHIAL: 130mmHg

RIGHT TOE: 44mmHg (0.34)

Reason Routine
Outcome No significant disease indicated

Right

Left

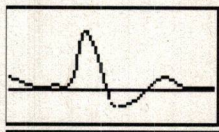
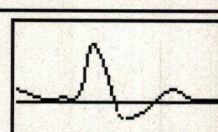


Good

Brachial

Common Femoral

Good



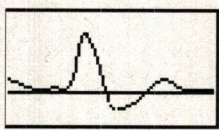
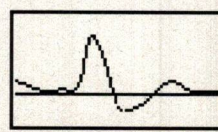
Good

High Thigh

Low Thigh

Popliteal

Good

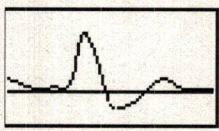
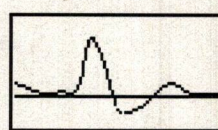


Good

High Calf

Peroneal

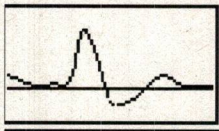
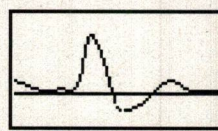
Good



Good

Anterior Tibial

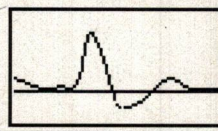
Good



Good

Posterior Tibial

Good



Dorsalis Pedis

Toe Pressure

Post Exercise

Notes

BILATERAL LOWER LIMB ARTERIAL DUPLEX SCAN

RIGHT

CFA: Mild disease with good triphasic waveforms, PSV 117cm/s.

PFA: Mild disease with good triphasic waveforms, PSV 65cm/s.

SFA: Mild disease with good triphasic waveforms, PSV 53-107cm/s.

POPA: Mild disease with good triphasic waveforms, PSV 64-72cm/s.

ATA: Patent at ankle with good triphasic waveforms, PSV 30cm/s.

Assessed by Jack Wilson

Printed on 16/11/2021 at 12:48 pm

Checked by

PTA: Patent at ankle with good triphasic waveforms, PSV 48cm/s.
PerA: Patent at ankle with good triphasic waveforms, PSV 46cm/s.

LEFT

CFA: Mild disease with good triphasic waveforms, PSV 113cm/s.
PFA: Mild disease with good triphasic waveforms, PSV 55cm/s.
SFA: Mild disease with good triphasic waveforms, PSV 68-85cm/s.
POPA: Mild disease with good triphasic waveforms, PSV 57-61cm/s.
ATA: Patent at ankle with good triphasic waveforms, PSV 50cm/s.
PTA: Patent at ankle with good triphasic waveforms, PSV 22cm/s.
PerA: Patent at ankle with good triphasic waveforms, PSV 50cm/s.

Conclusion: No evidence of significant right or left lower limb arterial disease detected from this scan.

Reason	Claudication
Outcome	Occlusion, Obscured, Calcified, Bowel gas, Poor images, Significant disease indicated

Right			Left	
	124 1.00	Brachial		
	Good	Common Femoral	Good	
		High Thigh		
		Low Thigh		
	Reduced	Popliteal	Reduced	
		High Calf		
	Reduced	Peroneal	Reduced	
	Reduced	Anterior Tibial	Reduced	
			164 1.32	
	Reduced	Posterior Tibial	Reduced	
	120 0.97			
		Dorsalis Pedis		
		Toe Pressure		
		Post Exercise		
	Foot Flex		Foot Flex	
	90 0.73		58 0.47	

Notes

BILATERAL LOWER LIMB ARTERIAL DUPLEX SCAN

AORTA: Poorly visualised due to bowel gas. Where seen appears slightly aneurysmal with maximum dimensions TS- (ITI:3.0cm, OTO:3.3cm), LS- (ITI:3.0cm, OTO:3.3cm). Mild/mod calcified disease with reduced biphasic waveforms, PSV 30cm/s.

RIGHT

CIA: Obscured by bowel gas.

Assessed by Jack Wilson

Printed on 16/11/2021 at 12:48 pm

Checked by

EIA: Moderate calcified disease in the proximal vessel, mild/mod calcified in the mid to distal vessel with good triphasic waveforms, PSV 77-108cm/s.

CFA: Mild/mod calcified disease with good mono/triphasic waveforms, PSV 156cm/s.

PFA: Mild/mod calcified disease with good mono/triphasic waveforms, PSV 94cm/s.

SFA: Appears chronically occluded from origin. Flow reforms in the distal vessel (55cm prox to MM) via a collateral with reduced monophasic waveforms, PSV 35cm/s. Mild/moderate calcified disease in the distal vessel with reduced monophasic waveforms, PSV 31cm/s. Vessel appears patent through adductor canal.

POPA: Mild/moderate calcified disease with reduced monophasic waveforms, PSV 18-19cm/s. TPT appears patent with 3 vessel run off identified.

ATA: Moderate, heavily calcified disease along length with reduced monophasic waveforms at ankle, PSV 25cm/s.

PTA: Moderate, heavily calcified disease along length with reduced monophasic waveforms at ankle, PSV 32cm/s.

PerA: Moderate, heavily calcified disease along length with reduced monophasic waveforms at ankle, PSV 18cm/s.

LEFT

CIA: Moderate calcified disease with good triphasic waveforms, PSV 53cm/s.

EIA: Proximal vessel was obscured due to bowel gas. Mild/ Mod calcified disease in the mid to distal vessel with good triphasic waveforms, PSV 108cm/s.

CFA: Mild/mod calcified disease in the proximal to mid vessel and moderate calcified disease in the distal vessel with good triphasic waveforms, PSV 85cm/s.

PFA: Mild/mod calcified disease with good biphasic waveforms, PSV 67cm/s.

SFA: Appears chronically occluded from origin. Flow reforms in the distal vessel (56cm prox to MM) via a collateral with turbulent biphasic waveforms, PSV 88cm/s. Moderate calcified disease in the distal vessel with reduced monophasic waveforms, PSV 22cm/s. Vessel appears patent through adductor canal.

POPA: Mild/mod calcified disease with reduced monophasic waveforms, PSV 21-22cm/s. TPT appears patent with 3 vessel run off identified.

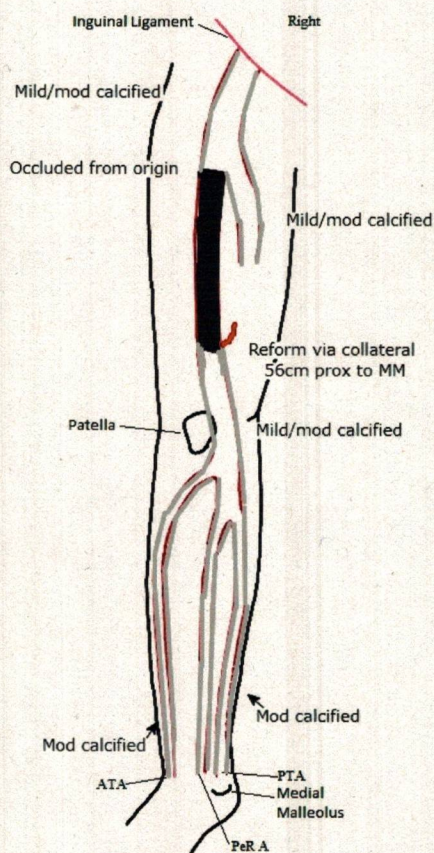
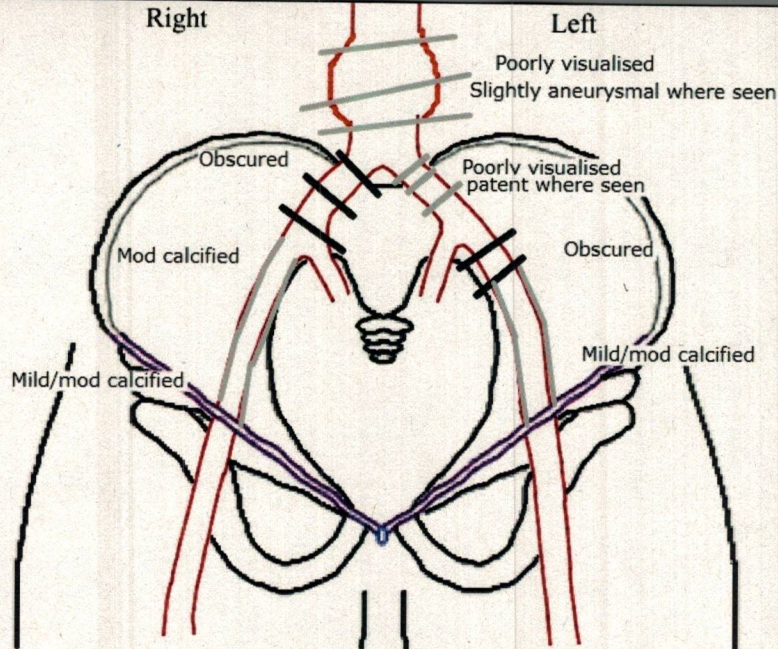
ATA: Moderate, heavily calcified disease along length with reduced monophasic waveforms at ankle, PSV 27cm/s.

PTA: Intermittent flow along length due to heavy calcification. Reduced monophasic waveforms at ankle, PSV 19cm/s.

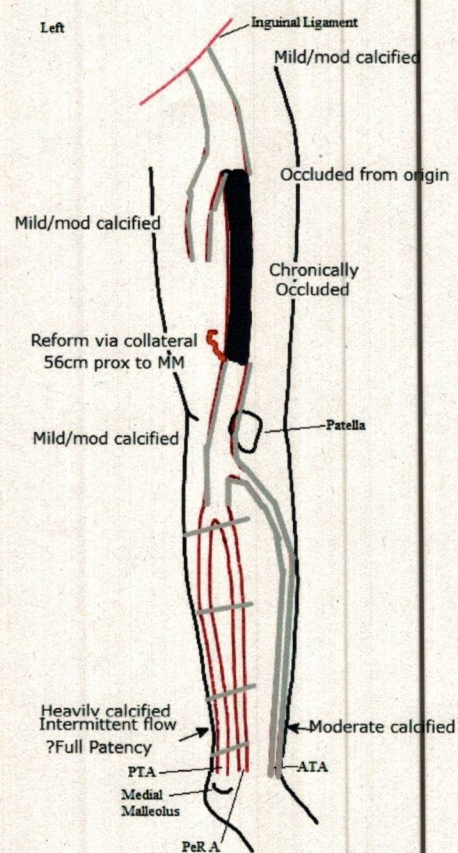
PerA: Intermittent flow along length due to heavy calcification. Reduced monophasic waveforms at ankle, PSV 13cm/s.

ABPI:

The right resting ABPI is within normal limits ?due to calcification and appears reduced after a 1 minute foot flex exercise test. The left resting ABPI is elevated ?Due to calcification and appears reduced after a 1 minute foot flex exercise test.



PTA - Posterior Tibial Artery
PeR A - Peroneal Artery
ATA - Anterior Tibial Artery



PTA - Posterior Tibial Artery
PeR A - Peroneal Artery
ATA - Anterior Tibial Artery

Assessed by Jack Wilson

Printed on 16/11/2021 at 12:48 pm

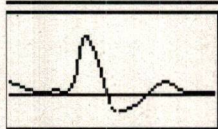
Checked by

Reason Ulceration
Outcome disease mild, disease moderate, Obscured, Poor images

Right

150

1.00



Good

Brachial

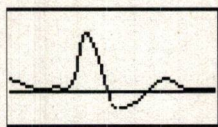
Common Femoral

Good

High Thigh

Low Thigh

Popliteal

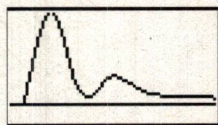


Good

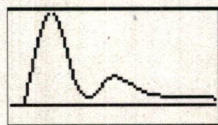
Good

High Calf

Peroneal




Good



Good

Anterior Tibial



Slightly Reduced

Posterior Tibial

Dorsalis Pedis

Good

Toe Pressure

98

0.65

Reduced

51

0.34

Post Exercise

Notes

BILATERAL LOWER LIMB ARTERIAL DUPLEX SCAN

AORTA: Normal, uniform calibre, maximum dimensions TS-1.8cm, LS-1.8cm. Mild disease, good triphasic waveforms, PSV 99cm/s.

RIGHT

CIA: Mild disease, good triphasic waveforms, PSV 101cm/s.

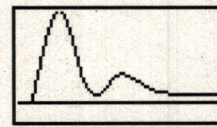
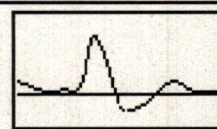
EIA: Mild disease, good triphasic waveforms, PSV 94-189cm/s.

Assessed by Jack Wilson

Printed on 16/11/2021 at 12:51 pm

Checked by

Left



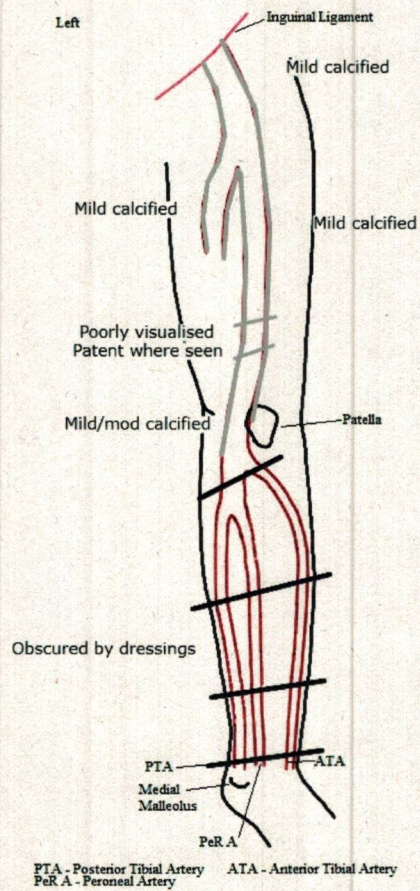
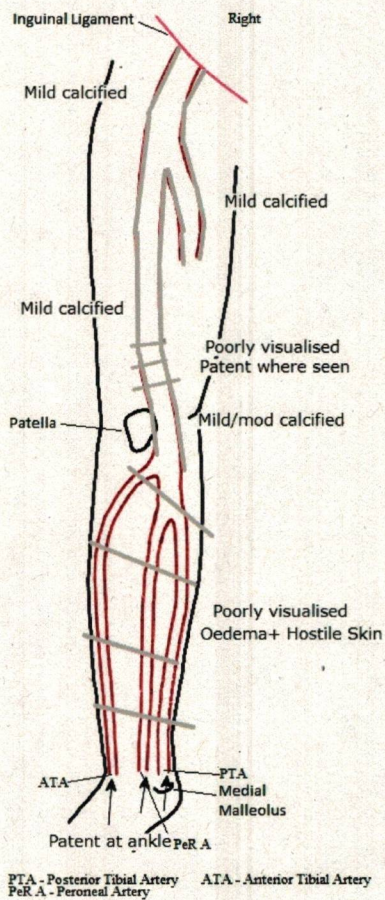
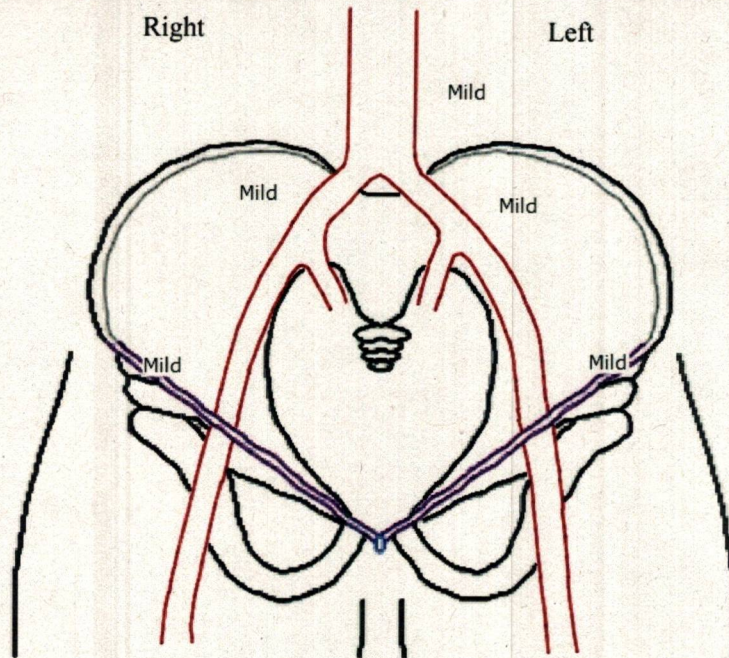
CFA: Mild calcified disease, good triphasic waveforms, PSV 20cm/s.
PFA: Mild disease, good triphasic waveforms, PSV 116cm/s.
SFA: Mild disease in the proximal to mid vessel, good triphasic waveforms, PSV 102-109cm/s. Distal vessel was poorly visualised due to poor tissue resolution, good triphasic waveforms where seen, PSV 90cm/s.
POPA: Mild/mod calcified disease along length with good triphasic waveforms, PSV 75-137cm/s. Unable to sufficiently visualise TPT due to oedema and poor tissue resolution. ?Full patency.
ATA: Poorly visualised along length due to oedema and hostile skin. Good hyperaemic waveforms at ankle, PSV 109cm/s.
PTA: Poorly visualised along length due to oedema and hostile skin. Slightly reduced mono/triphasic waveforms at ankle, PSV 50cm/s.
PerA: Poorly visualised along length due to oedema and hostile skin. Good hyperaemic waveforms at ankle, PSV 90cm/s.

LEFT:

CIA: Mild disease, good triphasic waveforms, PSV 99cm/s.
EIA: Mild disease, good triphasic waveforms, PSV 99cm/s.

CFA: Mild calcified disease, good triphasic waveforms, PSV 20cm/s.
PFA: Mild calcified disease, good triphasic waveforms, PSV 20cm/s.
SFA: Mild disease in the proximal to mid vessel, good hyperaemic waveforms, PSV 135-167cm/s. Distal vessel was poorly visualised due to poor tissue resolution, good hyperaemic waveforms where seen, PSV 90cm/s.
POPA: Mild/mod calcified disease with good hyperaemic waveforms, PSV 188-220cm/s. Unable to sufficiently visualise TPT due to oedema and poor tissue resolution. ?Full patency.
ATA: Obscured by dressings.
PTA: Obscured by dressings.
PerA: Obscured by dressings.
Dorsalis Pedis: Reduced monophasic waveforms identified using handheld doppler.

TBPI: The right resting TBPI is within normal limits. The left resting TBPI was difficult to obtain due to patient involuntary movement ?Reliability, however appears reduced at rest. ?Significant left calf vessel disease.



Assessed by Jack Wilson

Printed on 16/11/2021 at 12:52 pm

Checked by

Reason

Claudication

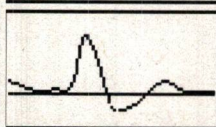
Outcome

Occlusion, Stenosis Moderate, Significant disease indicated

Right

140

1.00



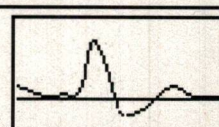
Good

Brachial

Common Femoral

Good

Left



High Thigh

Low Thigh

Popliteal

Reduced

High Calf

Peroneal

Weak

Anterior Tibial

Weak

Posterior Tibial

Weak

Dorsalis Pedis

Toe Pressure

Post Exercise

Reduced

Reduced

Reduced

88

0.63

Reduced

Notes

BILATERAL LOWER LIMB ARTERIAL DUPLEX SCAN

AORTA: Normal, uniform calibre with maximum dimensions TS-1.2cm, LS-1.2cm. Mild disease, good triphasic waveforms, PSV 70cm/s.

RIGHT

CIA: Obscured by bowel gas.

EIA: Mild/moderate disease with good triphasic waveforms, PSV 114-125cm/s.

Assessed by

Jack Wilson

Printed on 16/11/2021 at 12:53 pm

Checked by

CFA: Mild/moderate disease with good triphasic waveforms, PSV 100cm/s.

PFA: Mild disease, good triphasic waveforms, PSV 100cm/s.

SFA: Moderate disease with damped monophasic waveforms, PSV 33cm/s. Vessel occludes in the proximal thigh (68cm prox to MM). Flow reforms in the mid/distal thigh (53cm prox to MM) via a collateral with reduced monophasic waveforms, PSV 34cm/s.

POPA: Mild/mod disease along length with reduced monophasic waveforms, PSV 25-40cm/s. TPT appears patent with 3 vessel run off identified.

ATA: Mild disease along length with reduced monophasic waveforms at ankle, PSV 27-37cm/s.

PTA: Mild/mod disease in the proximal vessel. Mid vessel appears occluded. Flow reforms at the ankle with reduced monophasic waveforms, PSV 17cm/s.

PerA: Mild disease along length with reduced monophasic waveforms at ankle, PSV 20cm/s.

LEFT

CIA: Mild/moderate disease with good triphasic waveforms, PSV 130cm/s.

EIA: Mild/moderate disease with good triphasic waveforms, PSV 136-147cm/s.

CFA: Mild/moderate disease with good triphasic waveforms, PSV 179cm/s.

PFA: Mild disease with good triphasic waveforms, PSV 100cm/s.

SFA: Mild/moderate disease in the proximal vessel with good biphasic waveforms, PSV 55cm/s. Moderate stenosis identified in the proximal vessel (63cm prox to MM) with velocities increasing from 53-103cm/s.

Stenosis length ~1.04cm. Mild/moderate disease in the mid vessel with slightly reduced mono/triphasic waveforms, PSV 49cm/s. Moderate stenosis identified in the distal vessel (49cm prox to MM) with velocities increasing from 42-86cm/s. Vessel then occludes in the distal thigh (47cm prox to MM).

POPA: Proximal popliteal artery appears occluded. Flow reforms in the proximal/mid vessel (42cm prox to MM) with reduced monophasic waveforms, PSV 23-41cm/s. Moderate/severe diffuse disease identified in the TPT.

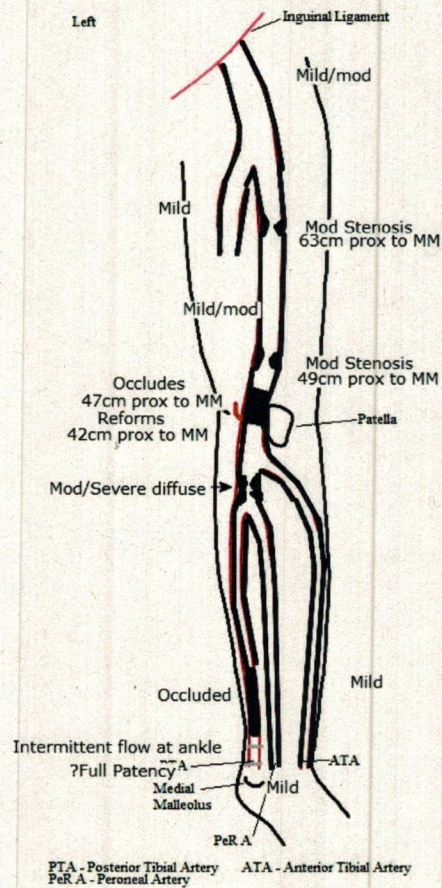
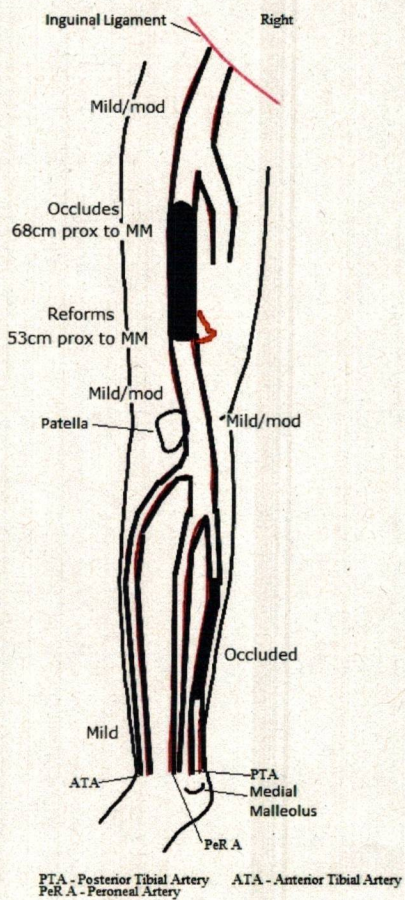
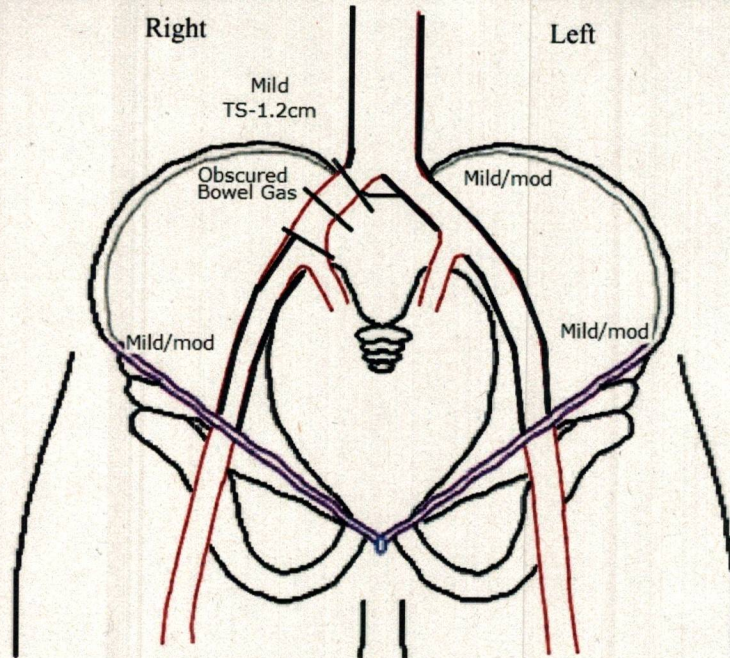
ATA: Mild disease along length with weak monophasic waveforms at ankle, PSV 28-34cm/s.

PTA: Mild disease in the proximal to mid vessel with reduced monophasic waveforms, PSV 20cm/s.

Mid/Distal vessel appears occluded. Intermittent flow at the ankle with weak monophasic waveforms, PSV 12cm/s.

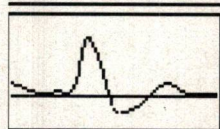
PerA: Mild disease along length with weak monophasic waveforms at ankle, PSV 17cm/s.

ABPI: The right and left resting ABPIs are reduced.

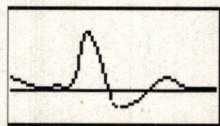


Reason Graft vein fem-pop
Outcome disease moderate, Graft widely patent

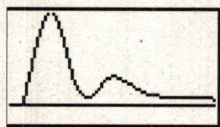
Right



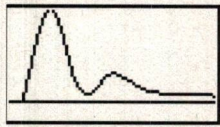
Good



Good



Good



Good

Brachial

Common Femoral

High Thigh

Low Thigh

Popliteal

High Calf

Peroneal

Anterior Tibial

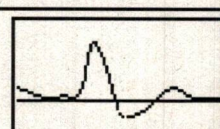
Posterior Tibial

Dorsalis Pedis

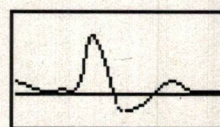
Toe Pressure

Post Exercise

Left



Good



Good

Notes

RIGHT LOWER LIMB ARTERIAL DUPLEX (FEM-POP GRAFT SURVEILLANCE)

RIGHT

CFA: Moderate calcified disease with good triphasic waveforms, PSV 137cm/s.

PFA: Mild disease with good biphasic waveforms, PSV 83cm/s.

SFA(PROX): Mild disease with good biphasic waveforms, PSV 48cm/s.

FEM-POP GRAFT

Assessed by Jack Wilson

Printed on 16/11/2021 at 12:55 pm

Checked by

PROX ANAST (PROX SFA): Widely patent, good biphasic waveforms, PSV 124cm/s.
GRAFT BODY: Widely patent, good triphasic waveforms, PSV 104-125cm/s.
DISTAL ANAST (DIST SFA): Widely patent, good triphasic waveforms, PSV 168cm/s.

SFA(DISTAL): Mild disease with good triphasic waveforms, PSV 124cm/s.

POPA: Mild disease with good bi/triphasic waveforms, PSV 70-72cm/s.

ATA: Patent at ankle with good mono/triphasic waveforms, PSV 136cm/s.

PTA: Appears occluded at ankle.

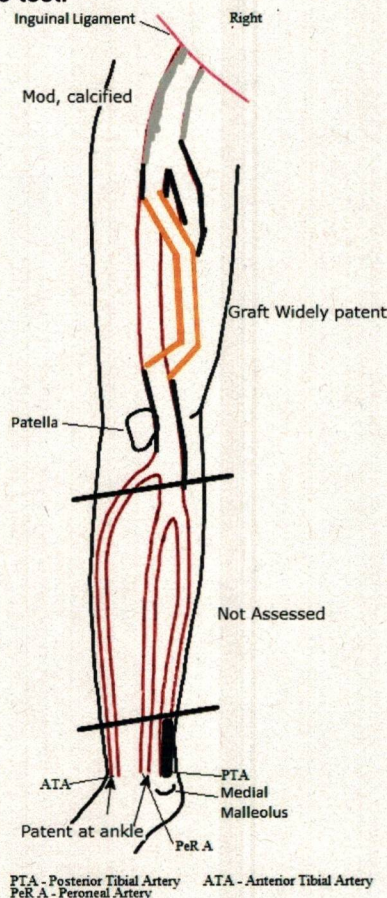
PERA: Patent at ankle with good mono/triphasic waveforms, PSV 112cm/s.

LEFT

CFA: Good triphasic waveforms, PSV 174cm/s.

ATA: Good triphasic waveforms at ankle, PSV 134cm/s.

ABPI: The right and left resting ABPIs are within normal limits and remain so after a 1 minute foot flex exercise test.



Assessed by Jack Wilson

Printed on 16/11/2021 at 12:55 pm

Checked by

Reason

Routine

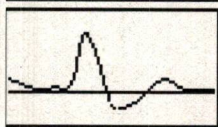
Outcome

disease mild, Bowel gas, Poor images, No significant disease indicated

Right

130

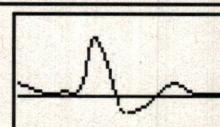
1.00



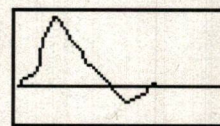
Good

Brachial**Common Femoral**

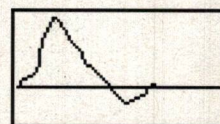
Good

Left**High Thigh****Low Thigh****Popliteal**

Good

**High Calf****Peroneal**

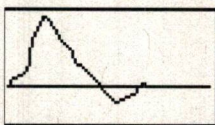
Good

**Anterior Tibial**

Good

Posterior Tibial


Good

Dorsalis Pedis**Toe Pressure****Post Exercise**

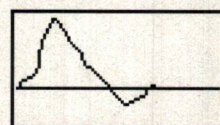
Good

128

0.98

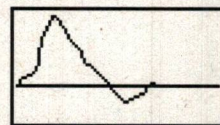


Reduced



126

0.97

**Notes****BILATERAL LOWER LIMB ARTERIAL DUPLEX SCAN**

AORTA: Obscured by bowel gas.

RIGHT

CIA: Obscured by bowel gas.

EIA: Mild disease along length with good triphasic waveforms, PSV 143-170cm/s.

Assessed by

Jack Wilson

Printed on 16/11/2021 at 12:55 pm

Checked by

CFA: Mild disease, good triphasic waveforms, PSV 188cm/s.

PFA: Mild disease, good biphasic waveforms, PSV 80cm/s.

SFA: Mild disease, good triphasic waveforms along length, PSV 132-184cm/s.

POPA: Mild disease, good triphasic waveforms, PSV 75-82cm/s.

ATA: Unable to visualise proximal to mid vessel due to oedema, mild disease in the distal vessel with good biphasic waveforms at ankle, PSV 82cm/s.

PTA: Unable to visualise proximal to distal vessel due to oedema and hostile skin, reduced biphasic waveforms at ankle, PSV 25cm/s.

PerA: Not identified due to oedema and hostile skin.

LEFT

CIA: Poorly visualised due to bowel gas, where seen appears patent with good biphasic waveforms PSV 154cm/s.

EIA: Proximal to mid vessel was obscured by bowel gas. Mild disease in the distal vessel with good triphasic waveforms, PSV 172cm/s.

CFA: Mild disease, good triphasic waveforms, PSV 165cm/s.

PFA: Mild disease, good biphasic waveforms, PSV 92cm/s.

SFA: Mild disease, good triphasic waveforms, PSV 119-188cm/s.

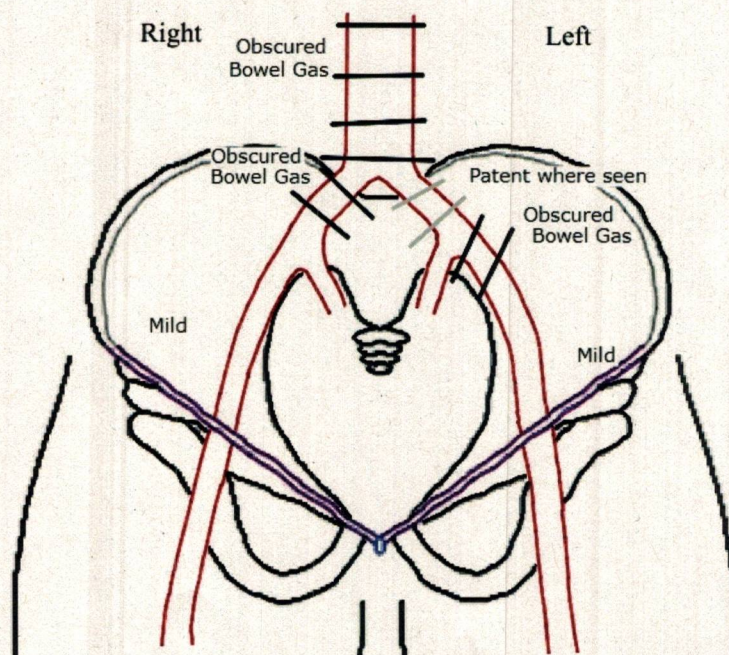
POPA: Mild disease, good biphasic waveforms, PSV 90-110cm/s.

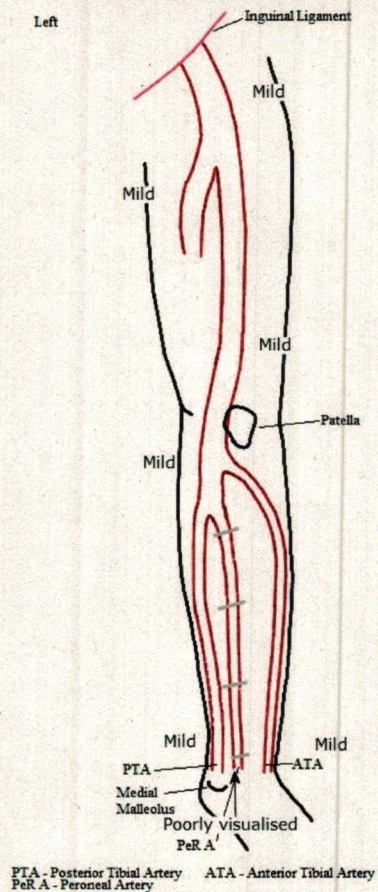
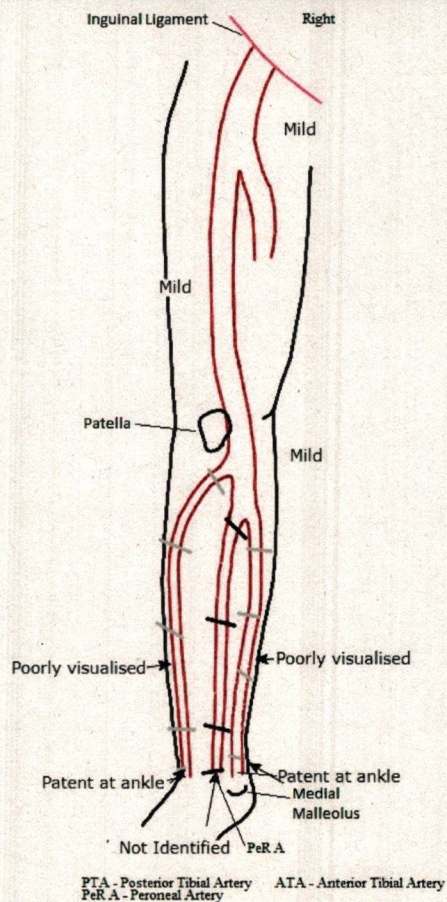
ATA: Mild disease, good biphasic waveforms at ankle PSV 143cm/s.

PTA: Mild disease, good biphasic waveforms at ankle, PSV 120cm/s.

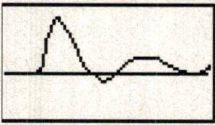
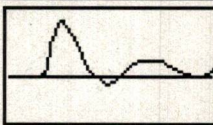
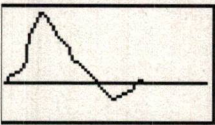
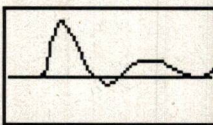
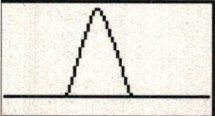
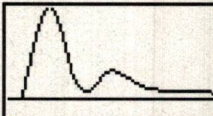
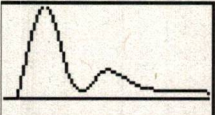
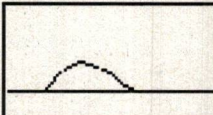
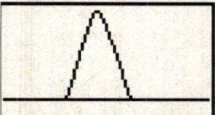
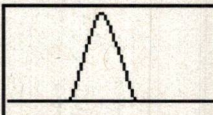
PerA: Unable to visualise proximal to distal vessel due to oedema and poor tissue resolution, patent at ankle with good biphasic waveforms, PSV 43cm/s.

ABPI: The right and left resting ABPIs are within normal limits. Patient unable to perform adequate exercise test.





Reason Claudication
 Outcome disease mild, disease moderate, Calcified, Poor images

Right				Left	
	150 1.00	Brachial			
	Good	Common Femoral	Good		
		High Thigh			
		Low Thigh			
	Good	Popliteal	Good		
		High Calf			
	Good	Peroneal	Good		
	Good	Anterior Tibial	Reduced		
	Good	Posterior Tibial	Good		
		Dorsalis Pedis			
	Good	Toe Pressure	Good		
	85 0.57		90 0.60		
		Post Exercise			

Notes

BILATERAL LOWER LIMB ARTERIAL DUPLEX SCAN

RIGHT

CFA: Mild/mod calcified disease with good triphasic waveforms, PSV 104cm/s.

PFA: Mild calcified disease with good biphasic waveforms, PSV 59cm/s.

SFA: Mild/mod calcified disease with good bi/triphasic waveforms, PSV 91-126cm/s.

POPA: Mild/mod calcified disease with good triphasic waveforms, PSV 68-81cm/s. Intermittent flow through TPT due to heavy calcification ?Full patency.

Assessed by Jack Wilson

Printed on 16/11/2021 at 12:56 pm

Checked by

ATA: Heavily calcified but patent along length with good mono/triphasic waveforms at ankle, PSV 78cm/s.
PTA: Intermittent flow along length due to heavy calcification, good monophasic waveforms at ankle, PSV 29cm/s.
PerA: Intermittent flow along length due to heavy calcification, good monophasic waveforms at ankle, PSV 31cm/s.

LEFT

CFA: Mild/mod calcified disease with good triphasic waveforms, PSV 94cm/s.
PFA: Mild/mod calcified disease with good biphasic waveforms, PSV 79cm/s.
SFA: Mild/mod calcified disease with good triphasic waveforms, PSV 58-62cm/s.
POPA: Mild/mod calcified disease with good triphasic waveforms, PSV 44-91cm/s. Intermittent flow through TPT due to heavy calcification ?Full patency.
ATA: Intermittent flow along length due to heavy calcification, good triphasic waveforms in the proximal vessel, PSV 73cm/s, reduced monophasic waveforms at ankle, PSV 15cm/s.
PTA: Intermittent flow along length due to heavy calcification, good monophasic waveforms at ankle, PSV 25cm/s.
PerA: Intermittent flow along length due to heavy calcification, good mono/triphasic waveforms at ankle, PSV 53cm/s.

TBPI: The right toe pressure is slightly reduced. The left toe pressure is within normal limits.

Right Brachial: 150mmHg

Right Toe: 85mmHg (0.57)

Left Toe: 90mmHg (0.60)

Reason Routine
Outcome disease mild, disease moderate, Calcified, Poor images

Right

154

1.00

Brachial

Common Femoral

Good

High Thigh

Low Thigh

Popliteal

Good

High Calf

Peroneal

Anterior Tibial

Good

Posterior Tibial

Slightly Reduced

Dorsalis Pedis

Toe Pressure

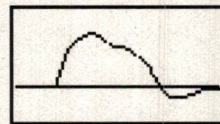
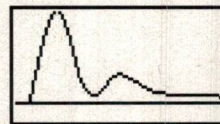
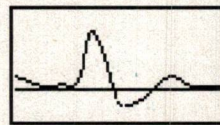
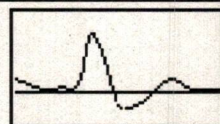
Good

113

0.73

Post Exercise

Left



Notes

LEFT LOWER LIMB ARTERIAL DUPLEX SCAN

CFA: Mild disease with good triphasic waveforms, PSV 97cm/s.

PFA: Mild disease with good triphasic waveforms, PSV 97cm/s.

SFA: Mild/moderate calcified disease with good triphasic waveforms, PSV 66-104cm/s.

POPA: Mild/moderate calcified disease with good triphasic waveforms, PSV 53-61cm/s.

ATA: Poorly visualised along length due to oedema and hostile skin, good mono/triphasic waveforms at ankle, PSV 25cm/s.

Assessed by Jack Wilson

Printed on 16/11/2021 at 12:58 pm

Checked by

PTA: Poorly visualised along length due to oedema and hostile skin, slightly reduced biphasic waveforms at ankle, PSV 12cm/s.

PerA: Not identified along length due to oedema and hostile skin.

TBPI: The left resting toe pressure is within normal limits.

Right Brachial: 154mmHg

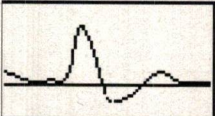
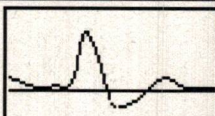
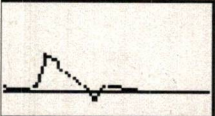
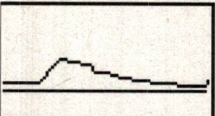
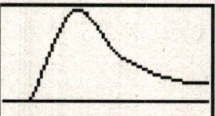
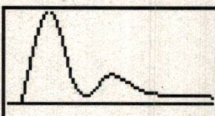
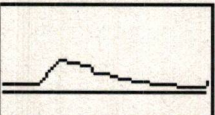
Left Toe: 113mmHg (0.73)

Assessed by Jack Wilson

Printed on 16/11/2021 at 12:58 pm

Checked by

Reason	Ulceration		
Outcome	disease mild, disease moderate, Occlusion, Calcified, Poor images, Stenosis Moderate, Stenosis Severe		

Right			Left	
	136 1.00	Brachial		
	Good	Common Femoral	Good	
		High Thigh		
		Low Thigh		
	Reduced	Popliteal		
	Reduced	High Calf		
		Peroneal		
	Slightly Reduced 144 1.06	Anterior Tibial	Good 200 1.47	
	Reduced	Posterior Tibial		
		Dorsalis Pedis		
		Toe Pressure		
	Foot Flex 80 0.59	Post Exercise	Foot Flex 210 1.54	

Notes

RIGHT LOWER LIMB ARTERIAL DUPLEX SCAN

AORTA: Normal, uniform calibre TS-1.6cm, LS-1.6cm. Mild, calcified disease with good triphasic waveforms.

RIGHT

CIA: Mild, calcified disease with good triphasic waveforms, PSV 101cm/s.

Assessed by Jack Wilson

Printed on 16/11/2021 at 12:59 pm

Checked by

EIA: Mild disease with good triphasic waveforms, PSV 84-149cm/s.

CFA: Mild/mod, calcified disease with good triphasic waveforms, PSV 101cm/s.

PFA: Mild, calcified disease with good triphasic waveforms, PSV 109cm/s.

SFA: Mild, calcified disease in the proximal vessel and mild/mod calcified disease in the mid to distal vessel with good triphasic waveforms along length, PSV 78-94cm/s.

POPA: Moderate calcified disease in the proximal vessel with good mono/triphasic waveforms, PSV 72cm/s. Moderate/severe stenosis identified in the mid vessel (44cm prox to MM) with velocities increasing from 85-219cm/s. Stenosis length ~0.59cm. Moderate calcified disease in the distal vessel with reduced mono/triphasic waveforms, PSV 73cm/s. Severe stenosis identified in the TPT (33cm prox to MM) with velocities increasing from 57-392cm/s. Stenosis length ~0.56cm. Distal TPT appears patent with 2 vessel run off identified.

ATA: Origin was very poorly visualised due to heavy calcification. Where seen, no flow identified with multiple collateral vessels noted ?Origin occluded. Proximal to distal vessel appears heavily calcified but patent with slightly reduced monophasic waveforms at ankle, PSV 78cm/s.

PTA: Proximal to mid vessel appears heavily calcified but patent with slightly reduced monophasic waveforms, PSV 38cm/s. Vessel occludes in the mid calf (20cm prox to MM). Flow reforms in the distal calf (11cm prox to MM) via a collateral with reduced monophasic waveforms at ankle, PSV 51cm/s.

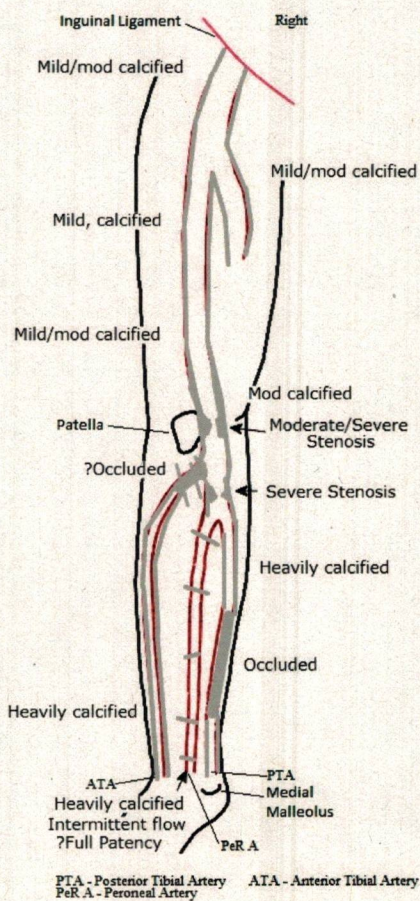
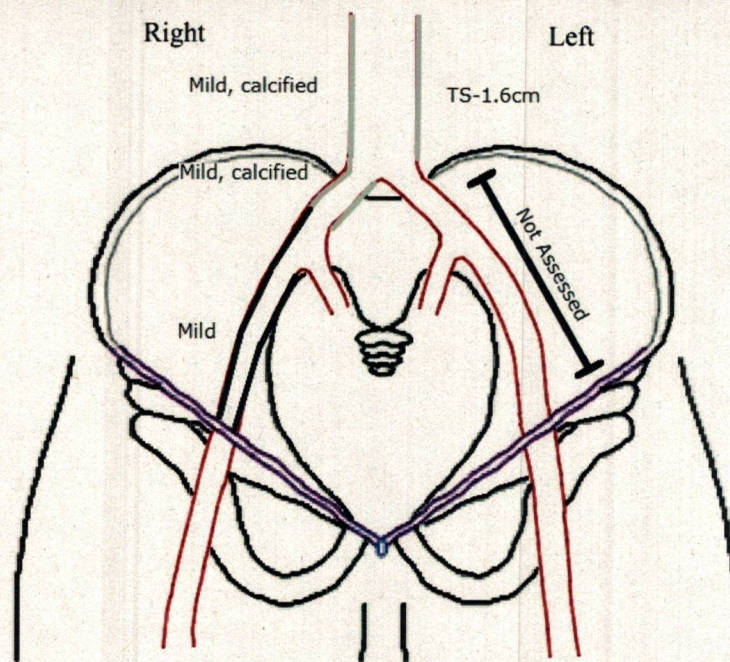
PerA: Intermittent flow along length due to heavy calcification. Patent at ankle with reduced monophasic waveforms, PSV 37cm/s.

LEFT

CFA: Good triphasic waveforms, PSV 142cm/s.

ATA: Good mono/triphasic waveforms at ankle, PSV 130cm/s.

ABPI: The right resting ABPI is within normal limits (?Falsely elevated) and becomes reduced after a 1 minute foot flex exercise test. The left resting ABPI is elevated and remains so after a 1 minute foot flex exercise test.



Assessed by Jack Wilson

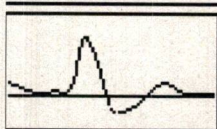
Printed on 16/11/2021 at 12:59 pm

Checked by

Reason Routine
Outcome disease mild, Occlusion, Calcified

Right

136 1.00



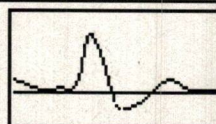
Good

Brachial

Common Femoral

Good

Left

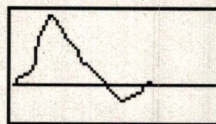


High Thigh

Low Thigh

Popliteal

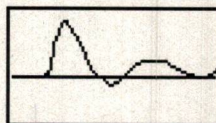
Good



High Calf

Peroneal

Good



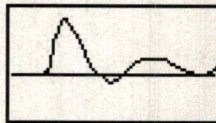
Anterior Tibial

Good (High Resistance)

Good

136 1.00

136 1.00



Posterior Tibial

Absent

Absent

Dorsalis Pedis

Toe Pressure

Post Exercise

Foot Flex

Foot Flex

128 0.94

130 0.96

Notes

BILATERAL LOWER LIMB ARTERIAL DUPLEX SCAN

AORTA: Normal uniform calibre, TS-1.5cm LS-1.5cm. Mild disease, good triphasic waveforms, PSV 111cm/s.

RIGHT

CIA: Mild disease, good triphasic waveforms, PSV 160cm/s.

EIA: Mild disease, good triphasic waveforms, PSV 101-184cm/s.

Assessed by Jack Wilson

Printed on 16/11/2021 at 12:59 pm

Checked by

CFA: Mild, calcified disease, good triphasic waveforms, PSV 100cm/s.

PFA: Mild disease, good biphasic waveforms, PSV 79cm/s.

SFA: Mild disease, good biphasic waveforms, PSV 61-125cm/s. Vessel appears patent through adductor canal.

POPA: Mild disease, good biphasic waveforms, PSV 111cm/s. TPT appears patent with 3 vessel run off identified.

ATA: Mild disease, good biphasic waveforms at ankle, PSV 106cm/s.

PTA: Mild, calcified disease in the proximal to mid vessel, good biphasic waveforms, PSV 60cm/s. Distal vessel appears occluded.

PerA: Mild disease, good biphasic waveforms at ankle, PSV 78cm/s.

LEFT

CIA: Mild disease, good triphasic waveforms, PSV 138cm/s.

EIA: Mild disease, good triphasic waveforms, PSV 129-130cm/s.

CFA: Mild disease, good triphasic waveforms, PSV 112cm/s.

PFA: Mild disease, good triphasic waveforms, PSV 52cm/s.

SFA: Mild disease, good bi/triphasic waveforms, PSV 107-134cm/s.

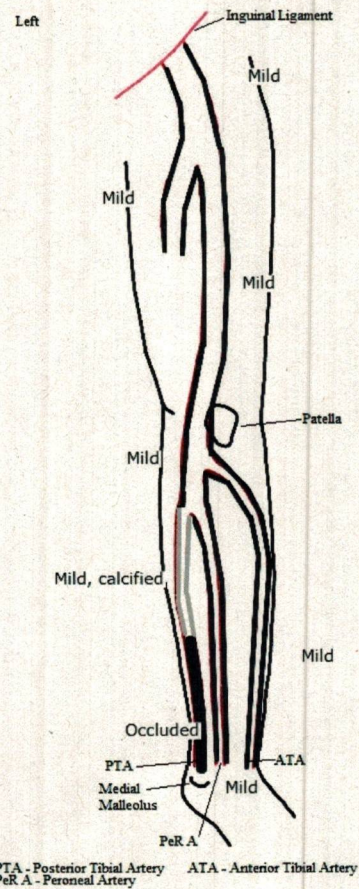
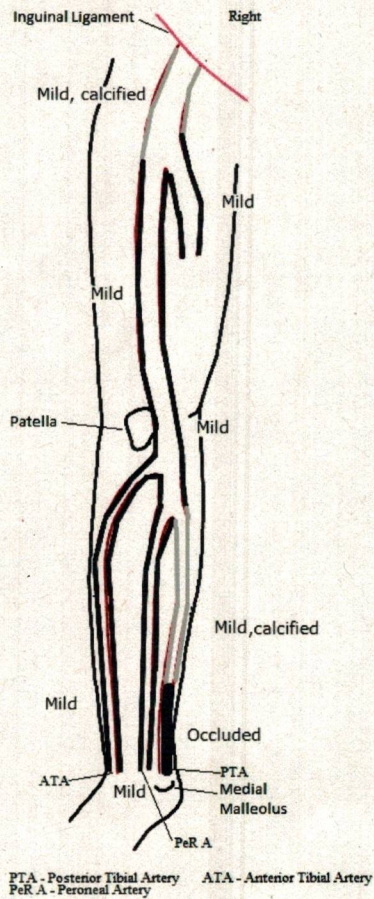
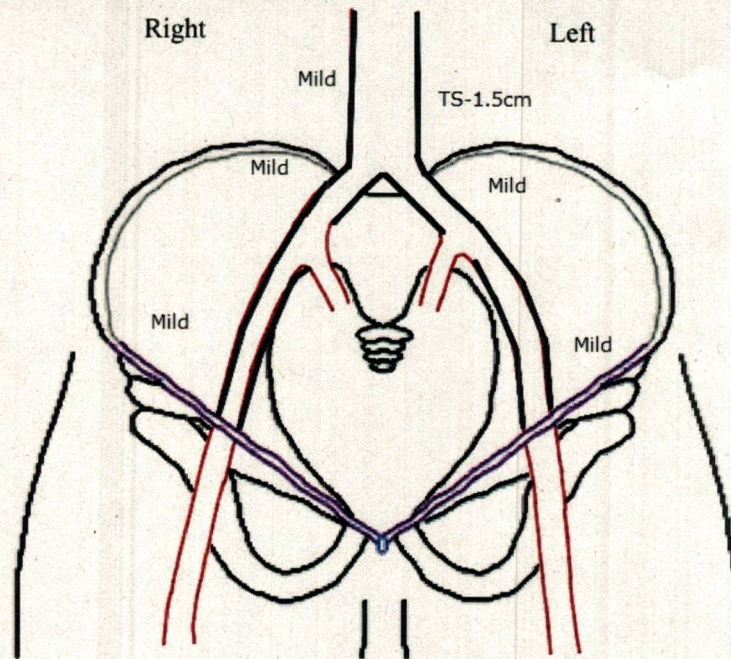
POPA: Mild disease, good biphasic waveforms, PSV 56-82cm/s. TPT appears patent with 3 vessel run off identified.

ATA: Mild disease, high resistance triphasic waveforms at ankle, PSV 150cm/s ?Distal disease.

PTA: Mild, calcified disease in the proximal vessel, good biphasic waveforms, PSV 60cm/s. Mid to distal vessel appears occluded.

PerA: Mild disease, good triphasic waveforms at ankle, PSV 94cm/s.

ABPI: The right and left resting ABPIs are within normal limits and remain so after a 1 minute foot flex exercise test.



Assessed by Jack Wilson

Printed on 16/11/2021 at 12:59 pm

Checked by