

# Ultrasonic Angiology

Patient:  
Hospital Number:  
Address:

Hospital:  
Consultant:

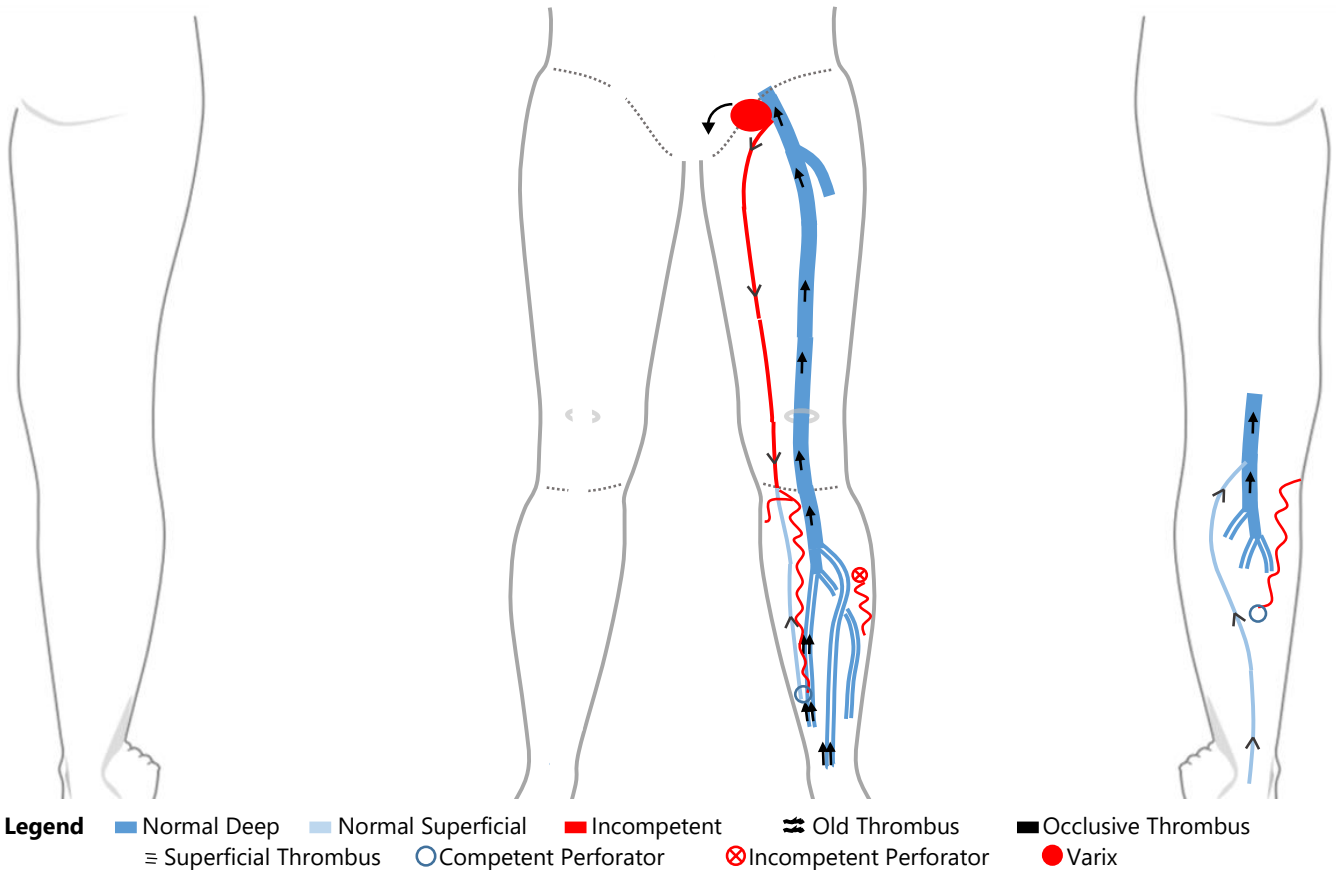
Ultrasonic Angiology Department  
2<sup>nd</sup> Floor, Borough Wing,  
Guy's Hospital, London SE1 9RT  
Tel: 0207 188 6778  
Head of Dept: Dr. TS Padayachee

## DUPLEX ASSESSMENT LOWER LIMB VENOUS

Date: 02.07.2021

Right leg:

Left leg:



### Conclusion:

#### LEFT LEG

1. Sapheno-femoral reflux. Large varix detected arising from LSV at level of SFJ. No significant change since previous assessment (patient scanned at Darent Valley on 29.06.2021). Varix dimensions 21 x 21mm, length 34mm. Prominent VV arises from LSV just BK. Medial branches drain into competent perforator vein in distal calf. Postero-medial VV branches drain into competent perforator vein at mid calf. LSV calibre 11.0mm at groin, 8.9mm at mid thigh and 7.5mm at knee.
2. Small incompetent perforator vein gives rise to lateral VV at mid calf level.
3. CFV, FV, POPV, PTVs, ATVs and SSV patent and competent.

Reported by: L. Smith  
Clinical Scientist