

Ultrasonic Angiology

Patient:
Hospital Number:
Address:

Hospital:
Consultant:

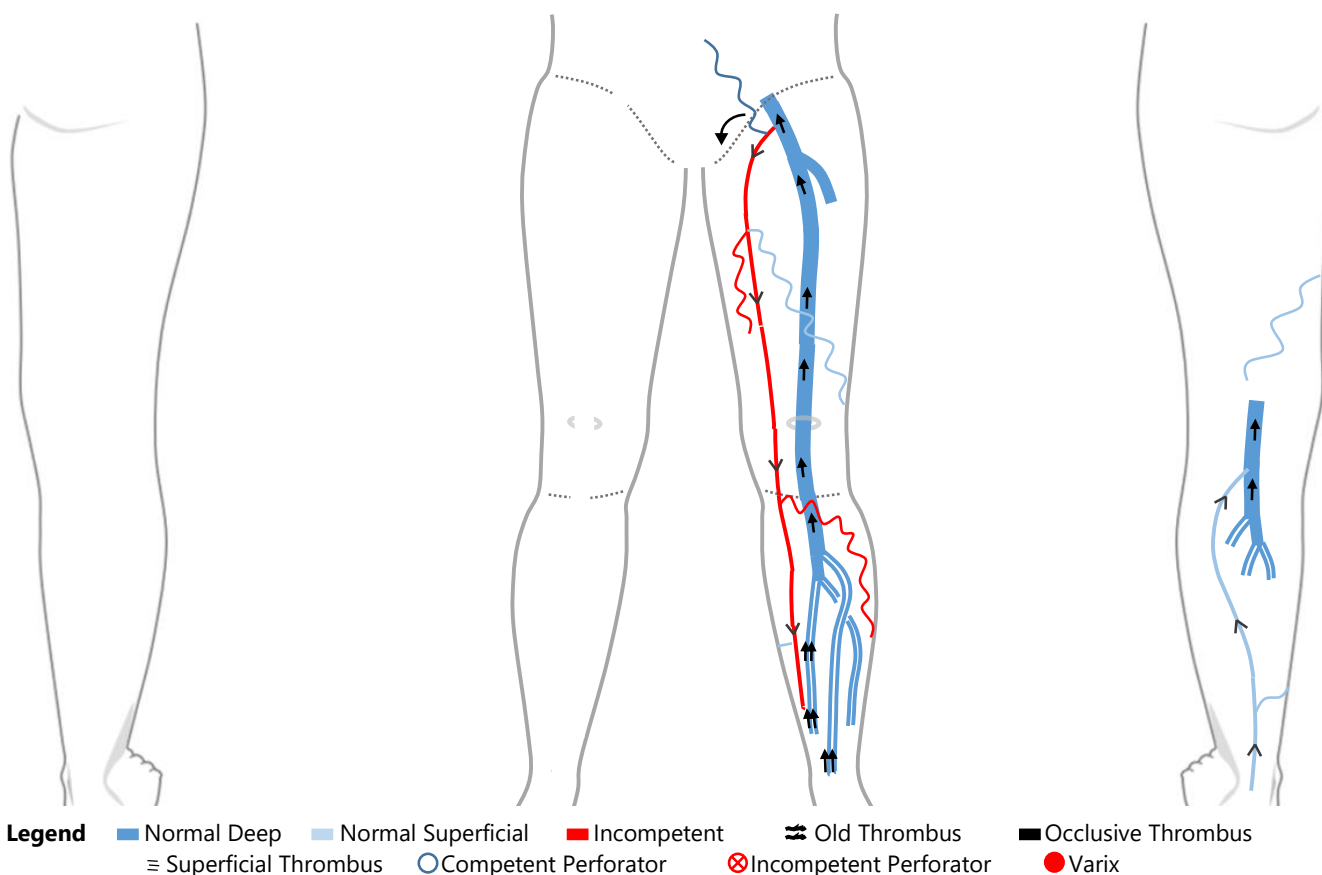
Ultrasonic Angiology Department
2nd Floor, Borough Wing,
Guy's Hospital, London SE1 9RT
Tel: 0207 188 6778
Head of Dept: Dr. TS Padayachee

DUPLEX ASSESSMENT LOWER LIMB VENOUS

Date: 05.07.2021

Right leg:

Left leg:



Conclusion:

LEFT LEG

1. Sapheno-femoral reflux. Prominent pelvic collateral veins arise from LSV just below level of SFJ. Competent postero-lateral thigh VV/collateral branch vein communicates with LSV at mid thigh. Medial VV arises from LSV at this level. Further VV arises from LSV just BK travelling to anterior aspect of knee and lateral calf. LSV calibre 7.8mm at groin, 4.8mm AK and 3.2mm BK.
2. SSV patent and competent. Branch vein arises from SSV in distal calf and communicates with LSV.
3. CFV, paired FVs, POPV, PTVs and ATVs patent and competent.

See iliac vein duplex report (05.07.2021) for assessment of (L) iliac vein stents.

Reported by: L. Smith
Clinical Scientist