

Ultrasonic Angiology

Patient:
Hospital Number:
Address:

Hospital:
Consultant:

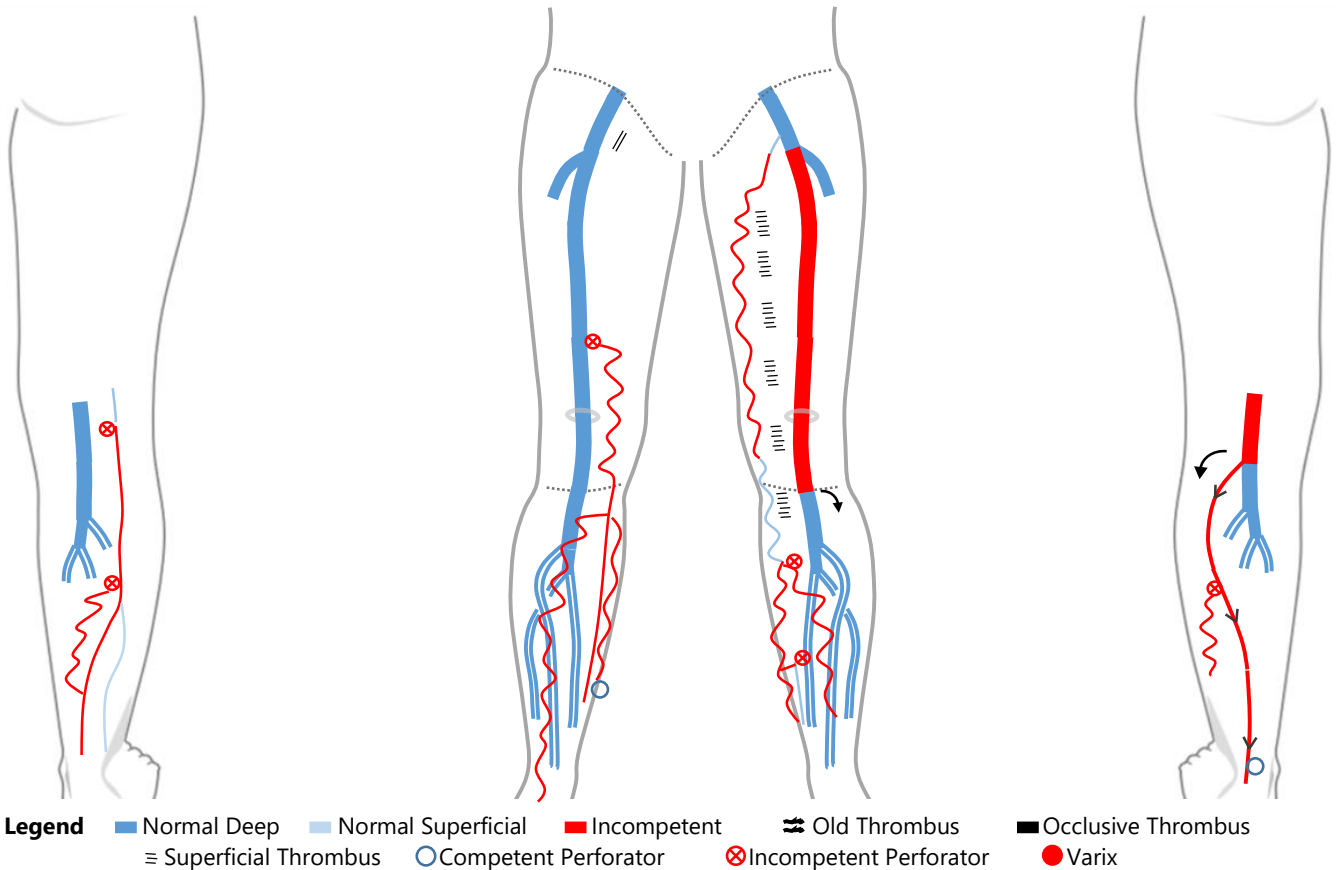
Ultrasonic Angiology Department
2nd Floor, Borough Wing,
Guy's Hospital, London SE1 9RT
Tel: 0207 188 6778
Head of Dept: Dr. TS Padayachee

DUPLEX ASSESSMENT LOWER LIMB VENOUS

Date: 09.07.2021

Right leg:

Left leg:



Legend ■ Normal Deep ■ Normal Superficial ■ Incompetent ■ Old Thrombus ■ Occlusive Thrombus
≡ Superficial Thrombus ○ Competent Perforator ⊗ Incompetent Perforator ● Varix

Conclusion:

LEFT LEG

1. ? LSV patent and competent at groin, becoming incompetent just below SFJ level. VV arises from LSV in proximal thigh. LSV not visualised below this level, ? thrombosed. VV incompetent to knee level, ? short segment of VV/branch vein competent until communication from incompetent perforator at mid calf level. Further VV branches travel medially and anteriorly at level of incompetent perforator vein. Short segment of competent LSV detected in distal calf, communicating with medial VV. Incompetent perforator vein in distal calf communicates with medial VV.
2. Sapheno-popliteal reflux. Incompetent perforator vein gives rise to posterior VVs at mid calf level and communicates with SSV. SSV communicates with competent perforator vein at ankle level. SSV calibre 7.1mm at SPJ (KSC level).
3. FV (1.5s) and POPV AK (1.9s) incompetent.
4. CFV, POPV BK, PTVs and ATVs patent and competent.

RIGHT LEG

1. LSV not visualised AK, ? previously treated. Incompetent perforator vein at mid thigh level gives rise to small calibre VV reforming incompetent LSV at knee. Anterior and medial calf VVs arise from LSV 5cm BK. Medial calf VV drains into competent perforator vein at ankle. Anterior VV travels to dorsum of foot. LSV calibre 4.4mm at knee and 2.4mm BK.
2. SSV patent and competent 10cm AK. Incompetent perforator vein/small calibre SPJ causes incompetence just below this level. Incompetent perforator vein gives rise to postero-lateral VV at mid calf and communicates with SSV. SSV paired below this level, medial duplication incompetent. VV communicates with incompetent SSV. Medial SSV calibre 3.2mm.
3. CFV, FV, POPV, PTVs and ATVs patent and competent.

Reported by: L. Smith
Clinical Scientist