

Ultrasonic Angiology

Patient:
Hospital Number:
Address:

Hospital:
Consultant:

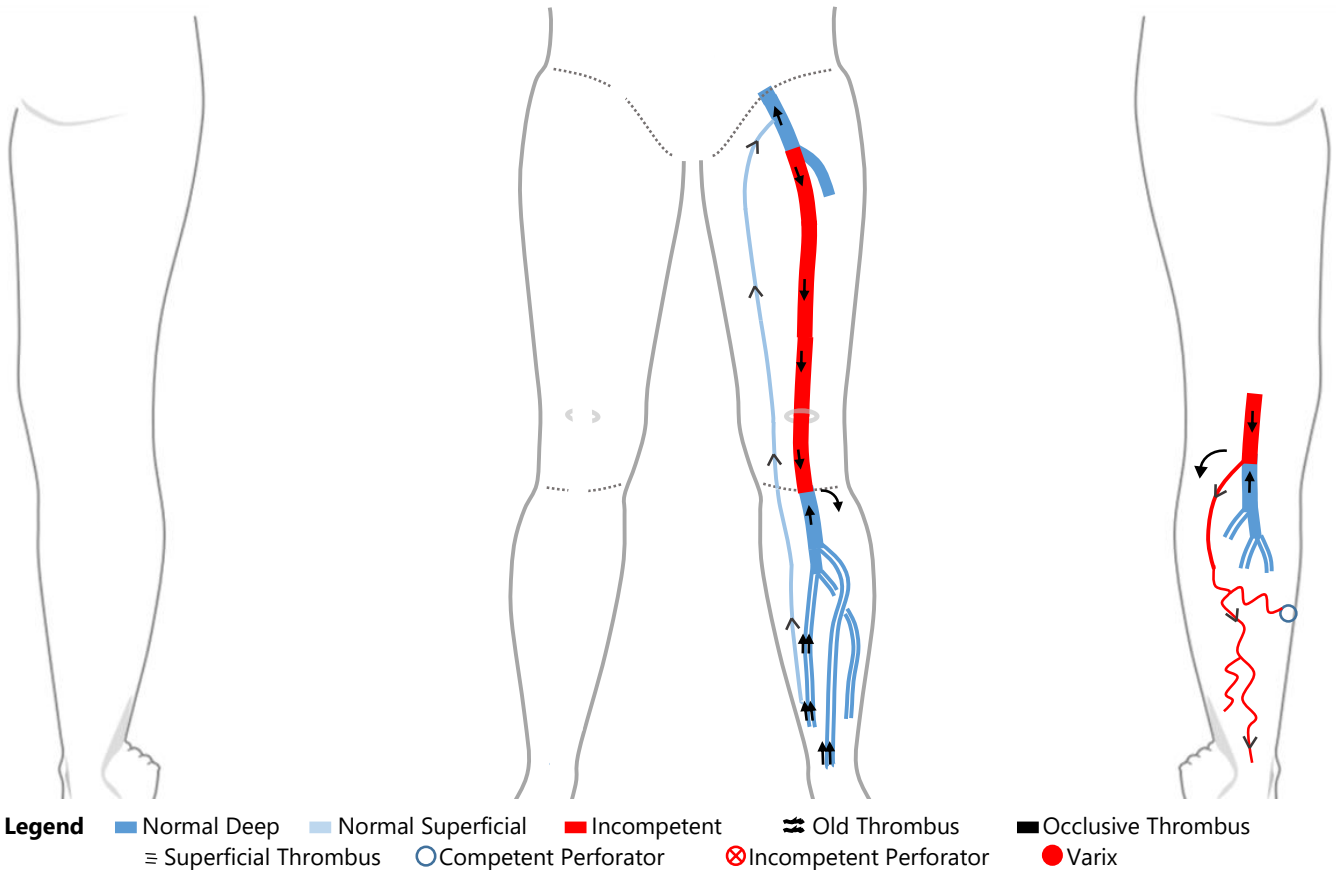
Ultrasonic Angiology Department
2nd Floor, Borough Wing,
Guy's Hospital, London SE1 9RT
Tel: 0207 188 6778
Head of Dept: Dr. TS Padayachee

DUPLEX ASSESSMENT LOWER LIMB VENOUS

Date: 13.07.2021

Right leg:

Left leg:



Conclusion:

LEFT LEG

1. FV (1.7s) and POPV AK (1.7s) incompetent.
2. Sapheno-popliteal reflux. SSV tortuous from mid calf level. VV arises from SSV at mid calf and drains into medial calf competent perforator vein. Small calibre posterior VV arises from SSV in distal calf. SSV calibre 7.2mm at SPJ at KSC, 9.6mm at mid calf and 5.8mm in distal calf.
3. PROF origin, POPV BK, PTVs, ATVs and LSV patent and competent.

See iliac vein duplex report (13.07.2021) for assessment of (L) iliac vein stents.

Reported by: L. Smith
Clinical Scientist