

Ultrasonic Angiology

Patient:
Hospital Number:
Address:

Hospital:
Consultant:

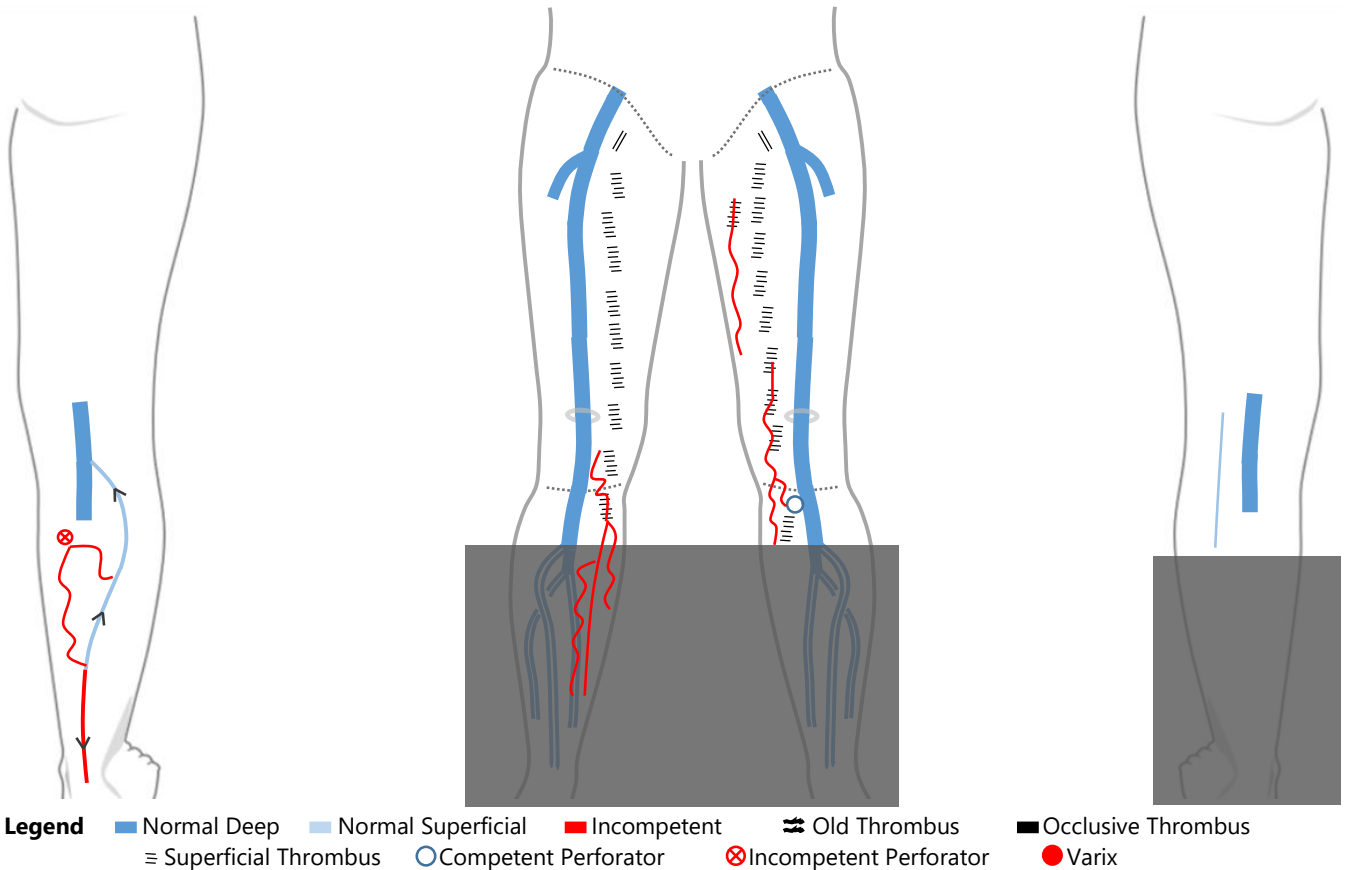
Ultrasonic Angiology Department
2nd Floor, Borough Wing,
Guy's Hospital, London SE1 9RT
Tel: 0207 188 6778
Head of Dept: Dr. TS Padayachee

DUPLEX ASSESSMENT LOWER LIMB VENOUS

Date: 07.07.2021

Right leg:

Left leg:



Conclusion:

LEFT LEG

Limited assessment, distal calf not scanned due to ulceration.

1. LSV thrombosed at SFJ post RFA. Two thrombosed veins in proximal thigh, ? paired LSVs. Medial duplication recanalises at mid thigh and becomes partially thrombosed VV. Evidence of minor recanalisation in second LSV at distal thigh level. VV arises from this level and travels to medial calf, communicating with competent perforator vein at knee.
2. CFV, FV, POPV and SSV from proximal to mid calf level patent and competent.

RIGHT LEG

1. LSV thrombosed AK post RFA. Mid thigh branch veins thrombosed. Incompetent LSV recanalises at knee and gives rise to VVs at knee level and 15cm BK. LSV calibre 3.1mm in distal calf.
2. Incompetent perforator vein gives rise to posterior VV at mid calf level. VV communicates with SSV at this level and in distal calf. SSV becomes incompetent following distal calf VV communication.
3. CFV, FV and POPV patent and competent.

Reported by: L. Smith
Clinical Scientist