

Ultrasonic Angiology

Patient:
Hospital Number:
Address:

Hospital:
Consultant:

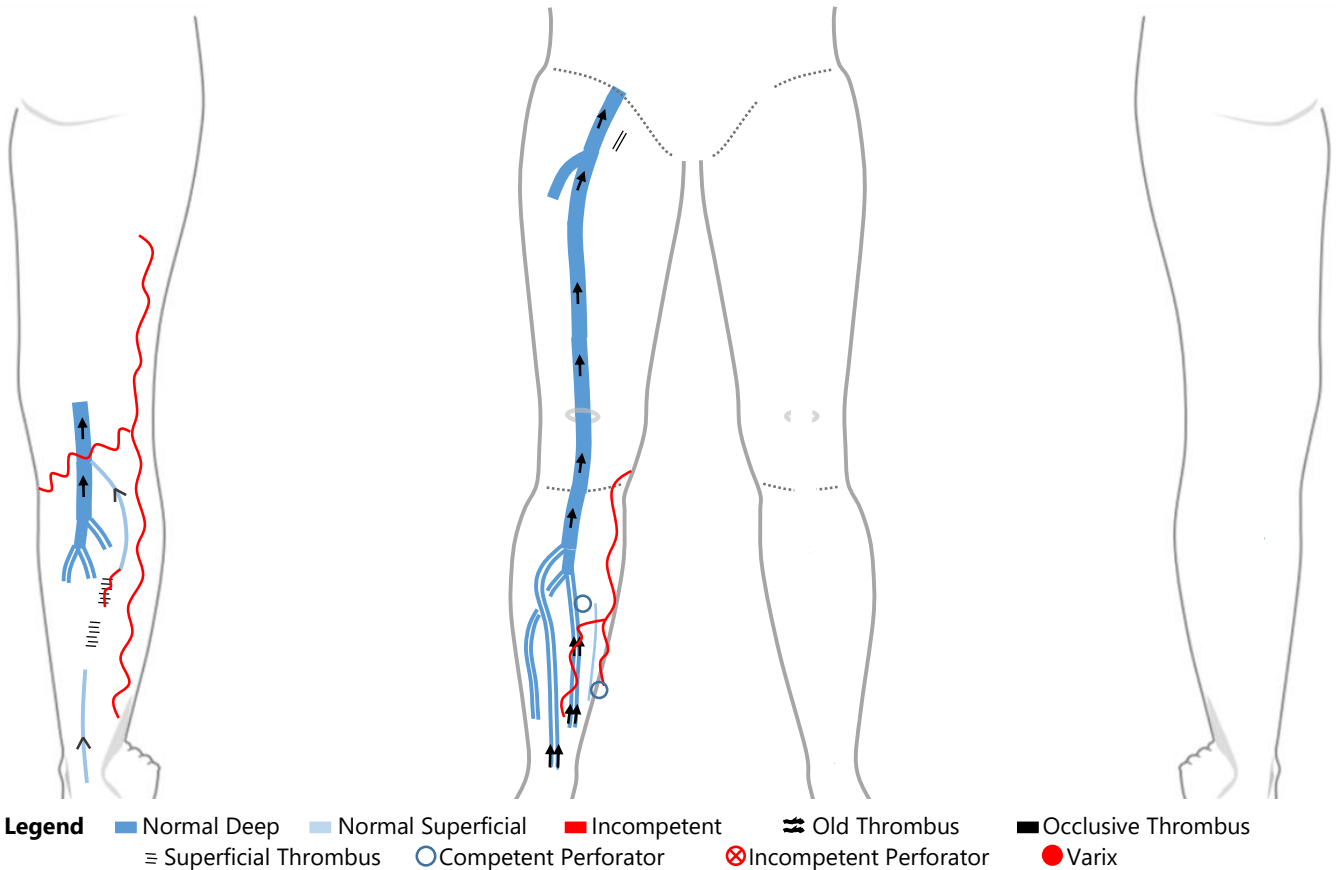
Ultrasonic Angiology Department
2nd Floor, Borough Wing,
Guy's Hospital, London SE1 9RT
Tel: 0207 188 6778
Head of Dept: Dr. TS Padayachee

DUPLEX ASSESSMENT LOWER LIMB VENOUS

Date: 19.07.2021

Right leg:

Left leg:



Conclusion:

RIGHT LEG

1. LSV not visualised AK, previously stripped. Competent LSV visualised from ankle to competent perforator vein at mid calf.
2. Postero-lateral VV arises from mid thigh travelling to knee level. Medial VV arises at this level and travels to competent perforator vein 10cm above ankle level. Antero-medial calf VV arises in distal calf. Lateral calf VV branch detected with evidence of old thrombus, ? post sclerotherapy.
3. SSV patent and competent in proximal calf. SSV thrombosed with short segment of recanalisation at mid calf, ? previously treated. SSV patent and competent in distal calf.
4. One medial gastrocnemius vein incompetent (1.7s).
5. CFV, FV, POPV, PTVs and ATVs patent and competent.

Reported by: L. Smith
Clinical Scientist