

Clinical: Finalise ☒Admin: Finalised ☐ Scribble to CRIS ☐ Shred ☐**CAROTID & VERTEBRAL DUPLEX****ULTRASONIC ANGIOLOGY DEPT.**

SCAN DATE: 10.05.21.

ID check: ☒ Y/N Consent: ☒ Y/N Chaperone: ☒ Y/N Infection Risk: ☒ Y/N History ☒

Clinical Details: Dizziness - ? cause.

Scan Site:

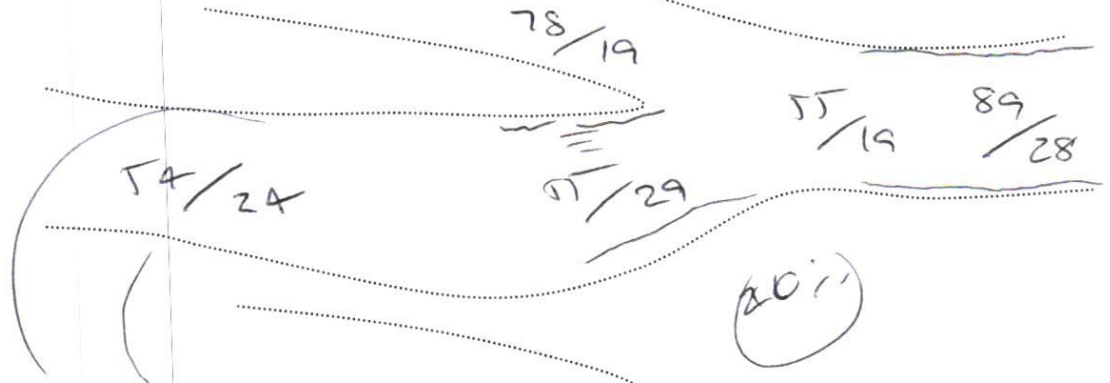
STH / GUYS

TCD:	R	L
MCA	53	40
ACA	49	33
PCA	33	23

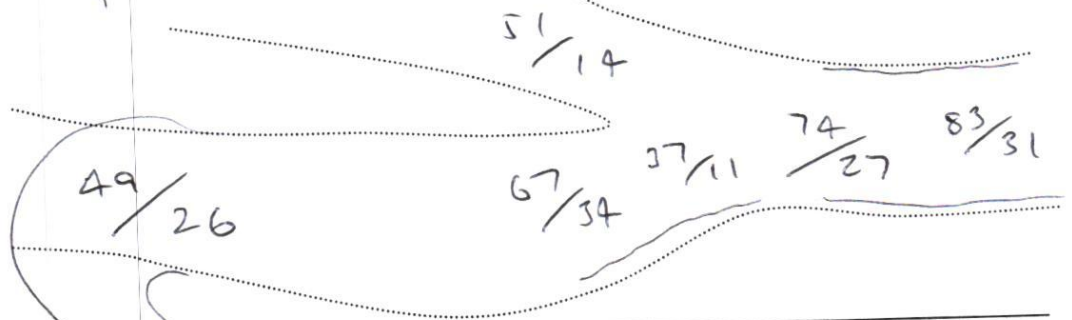
	R	L
VERTEBRAL	61	25
SUBCLAVIAN	87	75

RIGHT:ICA

DIAMETER
LENGTH

**LEFT:**ICA

DIAMETER
LENGTH

**CONCLUSION:**

Duplex ultrasound demonstrated minor fibrous plaque in the left internal carotid artery and minor fibro-calcified plaque in the right internal carotid artery. Bilateral vertebral arteries patent with antegrade flow, asymmetrical flow velocities. Bilateral subclavian arteries Dopplers within normal range.