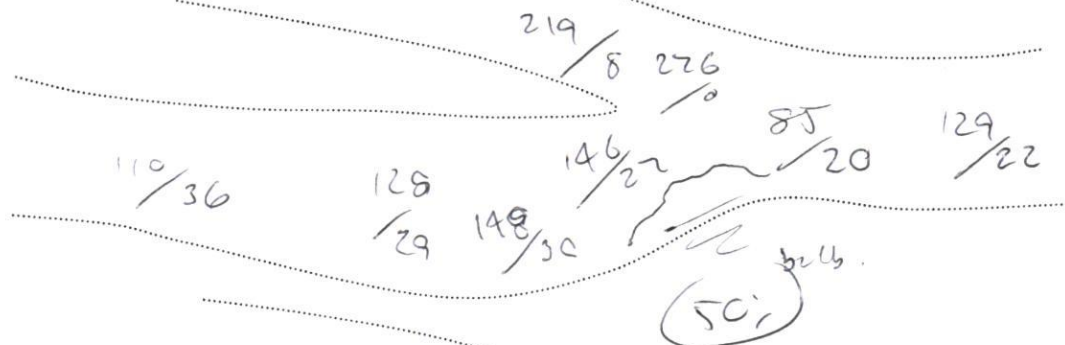
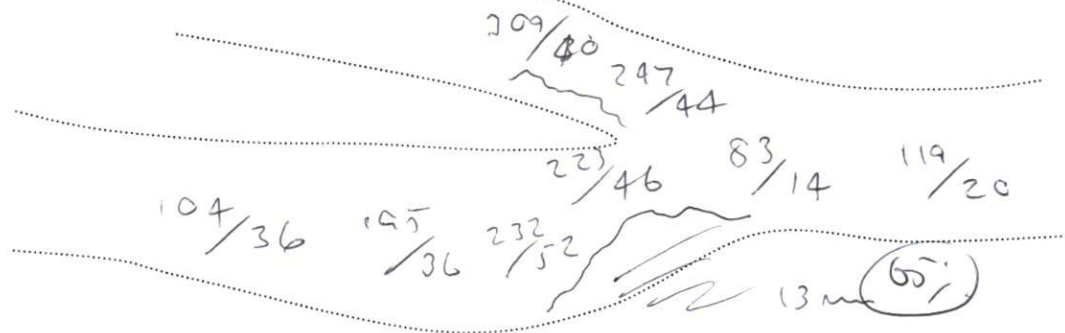


CAROTID & VERTEBRAL DUPLEX**ULTRASONIC ANGIOLOGY DEPT.****SCAN DATE:** 03.06.21ID check: Y/N Consent: Y/N Chaperone: Y/N Infection Risk: Y/N History ☐**Clinical Details:****Scan Site:****STH / GUYS**

TCD:	R	L
MCA		
ACA		
PCA		

	R	L
VERTEBRAL		
SUBCLAVIAN	233	531

RIGHT:ICA DIAMETER
LENGTH**LEFT:**ICA DIAMETER
LENGTH**CONCLUSION:**

Duplex ultrasound demonstrated irregular calcified plaque in causing moderate stenosis in the left internal carotid artery and moderate to severe stenosis in the left external carotid. Mod. calc. plaque in right bulb causes mod ICA + ECA stenosis. Partial steel in left bulb causes severe stenosis in (L) sub or on common carotid.

Right carotid occluded. Right sub - mod stenosis.