

Clinical: Finalise ☒Admin: Finalised ☐ Scribble to CRIS ☐ Shred ☐**CAROTID & VERTEBRAL DUPLEX****ULTRASONIC ANGIOLOGY DEPT.****SCAN DATE:** 10-06-21.ID check: Y/N Consent: Y/N Chaperone: Y/N Infection Risk: Y/N _____ History ☐**Clinical Details:** Bilateral peripheral vision loss, ~ 20 mins
No limb weakness.**Scan Site:**

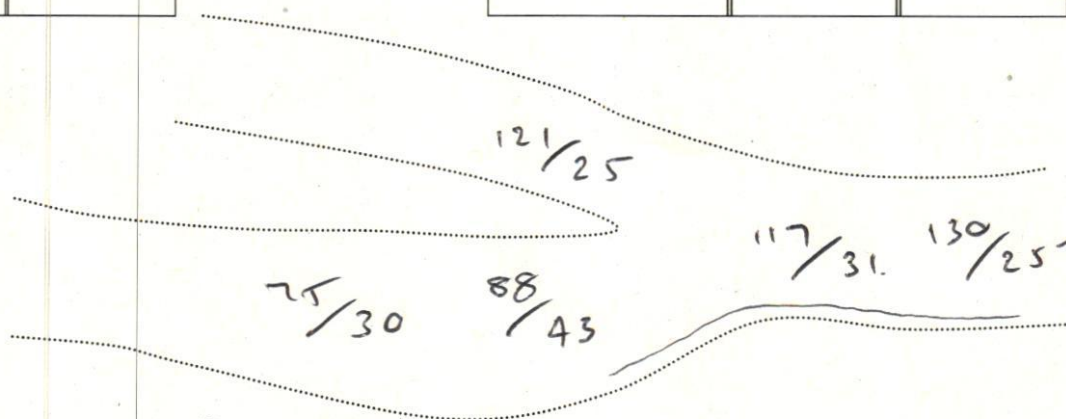
STH / GUYS

TCD:	R	L
MCA		
ACA		
PCA		


	R	L
VERTEBRAL	67 \triangle	57 \triangle
SUBCLAVIAN	152 Δ	141 Δ

RIGHT:ICA

DIAMETER
LENGTH

**LEFT:**ICA

DIAMETER
LENGTH

**CONCLUSION:**

Duplex ultrasound demonstrated minor fibrous thickening bilaterally. Vertebral and subclavian artery velocities within normal range.

1. Minor disease bilot ICAs. 16%.