

Clinical: Finalise ☒Admin: Finalised ☐ Scribble to CRIS ☐ Shred ☐**CAROTID & VERTEBRAL DUPLEX****ULTRASONIC ANGIOLOGY DEPT.**

SCAN DATE: 07/05/21

ID check: ☒ Y/NConsent: ☒ Y/N

Chaperone: Y/N

Infection Risk: Y/N \_\_\_\_\_ History ☐**Clinical Details:**

Smoker, diabetic, recent stroke + still dribbling

Scan Site:

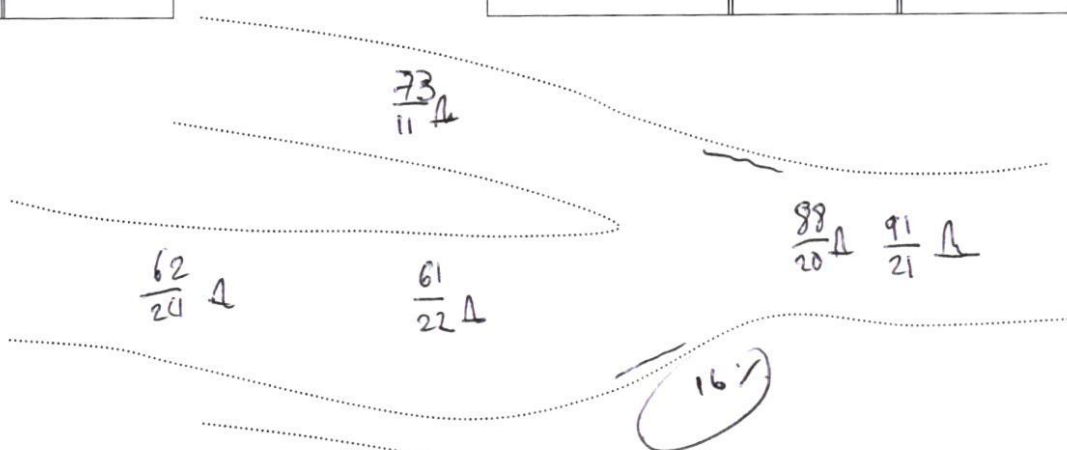
STH / GUYS

TCD:	R	L
MCA		
ACA		
PCA		

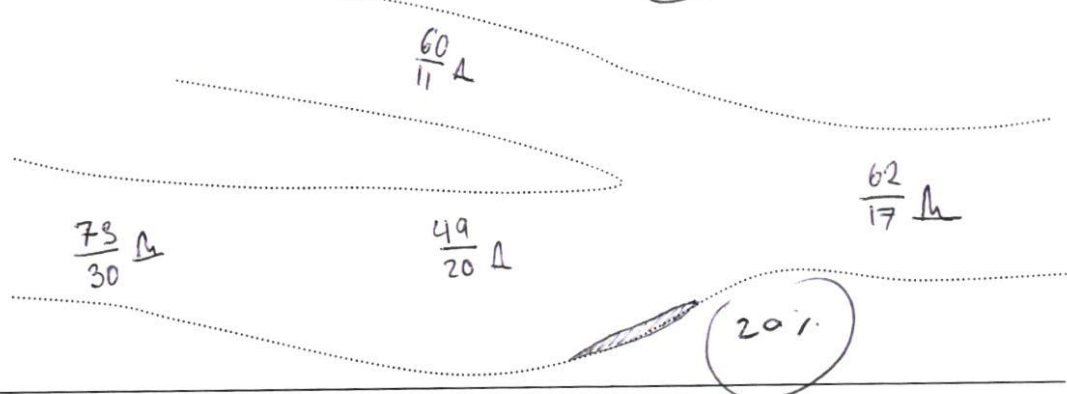
	R	L
VERTEBRAL	$\frac{59}{21}$ $\Delta$	$\frac{45}{13}$ $\Delta$
SUBCLAVIAN	166 $\Delta$	156 $\Delta$

**RIGHT:**ICA 

DIAMETER
LENGTH

**LEFT:**ICA 

DIAMETER
LENGTH

**CONCLUSION:**

Duplex ultrasound demonstrated minor fibrous plaque detected in bilateral internal carotid arteries. Vertebral and subclavian artery waveforms well within normal range.

1. Minor fibrous plaques in bilateral ICAs, 16-49%.