

Clinical: Finalise ☒Admin: Finalised ☐ Scribble to CRIS ☐ Shred ☐**CAROTID & VERTEBRAL DUPLEX****ULTRASONIC ANGIOLOGY DEPT.**

SCAN DATE: 09.06.21

ID check: Y/N Consent: Y/N Chaperone: Y/N Infection Risk: Y/N History ☐

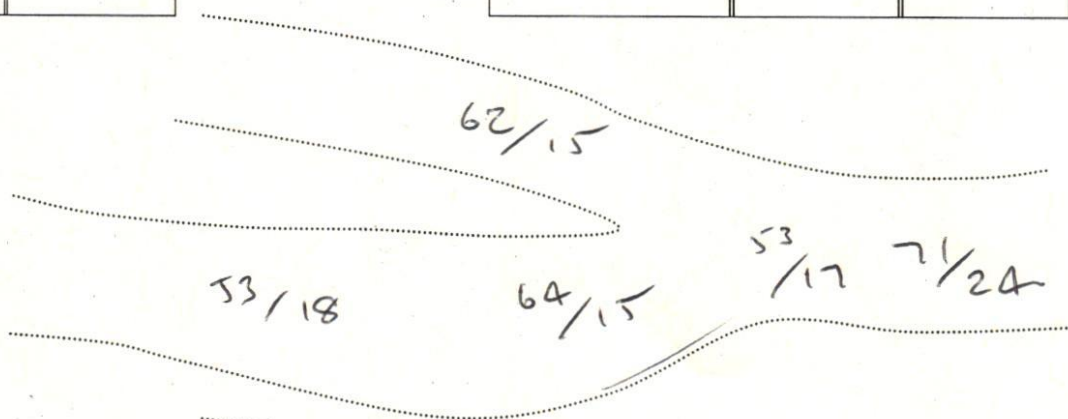
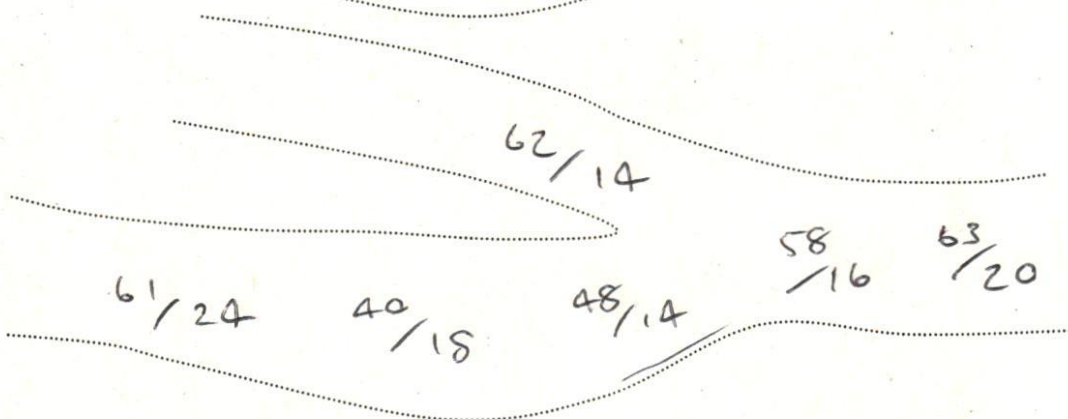
Clinical Details: (L) limb weakness, now resolved

Scan Site:

STH / GUYS

TCD:	R	L
MCA		
ACA		
PCA		

	R	L
VERTEBRAL	26 $\Delta$	34 $\Delta$
SUBCLAVIAN	101 $\Delta$	72 $\Delta$

**RIGHT:**ICA DIAMETER  
LENGTH**LEFT:**ICA DIAMETER  
LENGTH**CONCLUSION:**

Duplex ultrasound demonstrated minor fibrous thickening in bilateral internal carotid arteries. vertebral and subclavian artery waveforms were within normal range.

∴ minor disease in bilateral ICAs, 1-15%.