

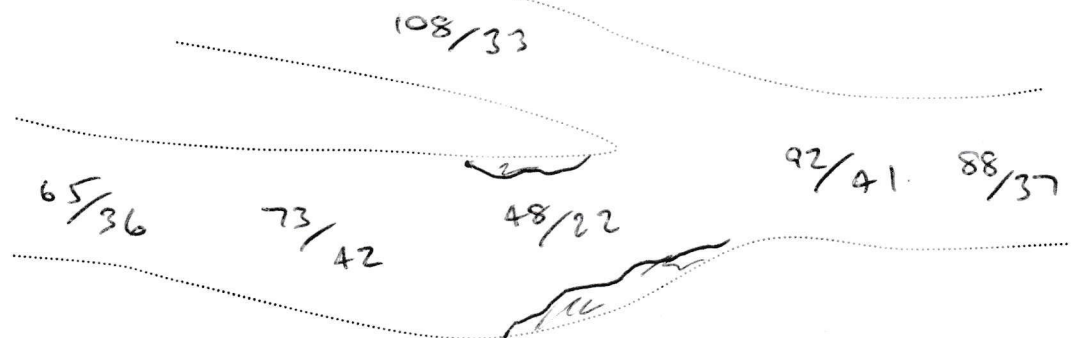
CAROTID & VERTEBRAL DUPLEX**ULTRASONIC ANGIOLOGY DEPT.**

SCAN DATE: 15.07.21.

ID check: ☒ Y/N Consent: ☒ Y/N Chaperone: ☒ Y/N Infection Risk: Y/O History: ☒
 Clinical Details: Dizziness and blurred vision. Episodes of double vision. Parasthesia on left side with weakness.
 Scan Site: **STH/ GUYS**

TCD:	R	L
MCA		
ACA		
PCA		

	R	L
VERTEBRAL	Δ 32	Δ 27
SUBCLAVIAN	Δ 83	Δ 102

RIGHT:ICA DIAMETER
LENGTH**LEFT:**ICA DIAMETER
LENGTH**CONCLUSION:**

Duplex ultrasound demonstrated minor mixed echo, irregular plaque in bilateral internal carotid arteries. Vertebral and subclavian artery waveforms were within normal range.

1. Minor irregular, mixed echo plaques detected in bilateral ICAs, 16-49% (near 20%).