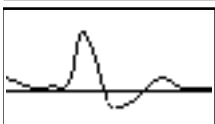




Reason Claudication
Outcome Stenosis mild, Occlusion

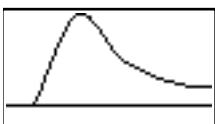
Right



Good



Absent



Slightly Reduced

Brachial

Common Femoral

High Thigh

Low Thigh

Popliteal

High Calf

Peroneal

Anterior Tibial

Posterior Tibial

Dorsalis Pedis

Toe Pressure

Post Exercise

Left

Notes

RIGHT LOWER LIMB ARTERIAL DUPLEX

EIA, CFA, PFA origin - patent with mild disease, good bi/triphasic waveforms, PSV 181-75cm/s.
SFA - mild stenosis identified in the mid thigh SFA, velocities increase from PSV 65 to 138cm/s.
Pop A - mid to distal vessel is occluded with mixed echogenic material ?thrombus.
TPT - appears occluded with mixed echogenic material ?thrombus
ATA - patent along length, slightly reduced monophasic waveforms at the ankle.
PTA - appears occluded along its length.

Assessed by Sharifa Kiyegga

Printed on 16/12/2019 at 3:13 am

Checked by

Pero A - no colour flow noted along its length ?occluded.

Right resting not performed due to ?acute nature of disease.

