

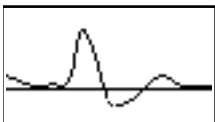


**Reason** Claudication  
**Outcome** Stenosis moderate, Stenosis severe, Occlusion

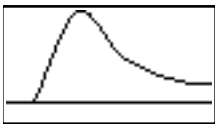
## Right

140

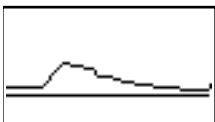
1.00



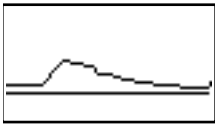
Good



Slightly Reduced



Reduced



Reduced

120

0.86

**Brachial**

**Common Femoral**

**High Thigh**

**Low Thigh**

**Popliteal**

**High Calf**

**Peroneal**

**Anterior Tibial**

**Posterior Tibial**

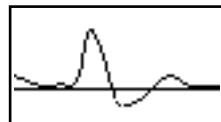
**Dorsalis Pedis**

**Toe Pressure**

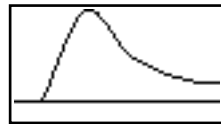**Post Exercise**

## Left

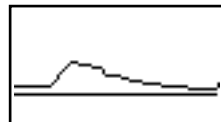Good



Slightly Reduced



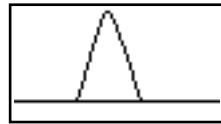Reduced



Slightly Reduced

116

0.83



**Calf Raises**

74

0.53

**Calf Raises**

62

0.44

## Notes

### BILATERAL LOWER LIMB ARTERIAL DUPLEX

#### RIGHT:

CFA - widely patent with good triphasic waveforms, PSV 239cm/s.

PFA origin - appears moderately stenosed, PSV 306cm/s.

SFA - proximal vessel appear patent with mild/ moderate disease. A 1.5cm severe stenosis identified in the mid thigh SFA at 62cm proximal to the MM. Velocities increase from PSV 41 to >600cm/s. Turbulent flow and velocity shift noted in the distal thigh SFA at 55cm proximal to the MM, velocities increase from PSV 45

Assessed by Sharifa Kiyegga

Printed on 16/12/2019 at 3:00 am

Checked by



to 127cm/s, however collateral vessel noted in this region ?cause of flow turbulence. Distal SFA is patent with slightly reduced monophasic waveforms, PSV 45cm/s.

PopA - patent with mild disease, slightly reduced monophasic waveforms, PSV 44-51cm/s.

TPT is patent. 3 run-off origins noted.

ATA and PTA - patent along length, reduce monophasic waveforms at the ankle, PSV 18-20cm/s.

#### LEFT:

CFA - widely patent with good triphasic waveforms, PSV 205cm/s.

PFA origin - appears widely patent, good triphasic waveforms, PSV 205cm/s.

SFA - vessel origin is patent with severe disease. Moderate stenosis identified in the proximal vessel with velocities increasing from PSV 59 to 158cm/s. Distal to this the SFA is patent with diffuse severe disease, to the mid thigh. Vessel then occludes in the mid thigh at 60cm proximal to the MM for 5cm, and reforms in the distal thigh at 55cm proximal to the MM. Distal vessel is patent with slightly reduced monophasic waveforms, PSV 60cm/s.

PopA - patent with mild disease, slightly reduced monophasic waveforms, PSV 38-50cm/s.

TPT is patent. 3 run-off origins noted.

ATA and PTA - patent along length, slightly/reduce monophasic waveforms at the ankle, PSV 21-31cm/s.

Bilateral resting ABPI's are within normal limits (Right - 0.86, Left - 0.83) with a significant reduction in systolic ankle pressure following a 1-minute calf raise exercise challenge.

