



Patient

D.O.B.

Reason

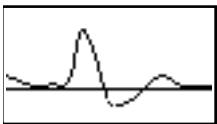
Ulceration

Outcome

Calcified

Right

Left



Good

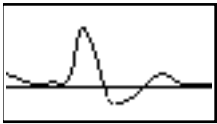
Brachial

Common Femoral

High Thigh

Low Thigh

Popliteal



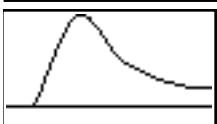
Good

High Calf

Peroneal

Anterior Tibial

Posterior Tibial



Good

Dorsalis Pedis

Toe Pressure

Post Exercise

Notes

RIGHT LOWER LIMB ARTERIAL DUPLEX

CFA, PFA origin, SFA and PopA - patent with calcified disease/ vessel walls, triphasic waveforms, PSV 75-144cm/s.

TPT is patent. 2 run-off origins noted.

ATA and PTA - unable to assesses due to wound dressings/ bandaging

Dorsalis pedis - calcified but appears patent with good monophasic waveforms, PSV 133cm/s.

Assessed by Sharifa Kiyegga

Printed on 15/12/2019 at 7:55 pm

Checked by



Right resting ABPI's not performed due wound dressing/ bandaging.

