



[Redacted]	[Redacted]	[Redacted]	[Redacted]
[Redacted]	[Redacted]	[Redacted]	[Redacted]
[Redacted]	[Redacted]	[Redacted]	[Redacted]
[Redacted]	[Redacted]	[Redacted]	[Redacted]
[Redacted]	[Redacted]	[Redacted]	[Redacted]
[Redacted]	[Redacted]	[Redacted]	[Redacted]

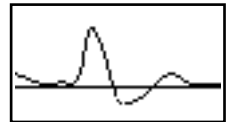
Right

Left

Brachial

Common Femoral

Good

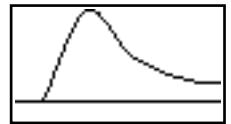


High Thigh

Low Thigh

Popliteal

Reduced



High Calf


Peroneal

Absent



Anterior Tibial

Absent



Posterior Tibial

Reduced



Dorsalis Pedis

Toe Pressure

Post Exercise

Notes

LEFT LOWER LIMB ARTERIAL DUPLEX

CFA - patent with good triphasic waveforms, PSV 130cm/s.

PFA origin - patent with turbulent flow and raised velocities, suggestive of a moderate stenosis, PSV 264cm/s.

SFA - vessel origin appears patent with good triphasic waveforms, PSV 122cm/s. Vessel occludes in the proximal thigh with echolucent material ?thrombus. Vessel remains occluded with flow reforming the below knee popliteal artery.

Assessed by Sharifa Kiyegga

Printed on 16/12/2019 at 2:40 am

Checked by



PopA - proximal vessel is occluded. Vessel reforms below knee with moderate echolucent disease ?thrombus. Reduced monophasic waveforms.

TPT is patent. 1 run-off origins noted.

ATA - appears occluded along its length.

PTA - patent along length, reduced/ weak monophasic waveforms at the ankle.

Pero A - no colour flow noted along length ?occluded.

Left resting ABPI not performed due to acute nature of disease and patient discomfort.

