

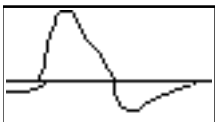


Reason Ulceration  
Outcome Stenosis moderate

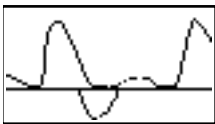## Right

154

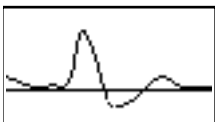
1.00



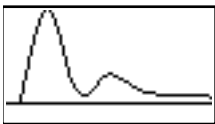
Good



Good



Good



Good

160

1.04

Brachial

Common Femoral

High Thigh

Low Thigh

Popliteal

High Calf

Peroneal

Anterior Tibial

Posterior Tibial

Dorsalis Pedis

Toe Pressure

Post Exercise

## Left

### Notes

RIGHT LOWER LIMB ARTERIAL DUPLEX

\*Fem- AK Pop bypass graft noted (10years old as per patient)

CFA - appears patent with good biphasic waveforms, PSV 147 -261cm/s.

Proximal anastomosis appears widely patent with turbulent flow, biphasic waveforms, PSV 108cm/s.

Graft - appears widely patent along its length. Turbulent flow noted in at the graft origin/ proximal segment,

Assessed by Sharifa Kiyegga

Printed on 15/12/2019 at 8:07 pm

Checked by



however good biphasic waveforms. Good bi/triphasic waveforms noted in the remaining graft, PSV 105-145cm/s.

Distal graft - widely patent with good mono/triphasic waveforms, PSV 112cm/s.

Pop A - Mild/ moderate stenosis noted in the mid vessel, velocities increase from PSV 79cm/s to PSV 213cm/s. The remaining vessel is patent with mild disease and raised velocities throughout, triphasic waveforms, PSV 125-173cm/s.

TPT - patent.

ATA - patent at the ankle, triphasic waveforms, PSV 66cm/s.

PTA - patent at the ankle with bouncy monophasic waveforms, PSV 121cm/s.

Right resting ABPI's good (1.04).

