



Reference

Accession

Patient

NHS No

D.O.B.

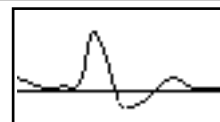
Patient Ref

Reason Graft synthetic fem-pop**Outcome** Occlusion, Calcified, Poor Images, Oedema**Right****Left**

Brachial

Common Femoral

Good



High Thigh

Low Thigh

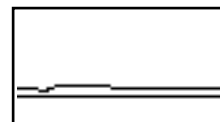
Popliteal

High Calf

Peroneal

Anterior Tibial

Weak/Absent



Posterior Tibial

Dorsalis Pedis

Toe Pressure

Post Exercise

Notes

LEFT LOWER LIMB ARTERIAL DUPLEX - SYNTHETIC FEM-POP BYPASS SURVEILLANCE.

CFA has mild disease 81cm/s triphasic.

The graft appears to be occluded throughout its length with anechoic material ?soft plaque ?thrombus.

Distal anastomosis not visualised.

No colour-flow noted in the popliteal artery and TPT ?patency.

ATA some poor, weak, venous-like monophasic flow noted at the ankle, PSV 9cm/s.

PTA is too heavily calcified to determine patency.

Assessed by Lukasz Koprowski

Printed on 08/06/2019 at 11:52 am

Checked by



Reference

Accession

Patient

NHS No

D.O.B.

Patient Ref

Pressure not assessed at this time due to patients pain and feeling very unwell.

INCIDENTAL FINDING: a mixed echogenic, avascular mass noted in the left groin, measuring ~1.8 cm ML x ~1.1 cm TS ?lymph node.

