



Reference

Accession

Patient

NHS No

D.O.B.

Patient Ref

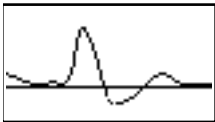
Reason Graft vein fem-pop

Outcome disease mild

Right

120

1.00



Good

Brachial

Left

Common Femoral

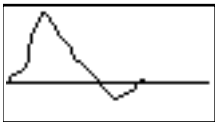
High Thigh

Low Thigh

Popliteal

High Calf

Peroneal



Good

120

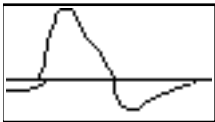
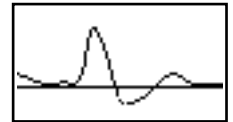
1.00

Anterior Tibial

Good

140

1.17



Slightly Reduced

Posterior Tibial

Dorsalis Pedis

Toe Pressure

Post Exercise

Notes

RIGHT FEM-POP VEIN GRAFT SURVEILLANCE ASSESSMENT

Irregular heart rate noted.

CFA - Patent, slightly turbulent triphasic waveforms, PSV 207cm/s.

Proximal graft anastomosis - Patent with good triphasic waveforms, PSV 144cm/s.

Body of graft - A focal (~0.4cm) mild-moderate disease noted just distal to the graft origin. Velocities increase to 290cm/s (turbulent triphasic), decreasing to 126cm/s (biphasic), distal to the disease.

Remainder of the graft appears patent, good biphasic waveforms and PSV 107-126cm/s.

Distal graft anastomosis (mid-distal POPA) - widely patent, good biphasic waveforms, PSV 121cm/s.

Assessed by Lukasz Koprowski

Printed on 08/06/2019 at 4:47 pm

Checked by



Reference

Accession

Patient

NHS No

D.O.B.

Patient Ref

Native distal POPA - Mild dense and calcified disease, good biphasic waveforms, PSV 72cm/s. TPT is patent; origins of two vessel run-off identified.

PTA - severely calcified with intermittent flow and slightly reduced biphasic waveforms PSV 51cm/s.

ATA - calcified with good biphasic waveforms PSV 69cm/s.

Bilateral, resting ABPIs are within normal limits; patient could not complete exercise challenge.

