



Reference

Accession

Patient

NHS No

D.O.B.

Patient Ref

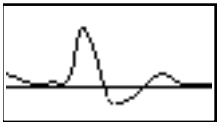
Reason Claudication

Outcome Occlusion

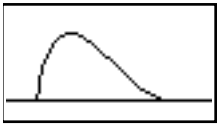
Right

90

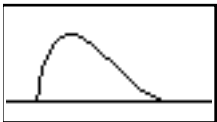
1.00



Good



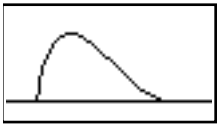
Reduced



Reduced

80

0.89



Reduced

Brachial

Common Femoral

High Thigh

Low Thigh

Popliteal

High Calf

Peroneal

Anterior Tibial

Posterior Tibial

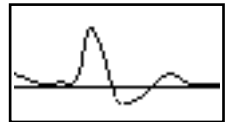
Dorsalis Pedis

Toe Pressure

Post Exercise

Left

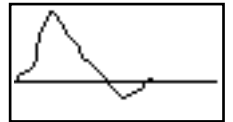
Good



Good

95

1.06



Notes

RIGHT LOWER LIMB ARTERIAL DUPLEX ASSESSMENT

Difficult assessment due to patient habitus and depth of vessels and calcified vessels.

Where visualised, the abdominal aorta appears patent, with good bi/triphasic waveforms, PSV 121cm/s.

Maximum AP diameter of 1.3cm, with no evidence of aneurysm noted.

Common iliac artery was poorly visualised, where seen good bi/triphasic waveforms, PSV 101cm/s.

External iliac artery appears mild/moderately diseased, good biphasic waveforms, PSV 127cm/s.

Common femoral artery appears mild/moderately diseased, good triphasic waveforms, PSV 111cm/s.

Assessed by Lukasz Koprowski

Printed on 08/06/2019 at 11:39 am

Checked by



Patient

NHS No

D.O.B.

Patient Ref

Profunda femoral artery (origin) appears mild/moderately diseased, good triphasic waveforms, PSV 143cm/s.

Superficial femoral artery (SFA) origin appears moderately diseased, good triphasic waveforms, PSV 122cm/s.

SFA appears occluded in the proximal thigh (63cm proximal to medial malleolus (MM), reforming in the distal thigh (44cm proximal to MM, with reduced monophasic flow, PSV 33cm/s into a mildly diseased SFA.

Popliteal artery appears mildly diseased, reduced monophasic waveforms, PSV 32cm/s. TPT appears patent; origin of 1 vessel run-off noted.

Posterior tibial artery appears patent along length, with mild calcified disease, reduced monophasic waveforms and PSV 38cm/s at ankle.

Anterior tibial artery appears patent along length, with mild calcified disease, reduced monophasic waveforms and PSV 26cm/s at ankle.

LEFT

Common femoral artery appears mild/moderately diseased, good triphasic waveforms, PSV 174cm/s.

Bilateral, resting ABPIs are within normal limits, becoming reduced post exercise on the right.

