



Reference

Accession

Patient

NHS No

D.O.B.

Patient Ref

Reason

Ulceration

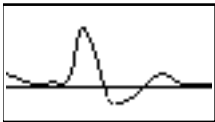
Outcome

disease severe, Calcified, Bowel gas, Poor images, patient habitus, Oedema

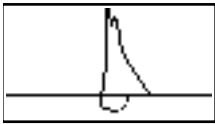Right

150

1.00




Good



turbulent



Absent



see notes

100

0.67

Brachial

Common Femoral

High Thigh

Low Thigh

Popliteal

High Calf

Peroneal

Anterior Tibial

Posterior Tibial

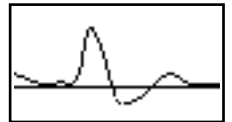
Dorsalis Pedis

Toe Pressure

Post Exercise

Left

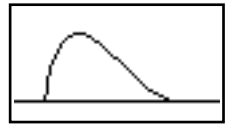
Good



see notes

120

0.80



Foot Flex

80

0.53

Foot Flex

120

0.80

Notes

RIGHT LOWER LIMB ARTERIAL DUPLEX SCAN

Difficult assessment due to patient's body habitus, bowel gas and calcified vessels.

Aorta and right common iliac artery are obscured.

EIA: appears patent, good triphasic waveforms, PSV 151cm/s.

CFA: mild-moderate disease, good triphasic waveforms, PSV 125cm/s.

PFA: patent, good triphasic waveforms, PSV 112cm/s.

SFA: diffuse mild-moderate disease, triphasic waveforms, PSV 83-138cm/s.

Assessed by

Lukasz Koprowski

Printed on 08/06/2019 at 11:23 am

Checked by



Patient

NHS No

D.O.B.

Patient Ref

POPA: patent proximally, slightly reduced monophasic waveforms, PSV 72cm/s. Severe disease noted at mid vessel, with velocities increasing to 451cm/s, turbulent monophasic flow. Very poor images obtained in the distal popliteal / TPT region ?patency.

All crural vessels appear calcified, with calf oedema and intermittent flow noted throughout ?full crural vessel patency.

ATA: no colour flow noted ?occluded.

PTA: some reduced monophasic flow seen at the ankle, PSV 38cm/s.

PerA: not identified.

LEFT CFA: appears patent, good triphasic waveforms, PSV 112cm/s.

Right, resting ABPI is reduced. Left, resting and post exercise ABPIs appear normal, but ?findings due to vessel calcification.

