



Reference

Accession

Patient

NHS No

D.O.B.

Patient Ref

Reason

Claudication

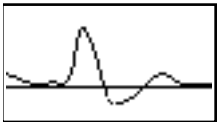
Outcome

Stenosis Severe

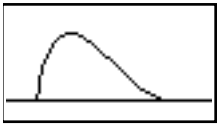
Right

160

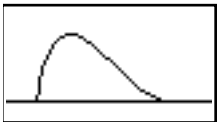
1.00



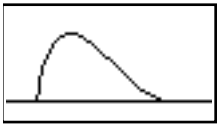
Good



Reduced



Reduced



Reduced

120

0.75

Brachial

Common Femoral

High Thigh

Low Thigh

Popliteal

High Calf

Peroneal

Anterior Tibial

Posterior Tibial

Dorsalis Pedis

Toe Pressure

Post Exercise


Foot Flex

70

0.44

Left

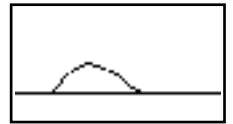
turbulent



Weak

80

0.50



Notes

RIGHT LOWER LIMB ARTERIAL DUPLEX ASSESSMENT

Abdominal aorta is patent, with good triphasic waveforms and PSV 50cm/s. The abdominal aorta appears of normal calibre (maximum AP = 1.8cm), with no evidence of focal dilatation or aneurysm identified.

CIA: appears patent, good triphasic waveforms, PSV 102cm/s.

EIA: appears patent, good triphasic waveforms, PSV 213cm/s.

Assessed by

Lukasz Koprowski

Printed on 08/06/2019 at 11:32 am

Checked by



Reference

Accession

Patient

NHS No

D.O.B.

Patient Ref

CFA: appears mild-moderately diseased, slightly turbulent triphasic waveforms, PSV 184cm/s.

CFA bifurcation appears moderately diseased, with the moderate disease extending into the profunda origin, slightly turbulent triphasic waveforms, PSV 170cm/s.

SFA: proximal vessel appears mild-moderately diseased, with good mono / just triphasic waveforms, PSV 145cm/s. Moderate stenosis noted in the prox-mid thigh (~60cm prox to MM), with the anechoic (?soft) plaque extending for ~1.3cm. Velocities increase from 77cm/s (mono / triphasic) to 156cm/s (turbulent monophasic), decreasing distally to 128cm/s (mono / just triphasic). Severe stenosis noted at mid-distal vessel (~51cm prox to MM), with the mixed echogenic plaque extending for ~1.9cm. Velocities increase from 70cm/s (reduced monophasic) to 566cm/s (turbulent monophasic), decreasing distally to 72cm/s (reduced monophasic). Distal vessel was difficult to visualise due to sub-optimal image resolution, but where seen appears patent, with reduced monophasic waveforms, PSV 52cm/s.

Pop A: appears widely patent, reduced monophasic waveforms, PSV 59cm/s. TPT appears patent; origins of 2 vessel run-off noted.

PTA: appears patent along its length, reduced monophasic waveforms, PSV 75cm/s.

Pero A: not identified.

ATA: appears patent along its length, reduced monophasic waveforms, PSV 48cm/s.

LEFT CFA: appears moderately diseased, turbulent triphasic waveforms, PSV 158cm/s.

Right, resting ABPI is reduced, becoming severely reduced post-exercise.

Left, resting ABPI is severely reduced.

