



Reference

Accession

Patient

NHS No

D.O.B.

Patient Ref

Reason

Claudication

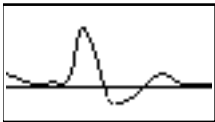
Outcome

disease moderate, Obscured, Calcified

Right

160

1.00



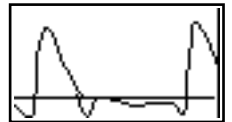
Good

Brachial

Left

Common Femoral

Good

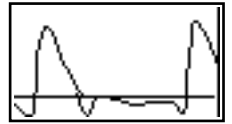


High Thigh

Low Thigh

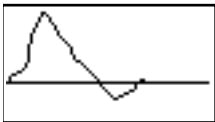
Popliteal

Good



High Calf

Peroneal



Good

180

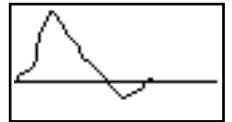
1.13

Anterior Tibial

Good

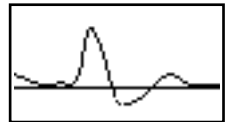
160

1.00



Posterior Tibial

See notes



Dorsalis Pedis

Toe Pressure

Post Exercise

Foot Flex

140

0.88

Notes

LEFT LOWER LIMB ARTERIAL DUPLEX ASSESSMENT

Slightly irregular heart rate noted.

Abdominal Aorta is patent with good triphasic waveforms PSV 64cm/s and is of normal and uniform calibre measuring 2.0cm (TS).

CIA - obscured by bowel gas.

EIA - appears patent, good biphasic waveforms, PSV 160cm/s.

Assessed by

Lukasz Koprowski

Printed on 08/06/2019 at 11:31 am

Checked by



Patient

NHS No

D.O.B.

Patient Ref

CFA - mild-moderately diseased, slightly turbulent bi/triphasic waveforms, PSV 160cm/s.

PFA origin - mildly diseased, good biphasic waveforms PSV 143cm/s.

SFA - patent throughout the thigh with good biphasic waveforms PSV 112 - 82cm/s. Mild diffuse dense and calcified disease noted.

PopA - mildly diseased and good bi/triphasic waveforms PSV 86cm/s. 2 vessel run-off noted.

ATA - patent but calcified to ankle with intermittent flow ?full patency, good biphasic waveforms PSV 34cm/s.

PTA - patent but calcified to mid-distal calf, good triphasic waveforms, PSV 43cm/s. No colour-flow detected in the distal calf ?occluded.

PeA was not identified.

Bilateral, resting ABPIs are within normal limits, with no decrease in pressure following a 1 minute foot-flex exercise challenge.

