



Reference

Accession

Patient

NHS No

D.O.B.

Patient Ref

Reason

Routine

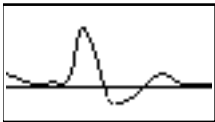
Outcome

disease mild, Calcified, No significant disease indicated

Right

160

1.00



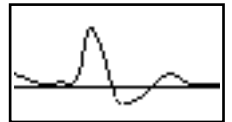
Good

Brachial

Common Femoral

Good

Left

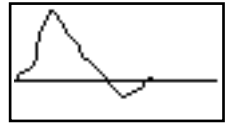


High Thigh

Low Thigh

Popliteal

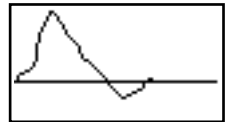
Good



High Calf

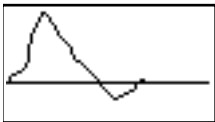
Peroneal

Good



Anterior Tibial

Good



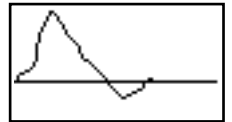
Good

220

1.38

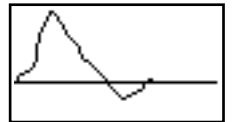
190

1.19



Posterior Tibial

Good



Dorsalis Pedis

Toe Pressure

Post Exercise

Foot Flex

190

1.19

Notes

LEFT LOWER LIMB ARTERIAL DUPLEX SCAN

AORTA: widely patent, good biphasic flow, PSV 81cm/s. Aorta is of a normal calibre, TS 1.5cm.

CIA: widely patent where visualised, good biphasic flow, PSV 48cm/s.

EIA: widely patent, good biphasic flow, PSV 127cm/s.

CFA: appears mildly diseased, good triphasic flow, PSV 130cm/s.

PFA: appears widely patent, good biphasic flow, PSV 100cm/s.

SFA: widely patent throughout its length, good biphasic flow, PSV 73-92cm/s.

Assessed by

Lukasz Koprowski

Printed on 08/06/2019 at 11:30 am

Checked by



Reference

Accession

Patient

NHS No

D.O.B.

Patient Ref

POPA: widely patent, good biphasic flow, PSV 82cm/s.

TPT: widely patent, with 3 vessel run-off noted.

ATA: severely calcified, but widely patent, good biphasic waveforms and PSV 62cm/s at the ankle.

PTA: severely calcified, but widely patent, good biphasic waveforms and PSV 65cm/s at the ankle.

PerA: patent where seen at the ankle, good biphasic waveforms and PSV 42cm/s.

Right CFA: widely patent, good triphasic flow, PSV 153cm/s.

ABPI: Left, resting and post-exercise readings appear normal. Unable to assess right ABPI due to incompressible crural vessels (BP >220mmHg).