



Reference

Accession

Patient

NHS No

D.O.B.

Patient Ref


Reason Embolic

Outcome Occlusion, Bowel gas, Poor images, patient habitus

## Right

## Left

Brachial



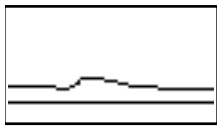Occluded

Common Femoral

High Thigh

Low Thigh

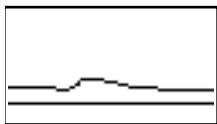Popliteal



Weak

High Calf

Peroneal



Weak

Anterior Tibial



Weak

Posterior Tibial

Dorsalis Pedis

Toe Pressure

Post Exercise

## Notes

RIGHT LOWER LIMB ARTERIAL DUPLEX (QUICK URGENT SCAN FROM CARDIOLOGY ?  
IATROGENIC CFA OCCLUSION)

AORTA: not assessed due to patient's condition.

RIGHT

CIA: not visualised due to bowel gas and depth.

EIA: appears patent where seen, biphasic waveforms, PSV 27cm/s.

Assessed by Lukasz Koprowski

Printed on 08/06/2019 at 11:22 am

Checked by



Reference

Accession

Patient

NHS No

D.O.B.

Patient Ref

CFA: difficult to visualise, but mid section appears occluded.

PFA: not assessed.

SFA: weak monophasic waveforms, PSV 13-23 cm/s.

POPA: weak monophasic waveforms, PSV 10 cm/s.

TPT: not assessed.

ATA: weak monophasic waveforms at the ankle, PSV 9 cm/s.

PTA: weak monophasic waveforms at the ankle, PSV 8 cm/s.

ABPIs not assessed.

SUGGEST URGENT REFERRAL TO VASCULAR TEAM