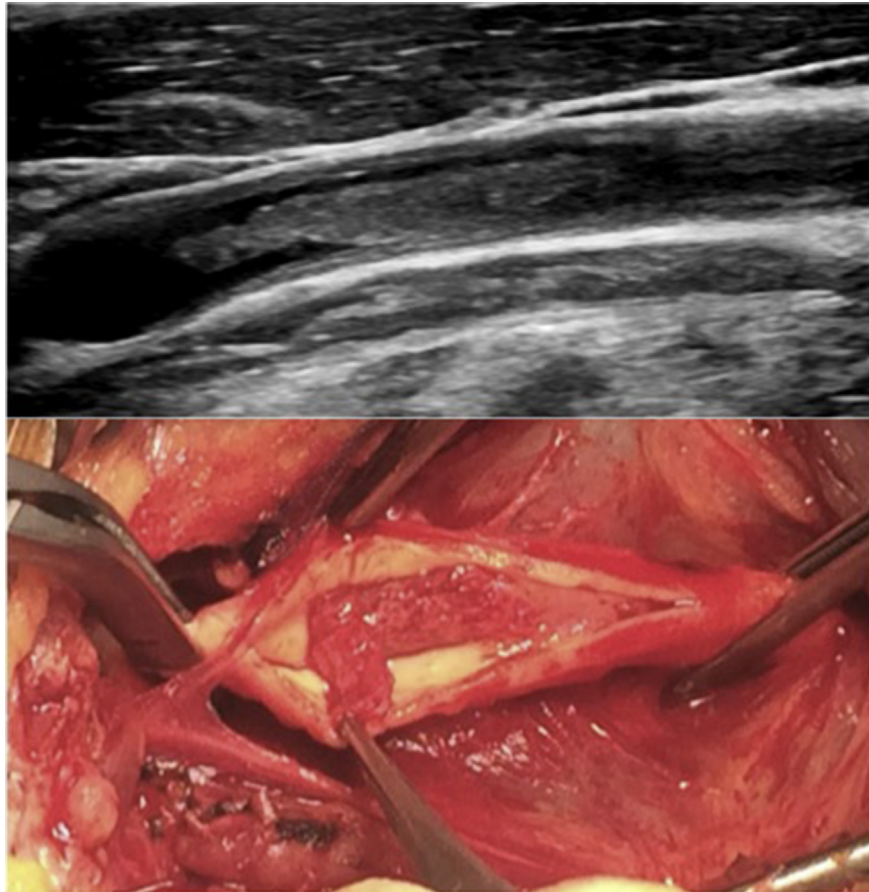


COUP D'OEIL**A Timely Intervention****M.B. Naylor, A.R. Naylor***

The Department of Vascular Surgery at Leicester Royal Infirmary, Leicester, UK



A 57-year-old male suffered two right carotid territory transient ischaemic attacks (TIAs) around 11:00 p.m. on a Friday evening. He was seen in the daily TIA clinic at 09:00 a.m. the following morning, where Duplex ultrasound revealed a mobile filling defect (top) within the mid common carotid artery (CCA). Emergency exploration that afternoon confirmed the presence of a large thrombus, which was partially adherent to an ulcerated plaque on the posterior CCA wall (bottom). Otherwise, there was no significant atherosclerotic stenosis. He made an uneventful recovery and remains asymptomatic 3 months postoperatively.

* Corresponding author. Vascular Research Group, Division of Cardiovascular Sciences, Clinical Sciences Building, Leicester Royal Infirmary, Leicester LE2 7LX, UK.

E-mail address: ross.naylor@uhl-tr.nhs.uk (A.R. Naylor).

Twitter: [@arossnaylor](https://twitter.com/arossnaylor)

1078-5884/© 2016 European Society for Vascular Surgery. Published by Elsevier Ltd. All rights reserved.

<http://dx.doi.org/10.1016/j.ejvs.2016.10.003>