

# Digital artery vasospasm in primary Raynaud's phenomenon

Steven Rogers<sup>1,2</sup> , Michael Hughes<sup>3</sup> 

A 60-year-old female with known primary Raynaud's phenomenon (RP) presented with an episodic unilateral attack of digital pallor change in the left index finger (Figure 1a) associated with paresthesia. Ultra-high-frequency (48 MHz) ultrasound of the affected digit revealed vasospasm of the proper digital arteries (Figure 1b), where color flow imaging shown in the longitudinal view was absent (Figure 1b). Contralaterally, the unaffected respective digit (Figure 1c) had normal color flow (Figure 1d). The attack lasted approximately 15 minutes and self-aborted.

Primary RP is a common vasospastic condition primarily affecting the digital artery. Typical attacks of the RP affect the extremities, presenting as episodic digital color changes in response to cold and/or emotional stress (1). Secondary RP can occur because of a broad range of medical and drug causes and is often the earliest manifestation seen in patients with systemic sclerosis (SSc) (1). Significant abnormalities (e.g., intimal hyperplasia and occlusion) of the digital arteries have been reported in SSc (2). Irrespective of the underlying cause, RP can have a significant impact on quality of life and function (3).

First-line treatment is patient education and behavioral adaptations (e.g., cold avoidance) (1, 4, 5). Pharmacological therapy (e.g., oral vasodilators) is indicated after the failure of general measures/behavioral adaptations. Calcium channel blockers are often used as the first-line drug treatment; however, clinicians are increasingly using phosphodiesterase type 5 inhibitors earlier for the pharmacological treatment of SSc-associated digital vasculopathy (1, 4, 5).

Patients with RP should seek emergency medical attention if they develop a permanently discolored digit and/or develop signs of tissue ulceration or gangrene.

**ORCID iDs of the authors:**  
S.R. 0000-0003-1722-453X;  
M.H. 0000-0003-3361-4909.

**Cite this article as:** Rogers S, Hughes M. Digital artery vasospasm in primary Raynaud's phenomenon. *Eur J Rheumatol* 8 June 2020; 10.5152/eurjrheum.2020.19211 [Epub Ahead of Print].

<sup>1</sup> Academic Surgery Unit, Division of Cardiovascular Sciences, School of Medical Sciences, Faculty of Biology, Medicine and Health, University of Manchester, Manchester Academic Health Science Centre, Wythenshawe Hospital, Manchester, UK

<sup>2</sup> Independent Vascular Services Ltd, Wythenshawe Hospital, Manchester University NHS Foundation Trust, Manchester, UK

<sup>3</sup> Department of Rheumatology, Royal Hallamshire Hospital, Sheffield Teaching Hospitals NHS Foundation Trust, Sheffield, UK

**Address for Correspondence:**  
Michael Hughes; Department of Rheumatology, Royal Hallamshire Hospital, Sheffield Teaching Hospitals NHS Foundation Trust, Sheffield, UK

E-mail: Michael.hughes-6@postgrad.manchester.ac.uk

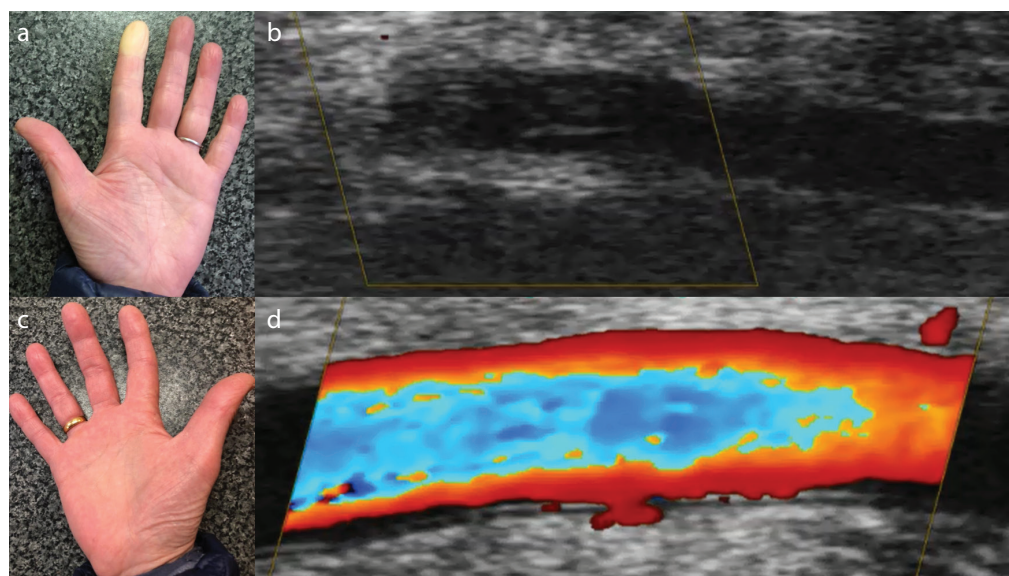
Submitted: December 14, 2019

Accepted: February 04, 2020

Available Online Date: June 08, 2020

Copyright©Author(s) - Available online at [www.eurjrheumatol.org](http://www.eurjrheumatol.org).

Content of this journal is licensed under a Creative Commons Attribution-NonCommercial 4.0 International License.



**Figure 1. a-d.** Unilateral attack (a) of primary Raynaud's phenomenon and digital artery vasospasm as assessed by ultra-high-frequency ultrasound (b). The contralateral digit was unaffected (c) and had normal color flow (d).

**Informed Consent:** Written informed consent was obtained from the patient who participated in this study.

**Peer-review:** Externally peer-reviewed.

**Author Contributions:** Concept - S.R., M.H.; Design - S.R., M.H.; Supervision - S.R., M.H.; Materials - S.R.; Data Collection and/or Processing - S.R.; Analysis and/or Interpretation - S.R., M.H.; Literature Search - S.R., M.H.; Writing Manuscript - S.R., M.H.; Critical Review - S.R., M.H.

**Conflict of Interest:** The authors have no conflict of interest to declare.

**Financial Disclosure:** The authors declared that this study has received no financial support.

## References

1. Pauling JD, Hughes M, Pope JE. Raynaud's phenomenon - an update on diagnosis, classification and management. *Clin Rheumatol* 2019; 38: 3317-30. [\[Crossref\]](#)
2. Allano Y, Seror R, Chevrot A, Kahan A, Drapé JL. Hand vascular involvement assessed by magnetic resonance angiography in systemic sclerosis. *Arthritis Rheum* 2007; 56: 2747-54. [\[Crossref\]](#)
3. Hughes M, Snapir A, Wilkinson J, Snapir D, Wigley FM, Herrick AL. Prediction and impact of attacks of Raynaud's phenomenon, as judged by patient perception. *Rheumatology (Oxford)* 2015; 54: 1443-47. [\[Crossref\]](#)
4. Hughes M, Ong VH, Anderson ME, Hall F, Moinzadeh P, Griffiths B, et al. Consensus best practice pathway of the UK Scleroderma Study Group: Digital vasculopathy in systemic sclerosis. *Rheumatology (Oxford)* 2015; 54: 2015-24. [\[Crossref\]](#)
5. Denton CP, Hughes M, Nataliya G, Vila J, Buch MH, Chakravarty K, et al. BSR and BHPR guideline for the treatment of systemic sclerosis. *Rheumatology (Oxford)* 2016; 55: 1906-10. [\[Crossref\]](#)